

# Larynx & Middle Ear

## 喉部與中耳

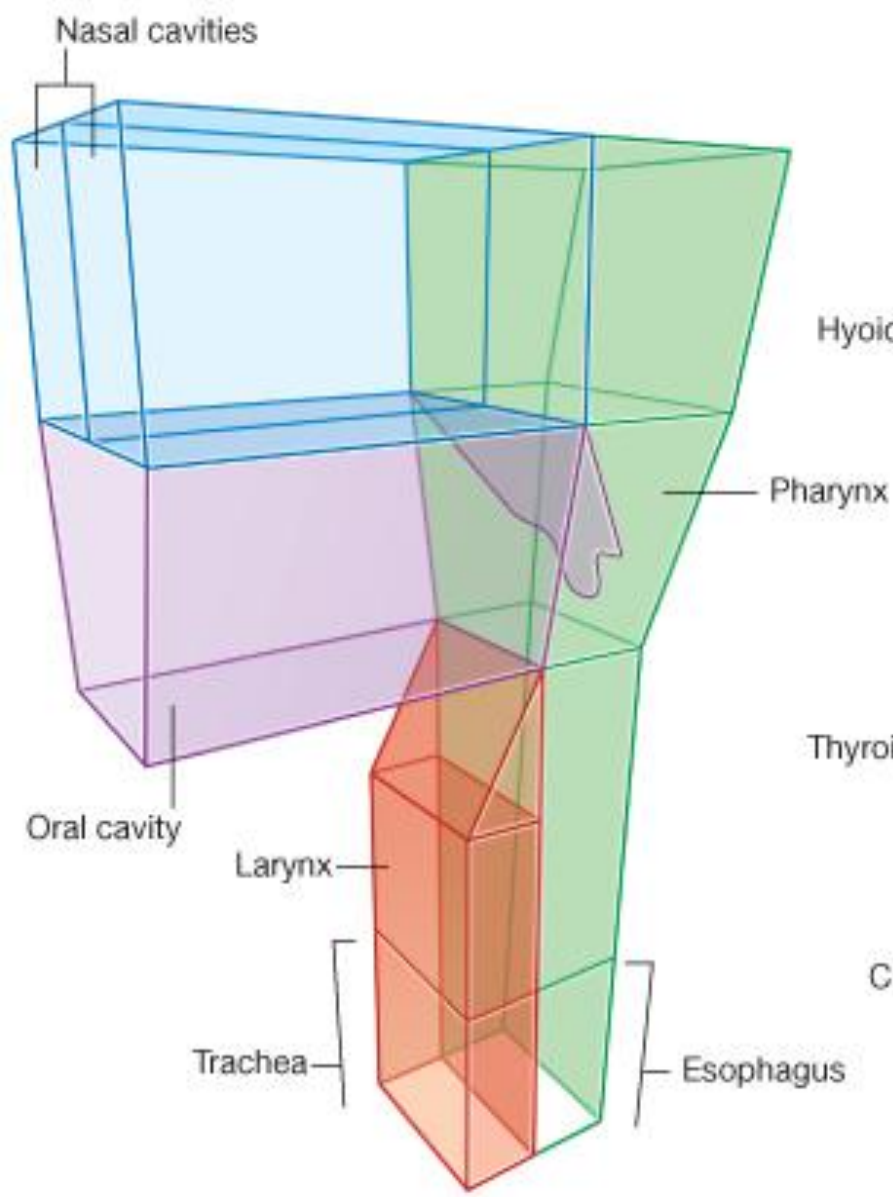
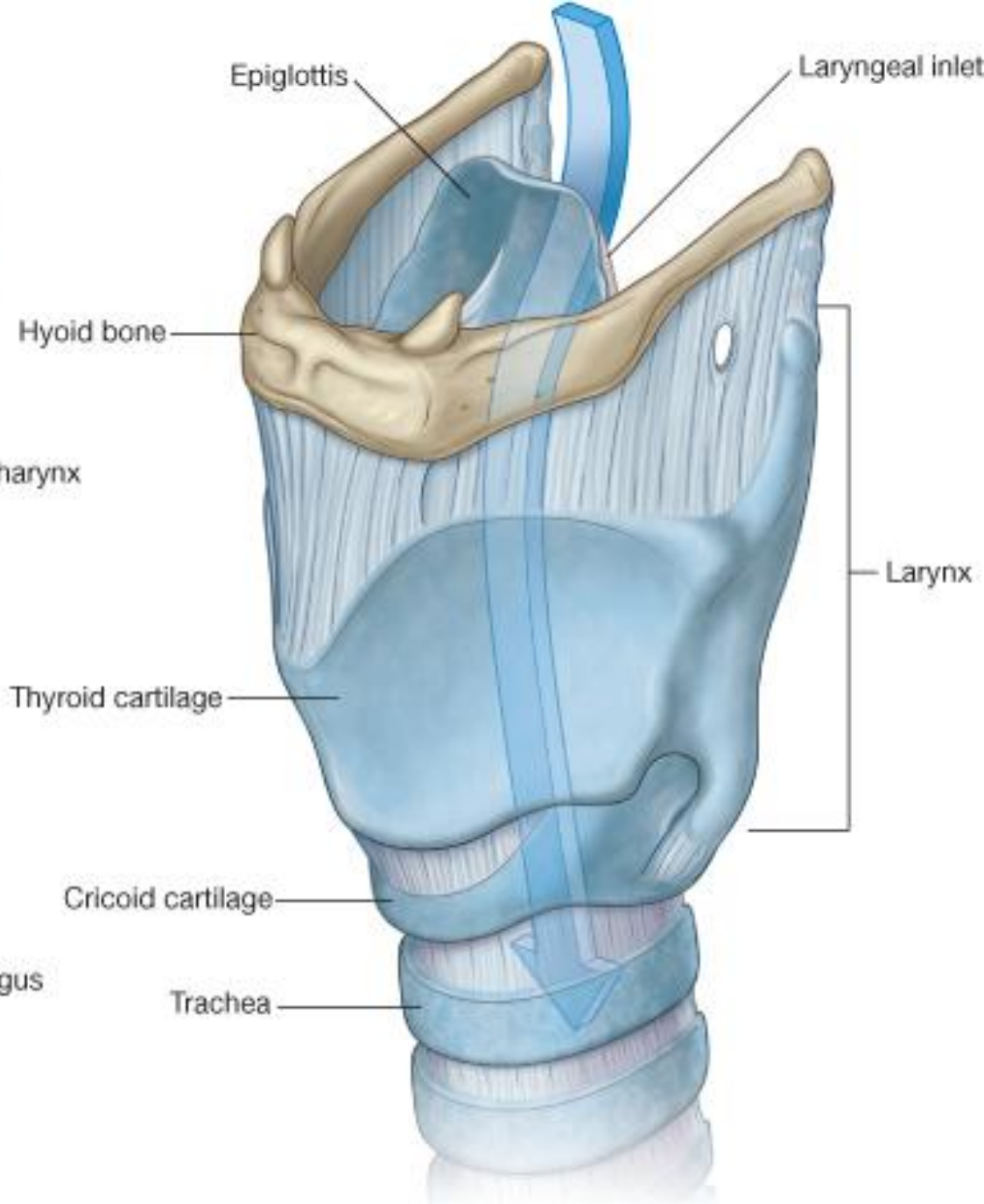
解剖學科 馮琮涵 副教授

分機 3250

E-mail: [thfong@tmu.edu.tw](mailto:thfong@tmu.edu.tw)

# Outline:

- Cartilages and ligaments of larynx
- Muscles, blood vessels and nerves of larynx

**A****B**

# Larynx

Position: C3-C6

Function: voice production (vocalization)

*Laryngeal skeleton: (9 cartilages)*

**Thyroid cartilage**

**Cricoid cartilage**

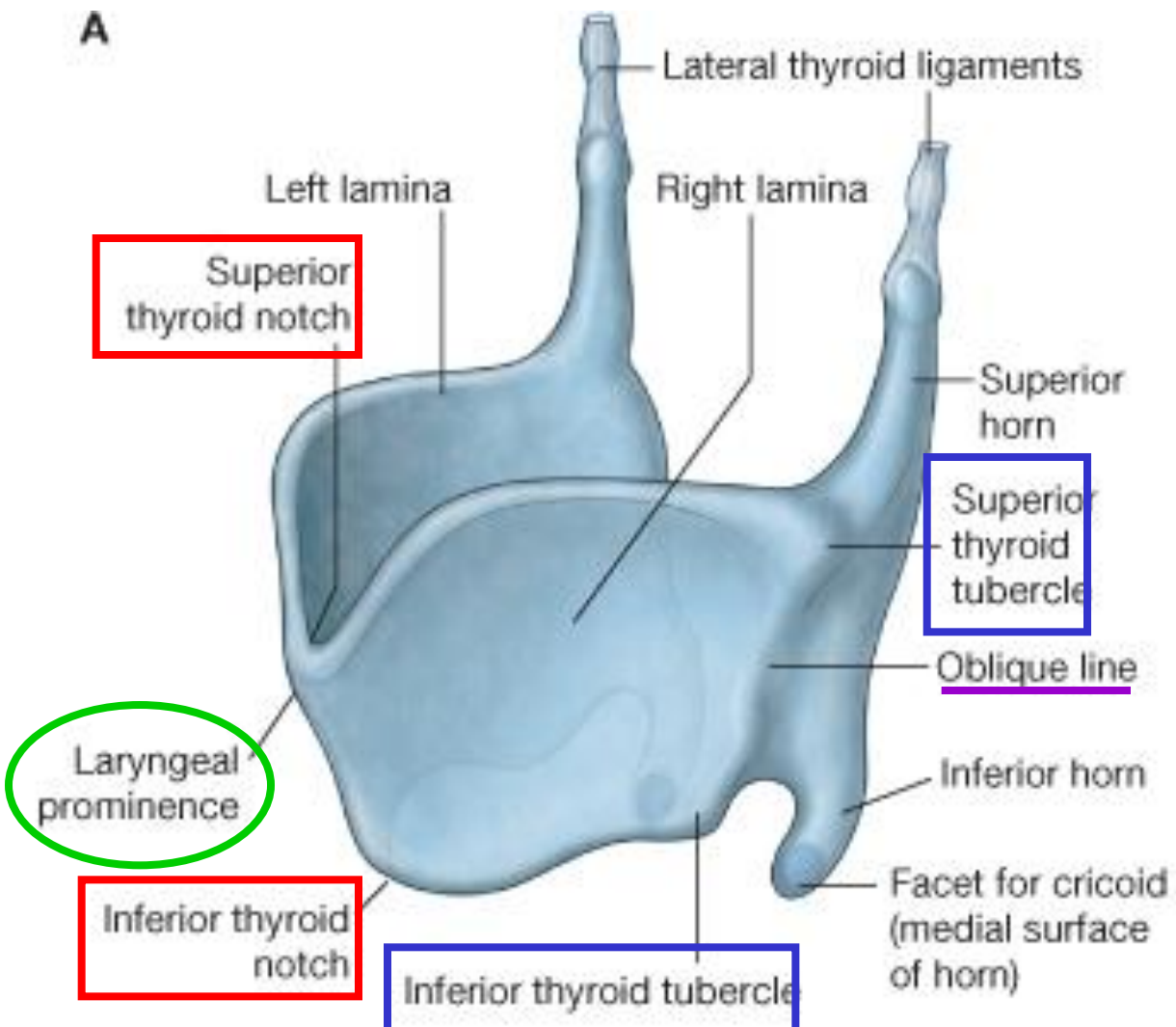
**Arytenoid cartilages**

**Epiglottic cartilage**

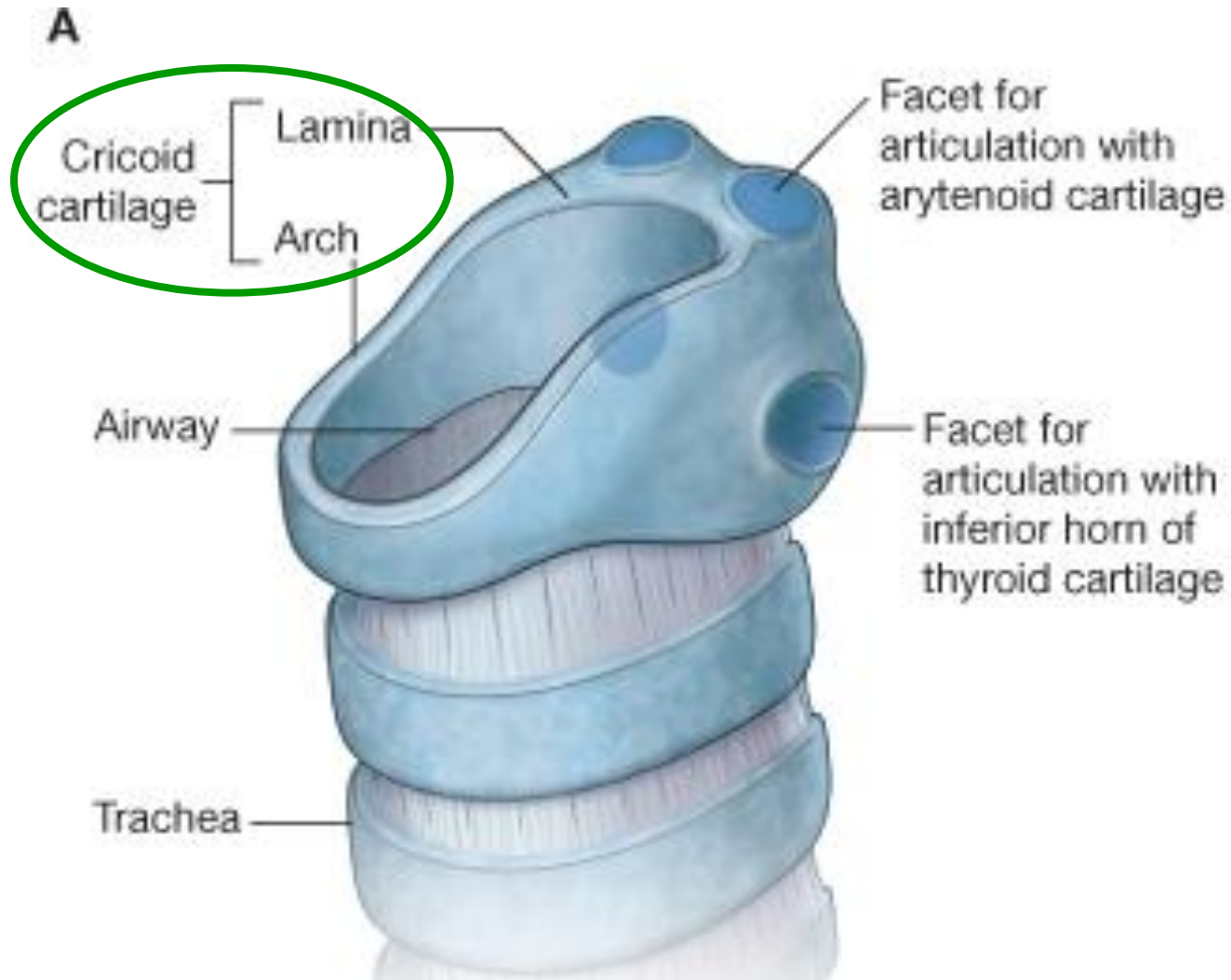
**Corniculate cartilages**

**Cuneiform cartilages**

**Thyroid cartilage** – laryngeal prominence (*Adam's apple*), sup. & inf. thyroid notch; horn; tubercles, *oblique line* **facet for cricoid cartilage**

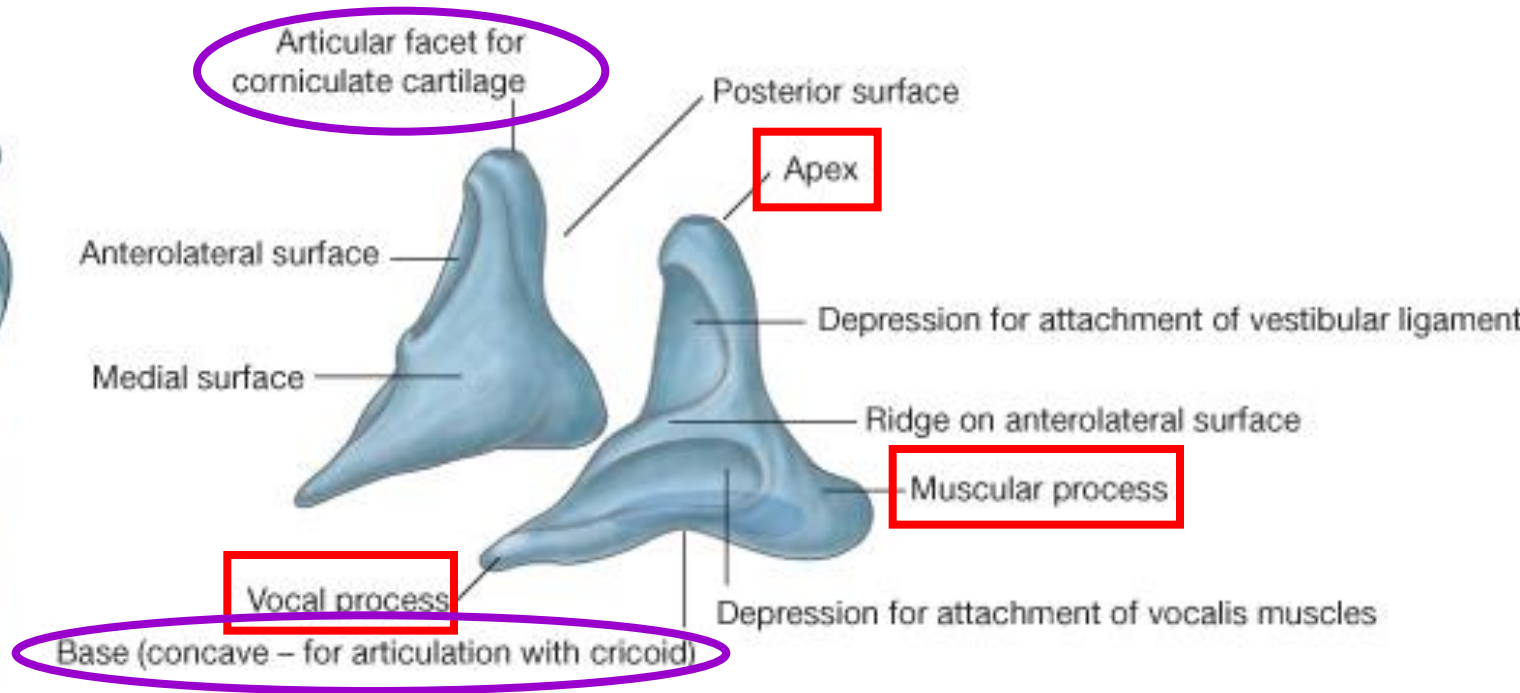
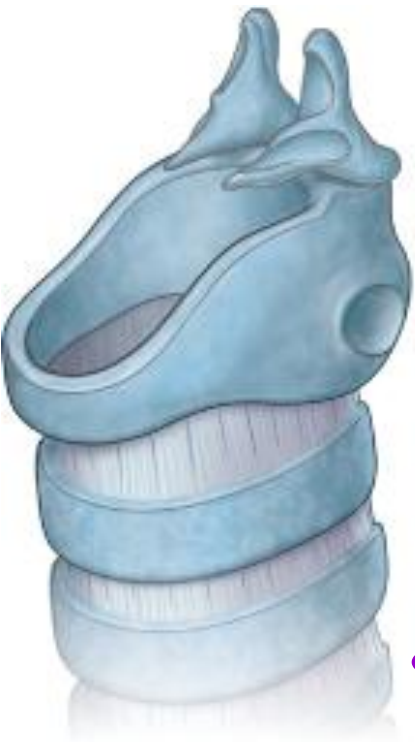

**Cricoid cartilage** – lamina and arch,  
facet for inferior horn of thyroid cartilage  
facet for arytenoid cartilage



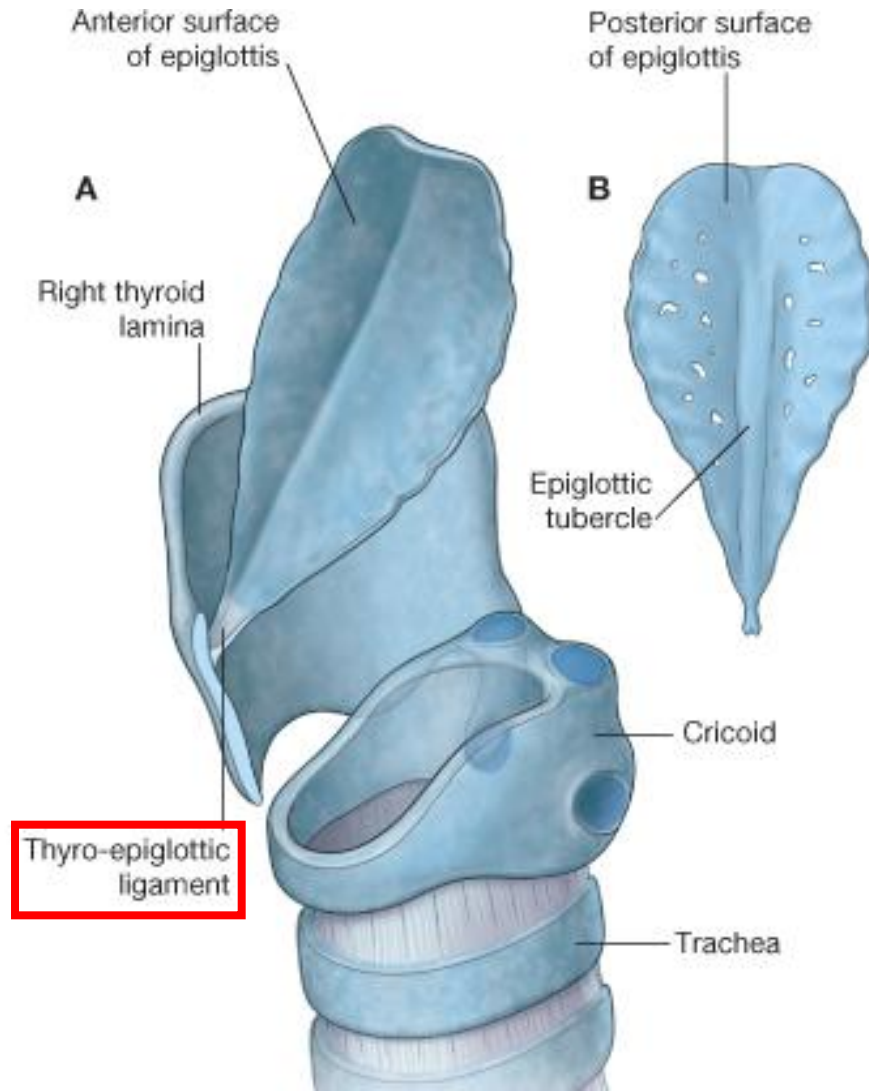
# Arytenoid cartilages – three-sided pyramids (apex, vocal process and muscular process)

## crico-arytenoid joints



# Epiglottic cartilage – “leaf-shaped”

– post. to tongue & hyoid bone, ant. to laryngeal inlet  
thyro-epiglottic lig.



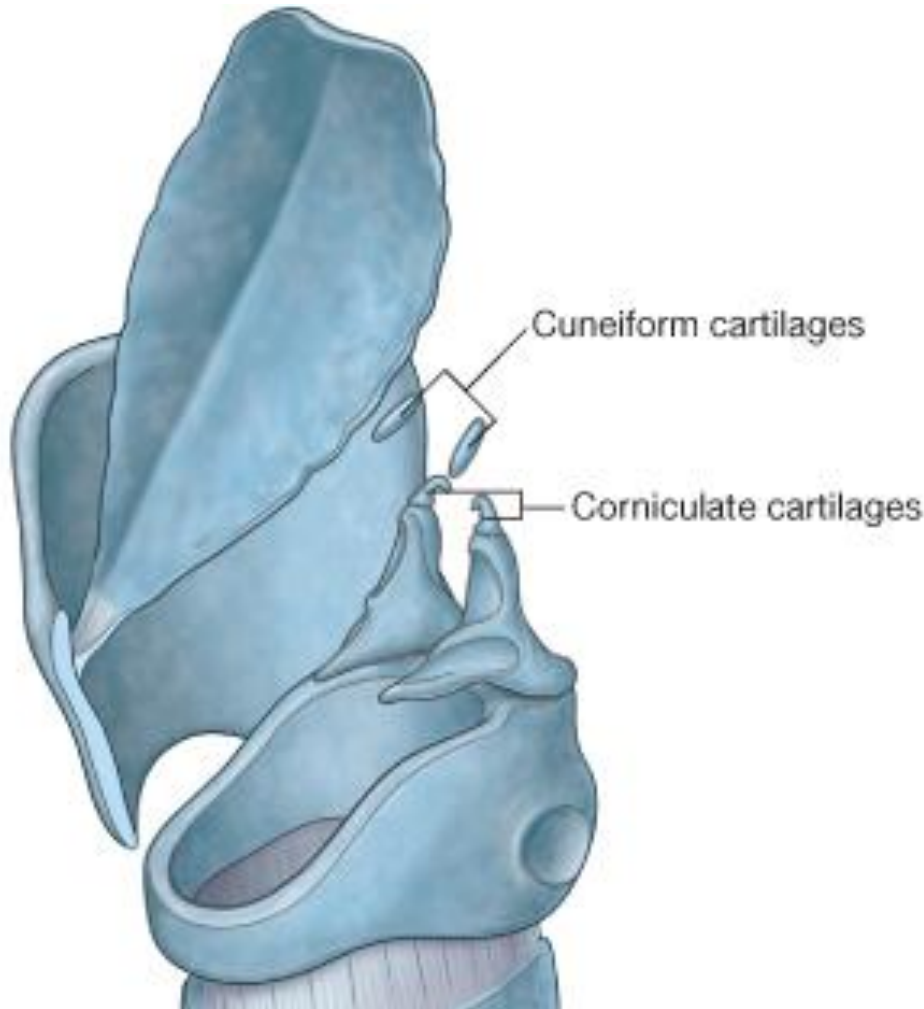


# Corniculate cartilages

– attach to the apex of arytenoid cartilage

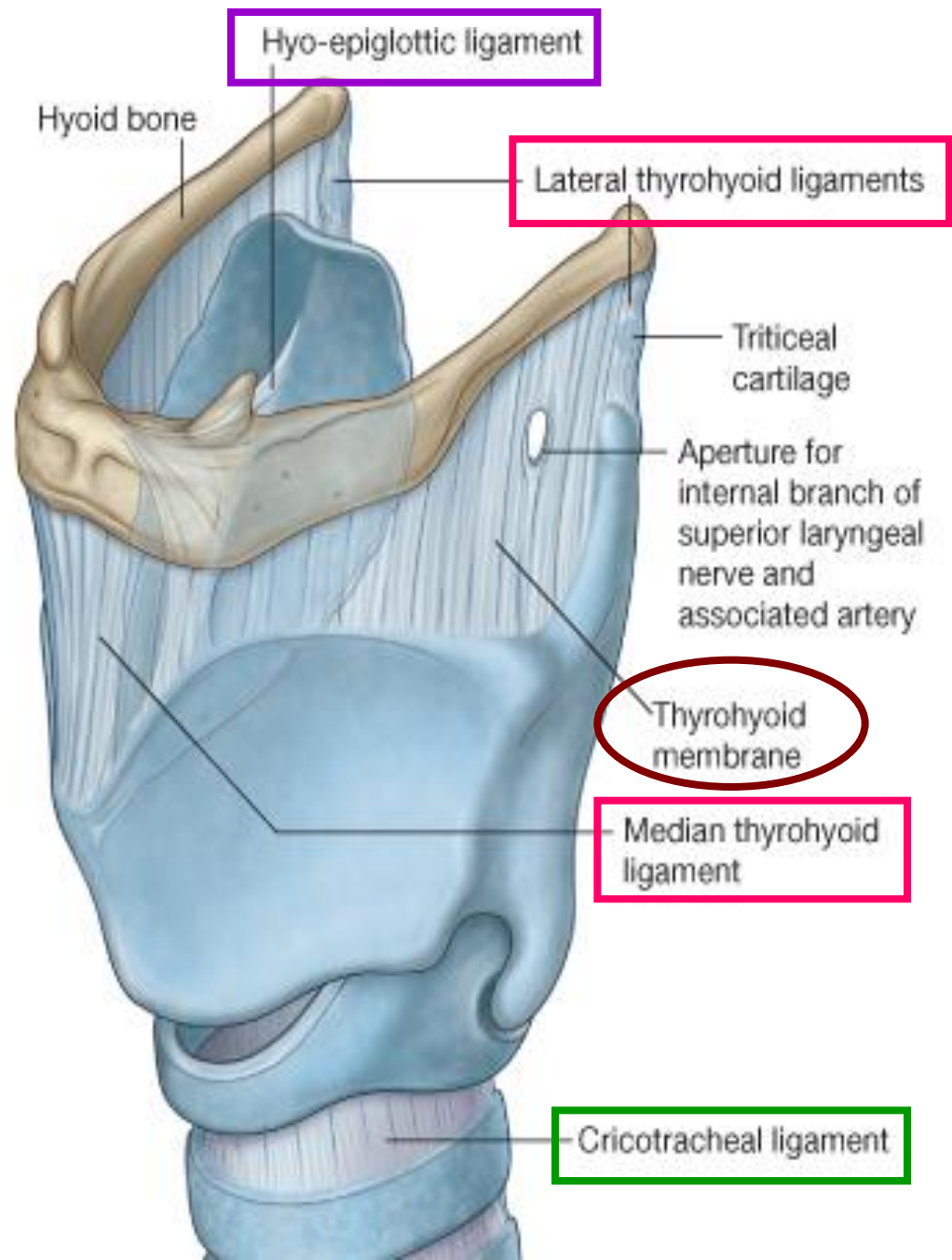
# Cuneiform cartilages

– do not directly attach to other cartilage



# Extrinsic ligaments of larynx

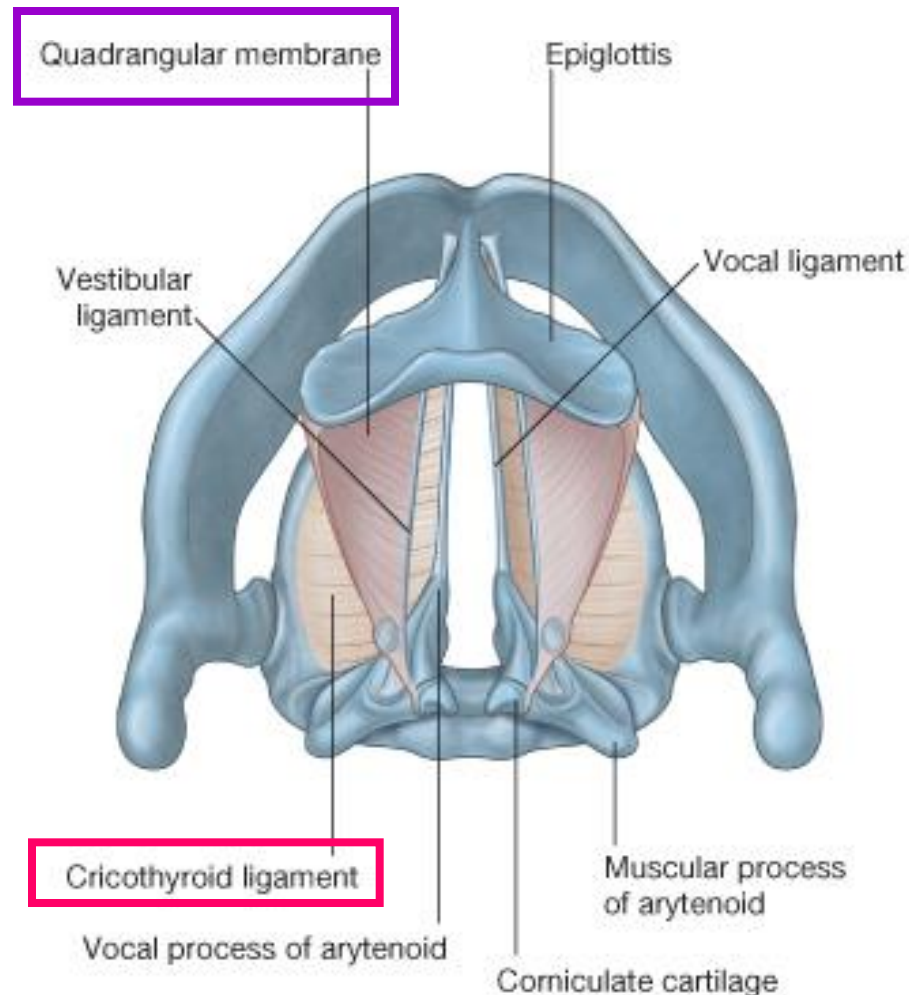
- **Thyro-hyoid membrane**  
median & lateral thyro-hyoid **ligaments**
- **Hyo-epiglottic ligament**
- **Crico-tracheal ligament**



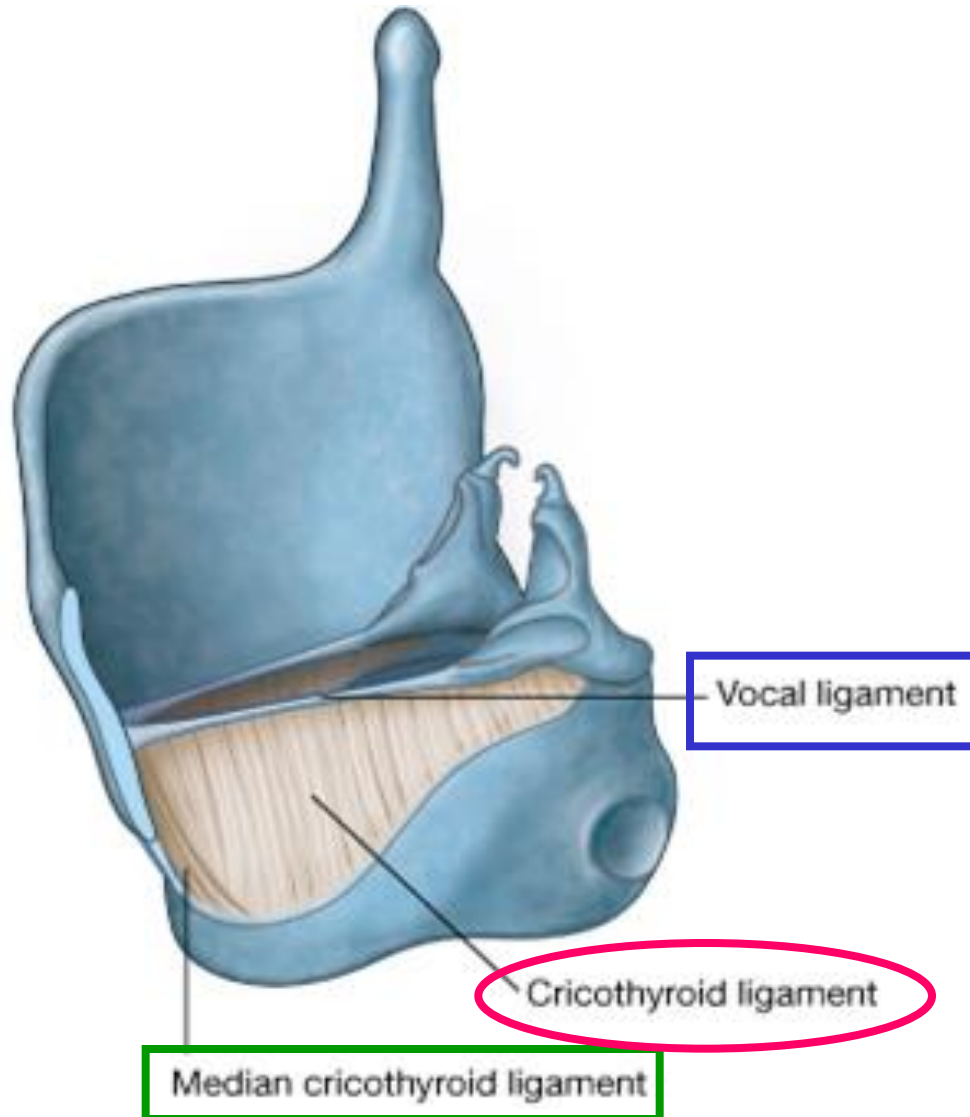
# Intrinsic ligaments of larynx (fibro-elastic membrane of larynx)

**Crico-thyroid ligament**

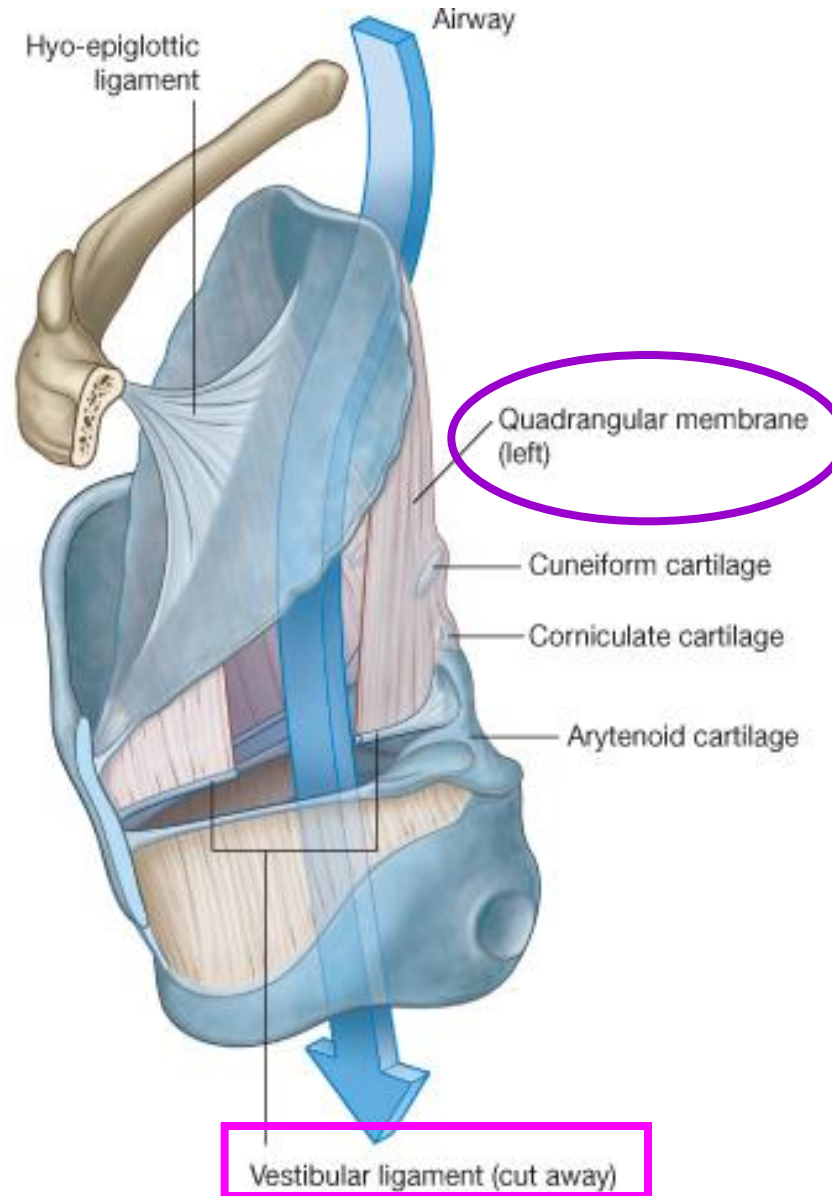
**Quadrangular membrane**



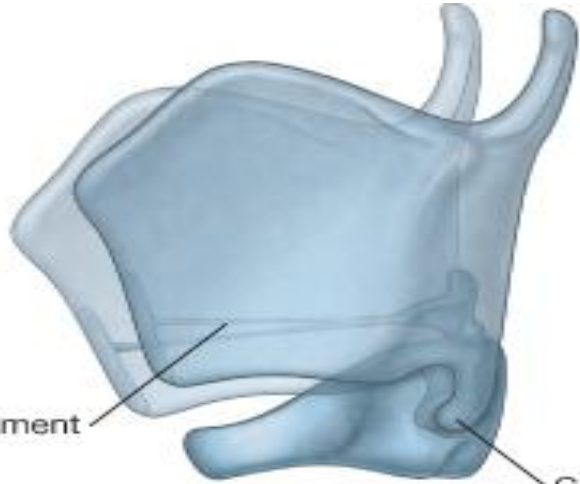
# Crico-thyroid membrane (ligament) (*crico-vocal membrane*)



# Quadrangular membrane



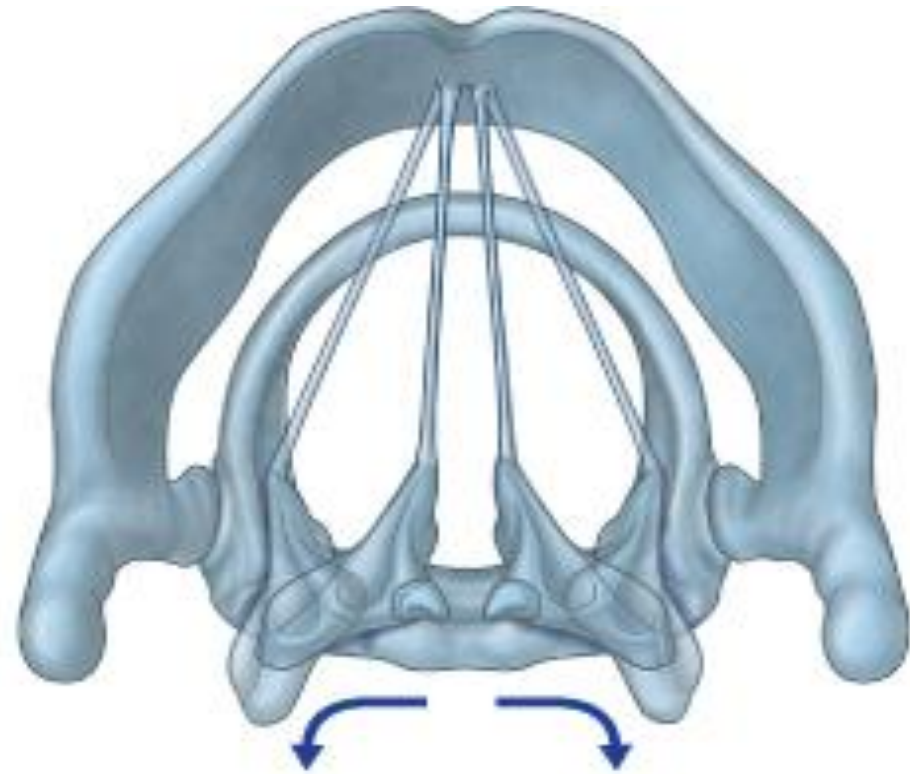
# Laryngeal joints



Vocal ligament

Cricothyroid joint

**crico-thyroid joint**



**crico-arytenoid joint**

# *Cavity of the larynx*

## **Vestibule**

- superior to the **vestibular fold** (false vocal fold)

## **Ventricle & saccule**

- between the **vestibular folds** and **vocal folds**

## **Infraglottic space**

- from vocal fold to the border of cricoid cartilage

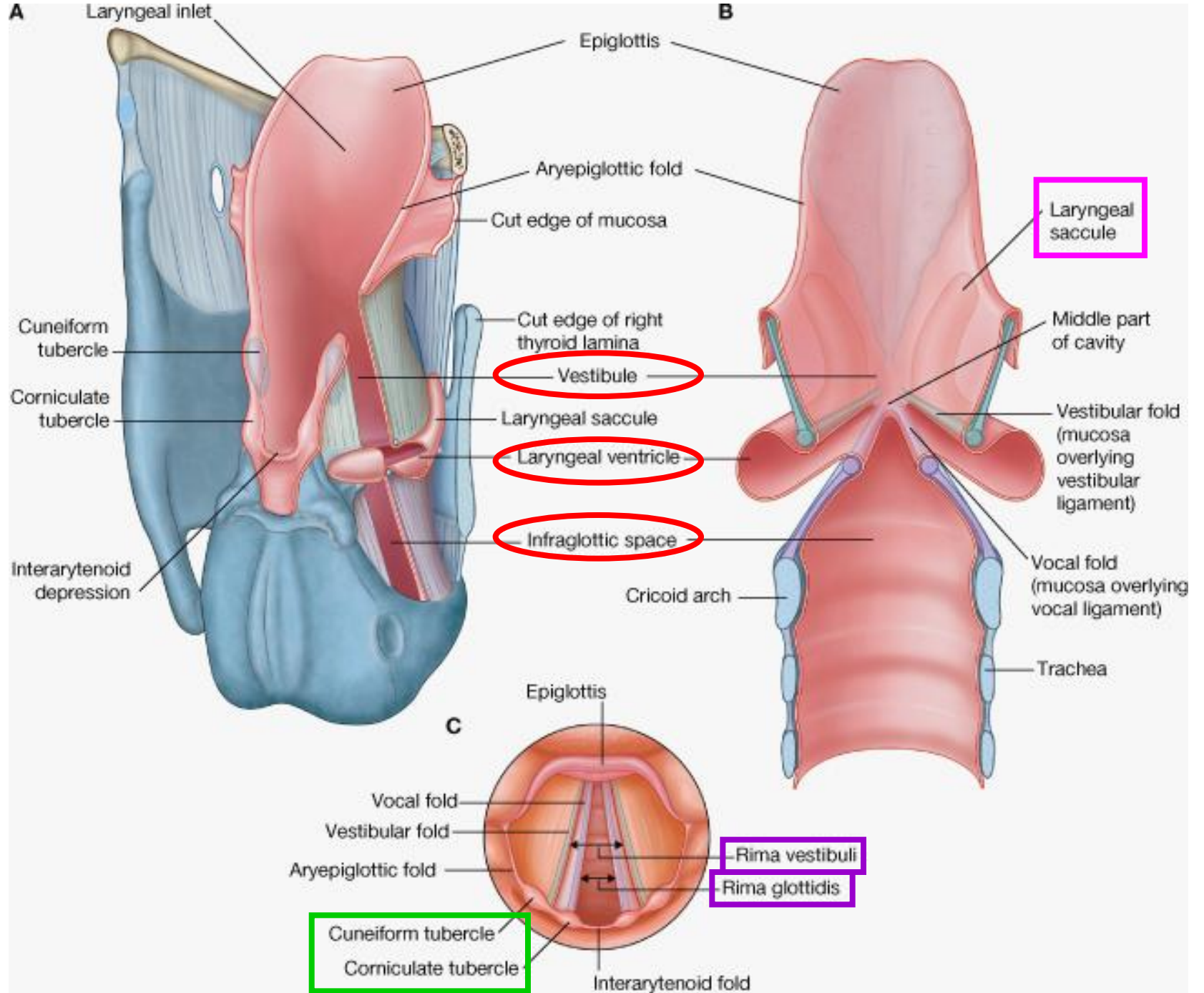
*Glottis* (the vocal apparatus of the larynx)

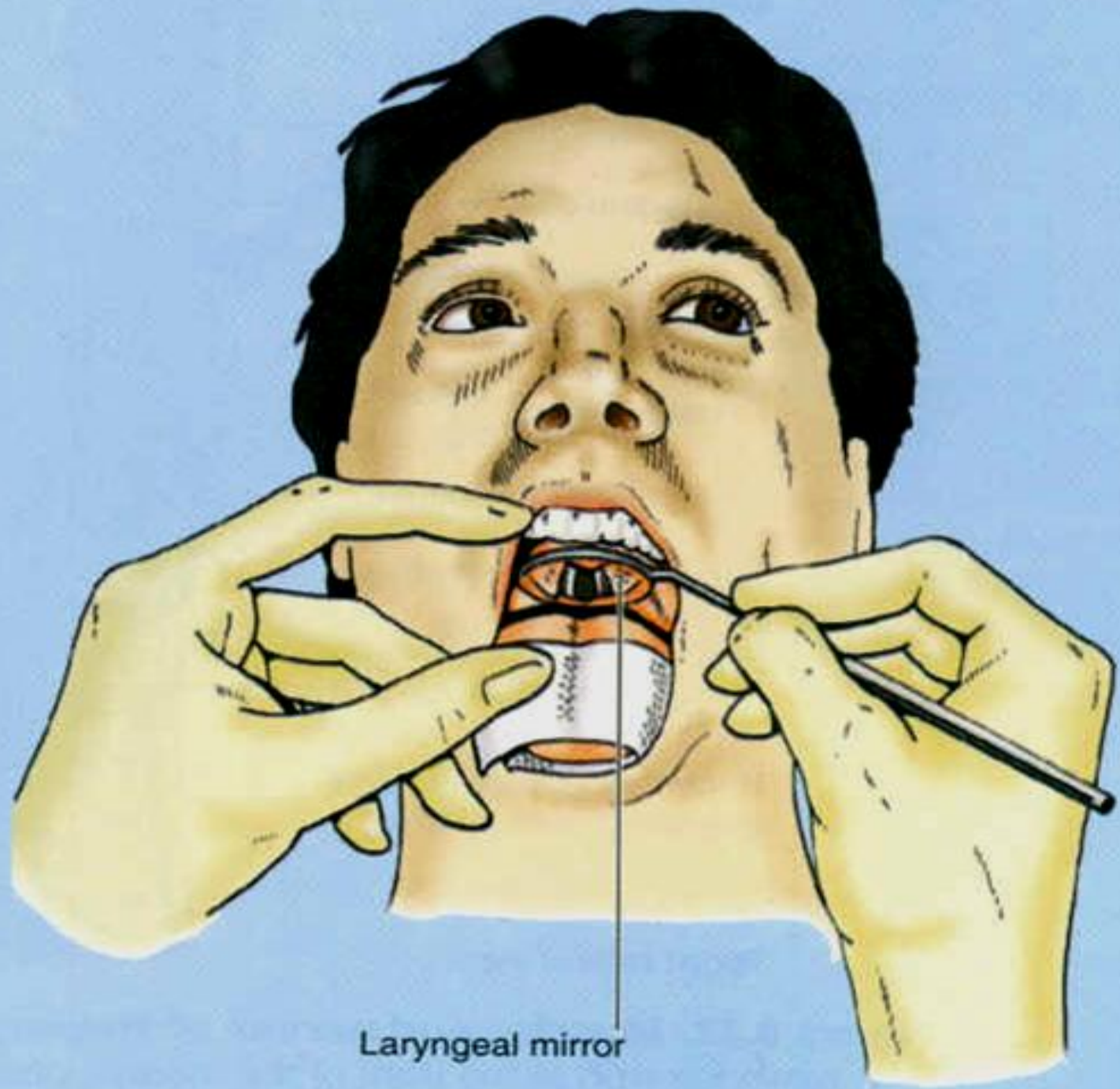
*Rima glottidis* – the aperture between the **vocal folds**

*Rima vestibuli* – the aperture between the **vestibular folds**

# Greater length of the vocal folds in man #



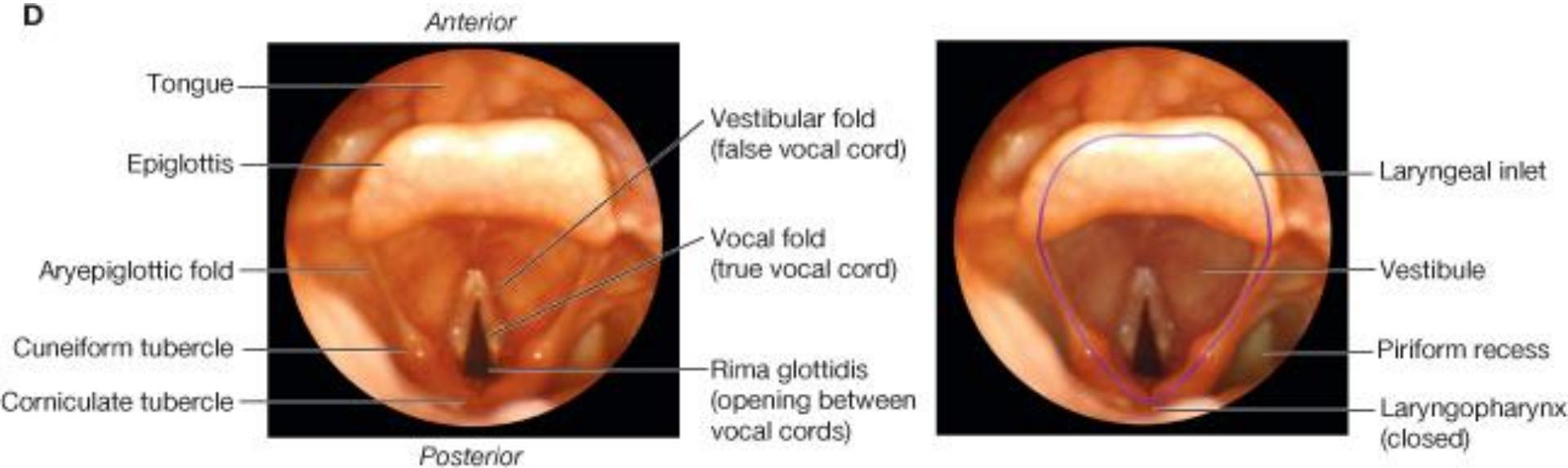




Laryngeal mirror

# Laryngeal cavity

D



© Elsevier Ltd. Drake et al: Gray's Anatomy for Students [www.studentconsult.com](http://www.studentconsult.com)

# Laryngeal muscles

**Extrinsic laryngeal muscles:** *move the larynx as a whole*  
**infra-hyoid m.** (depressor),  
**supra-hyoid** and **stylopharyngeus m.** (elevators)

**Intrinsic laryngeal muscles:** *regulation of the tension of vocal folds and the size of rima glottidis*

**cricothyroid m.** (ext. laryngeal n.)

**post. cricoarytenoid m.** (recurrent laryngeal n.)

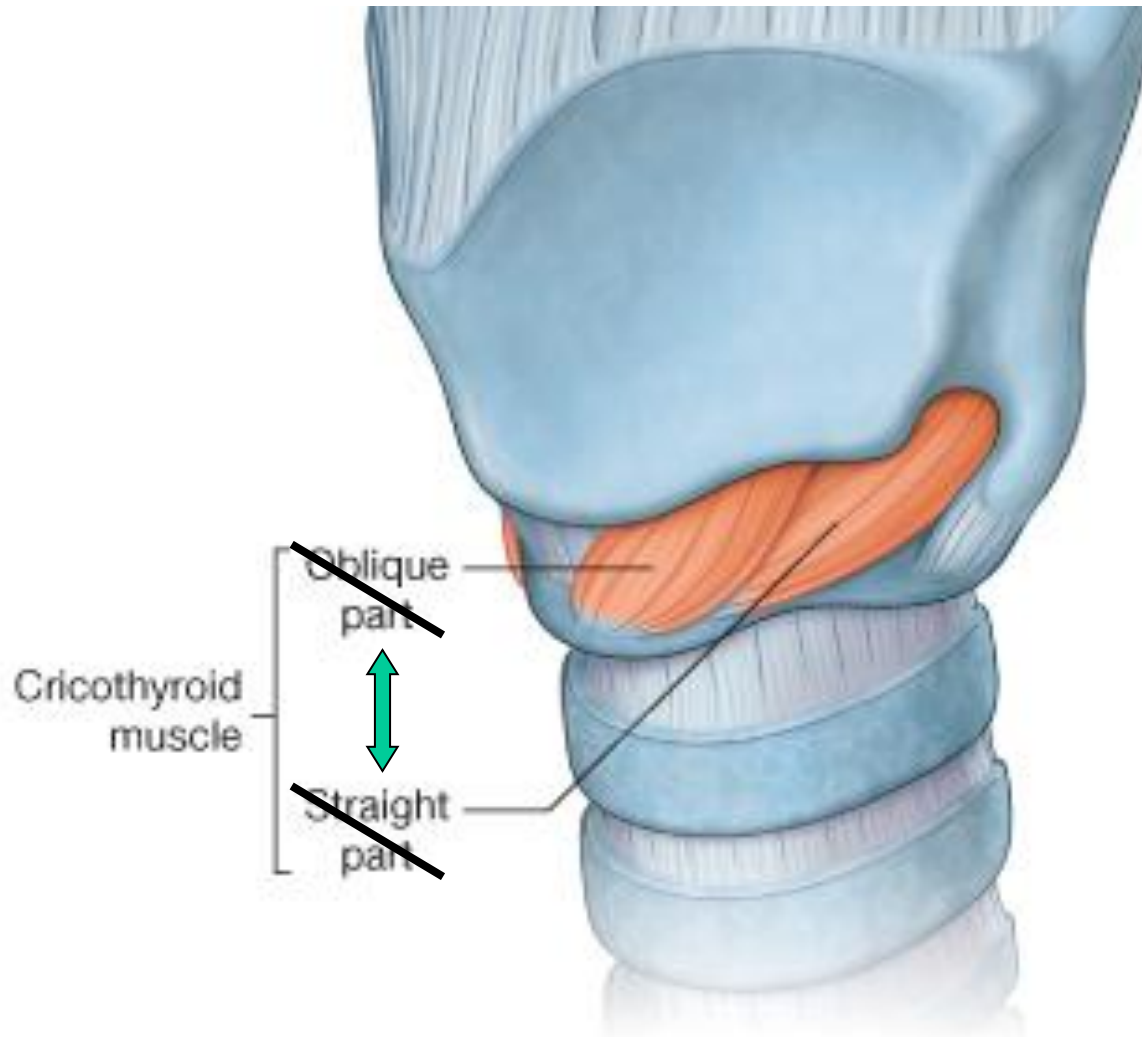
**lat. cricoarytenoid m.**

**transverse & oblique arytenoid m.**

**vocalis m.**

**thyroarytenoid m.**

**cricothyroid m.** (stretches and tenses vocal fold)  
– **external laryngeal nerve**



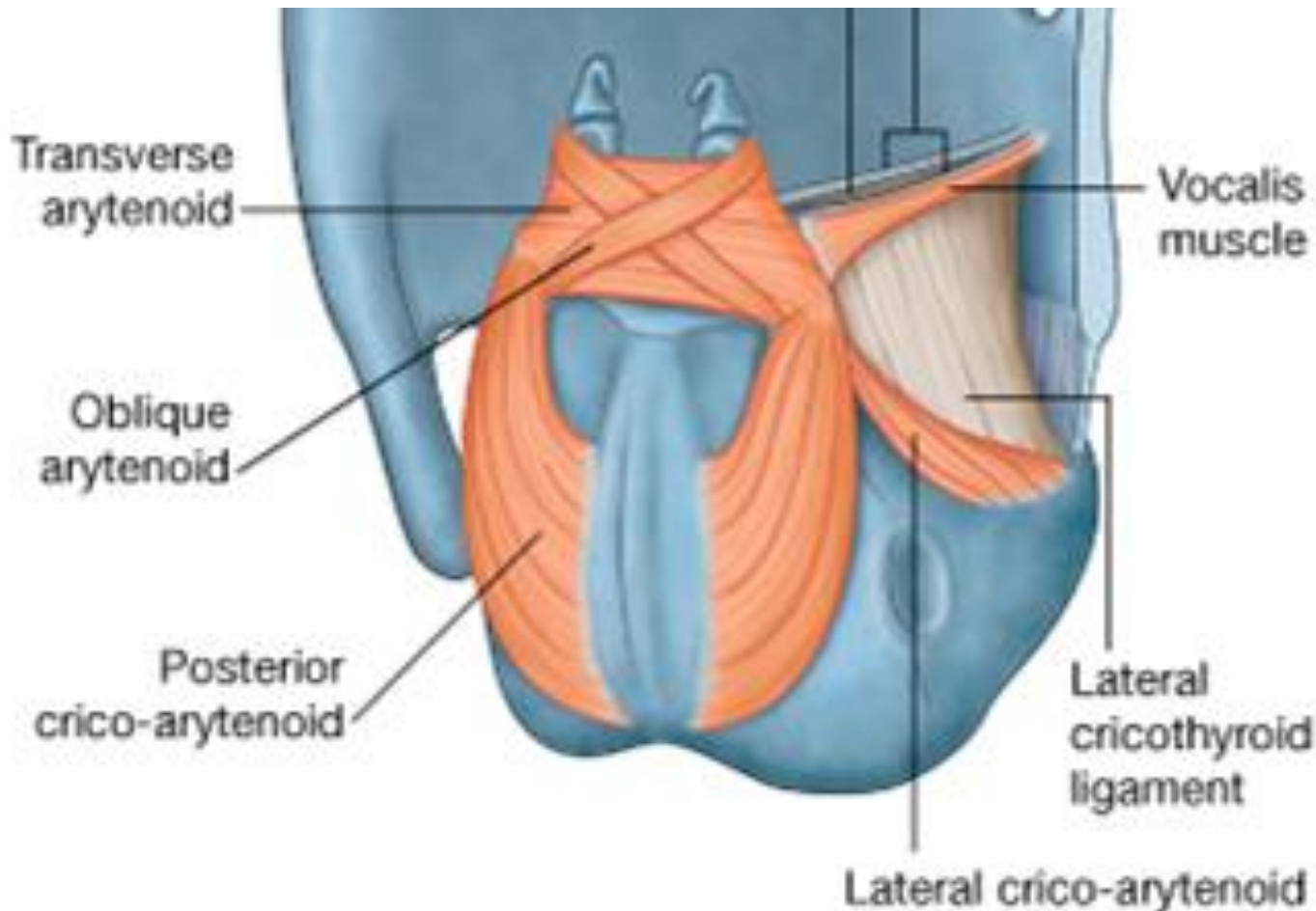
**posterior cricoarytenoid m.** (open)

**lateral cricoarytenoid m.** (close)

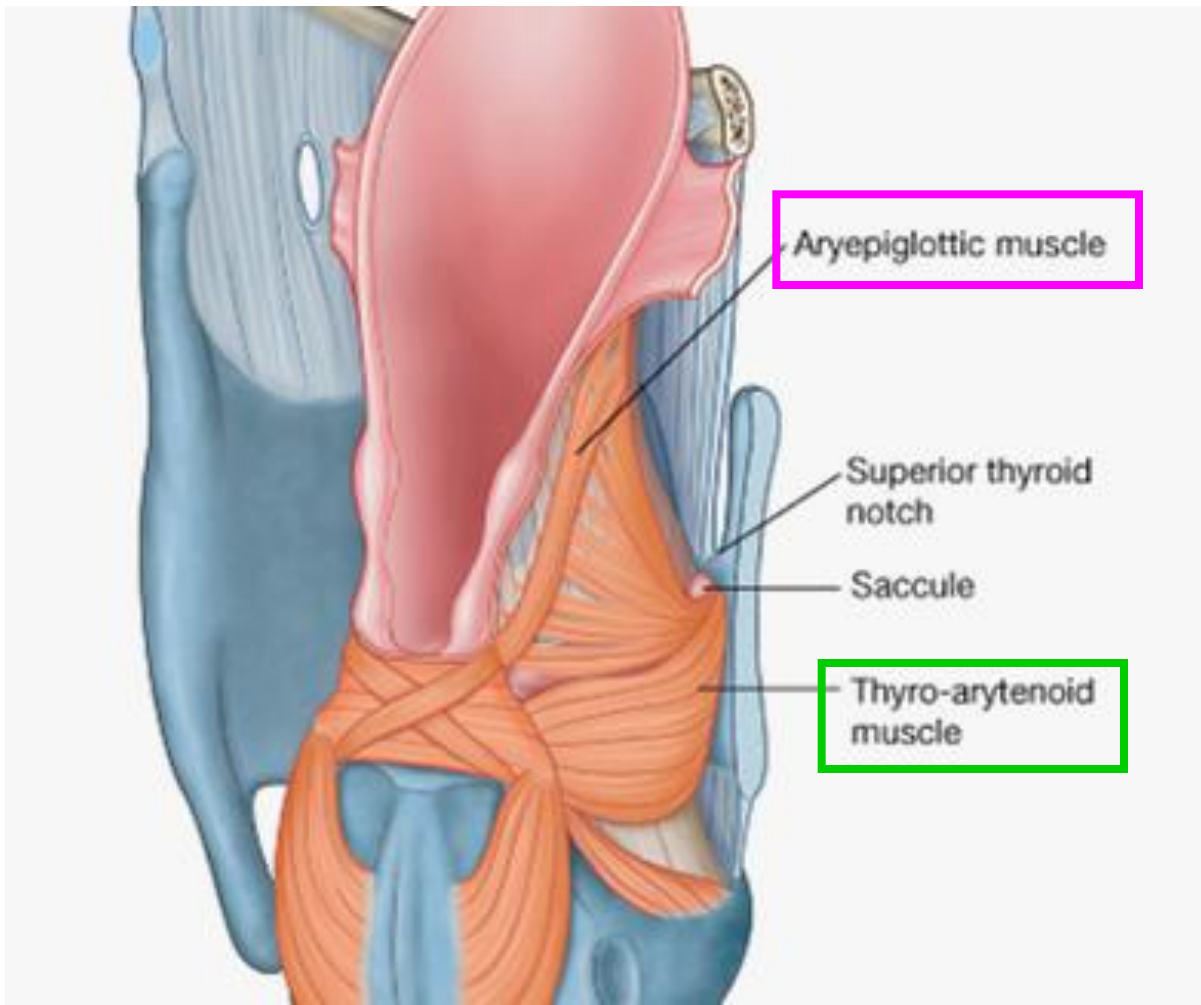
**transverse arytenoid m.** (close)

**oblique arytenoid m.** (close of laryngeal inlet)

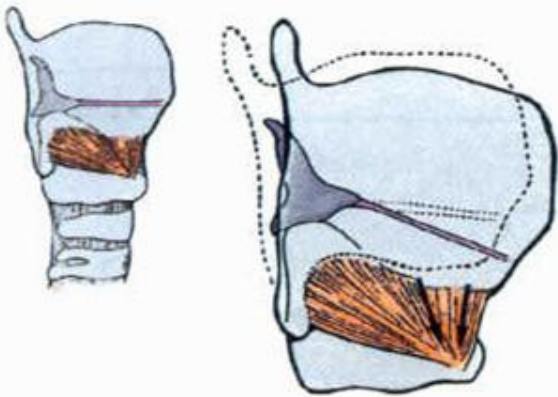
**vocalis m.** (adjust tension in vocal fold)



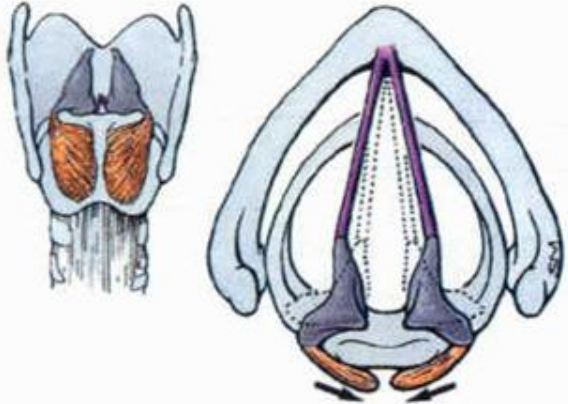
**oblique arytenoid m. (aryepiglottic part)**  
(sphincter of laryngeal inlet)  
**thyroarytenoid m. (thyroepiglottic part)**  
(sphincter of vestibule and laryngeal inlet)



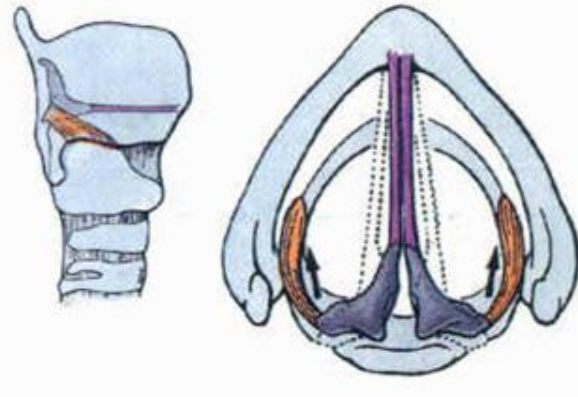
**Table 8.5. Actions of Laryngeal Muscles**



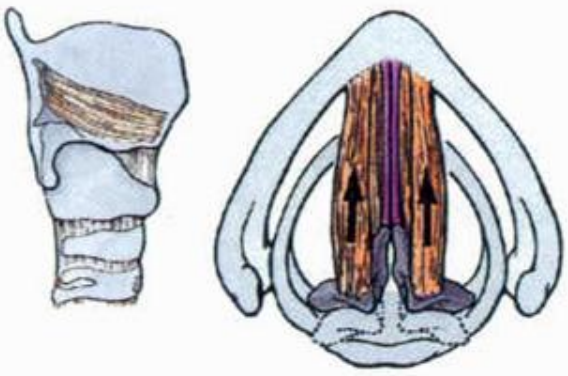
Lateral view  
**Cricothyroid**



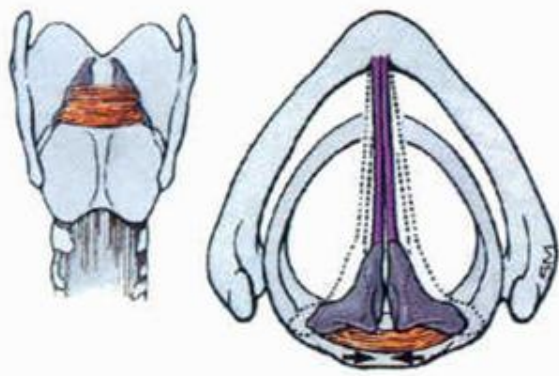
Superior view  
**Posterior cricoarytenoid**



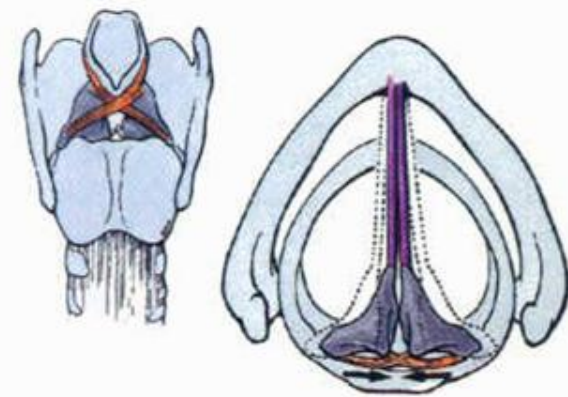
Superior view  
**Lateral cricoarytenoid**



Superior view  
**Thyroarytenoid**

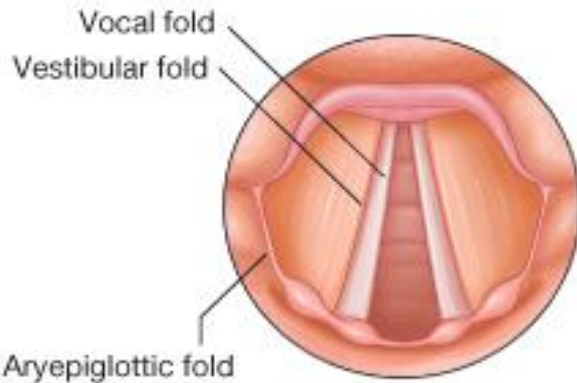


Superior view  
**Transverse arytenoid**



Superior view  
**Oblique arytenoid**

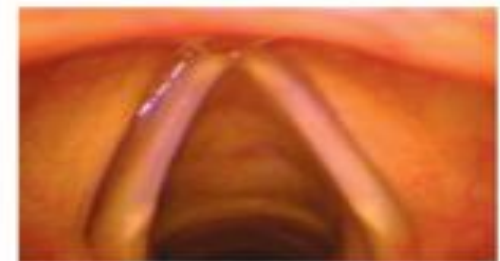
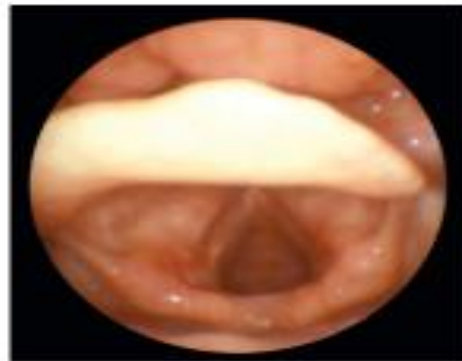
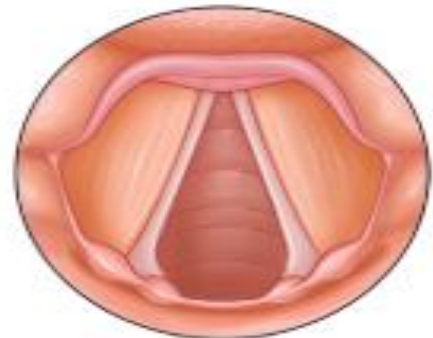


**A****Quiet respiration**

Drake et al: Gray's Anatomy for Students www.stu

**B****Forced inspiration**

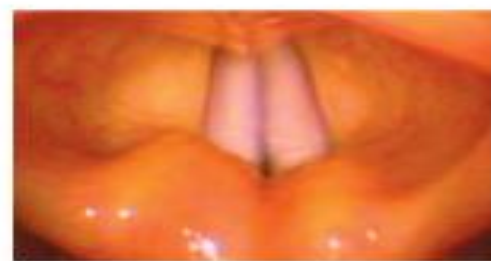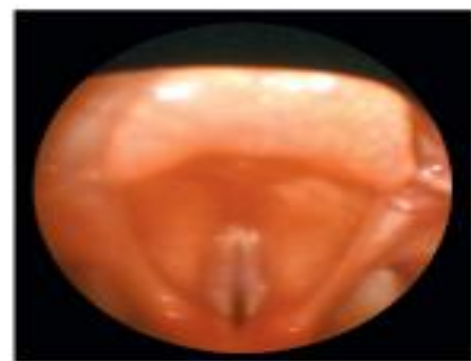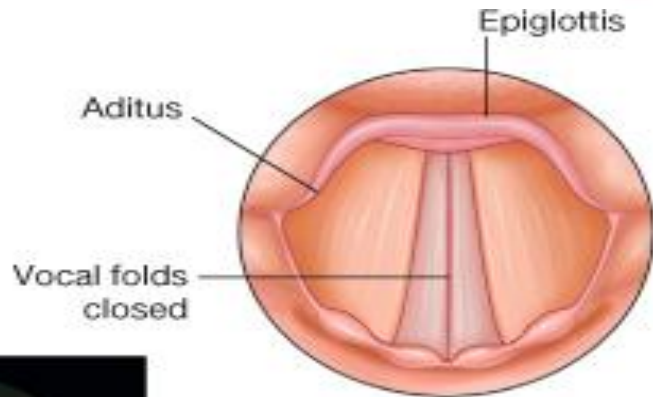
- vocal folds abducted and rima glottidis wide open
- vestibule open



Drake et al: Gray's Anatomy for Students www.studentcon

**C****Phonation**

- vocal folds adducted and stridulating as air is forced between them
- vestibule open



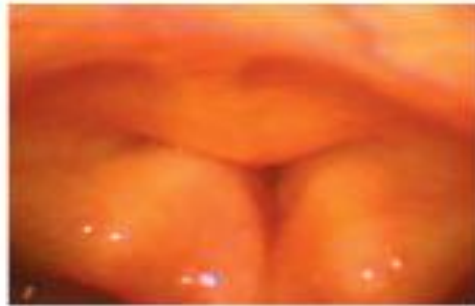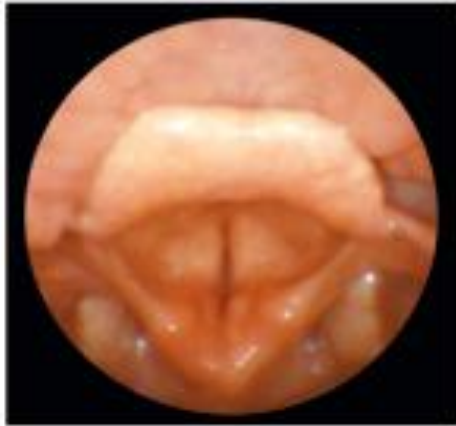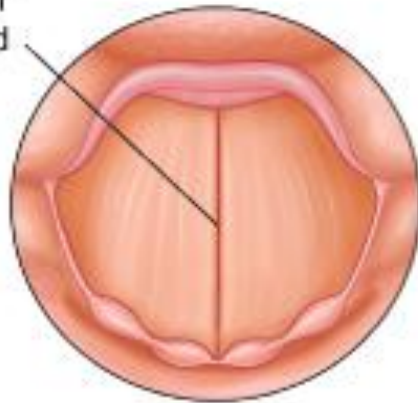
Drake et al: Gray's Anatomy for Students www.studentcon

**D**

**Effort closure**

- vocal folds and vestibular folds adducted
- rima glottidis and vestibule closed

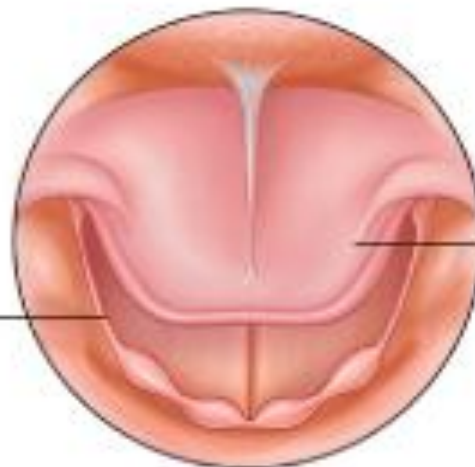
Vestibular folds closed



**E**

**Swallowing**

Aditus narrowed



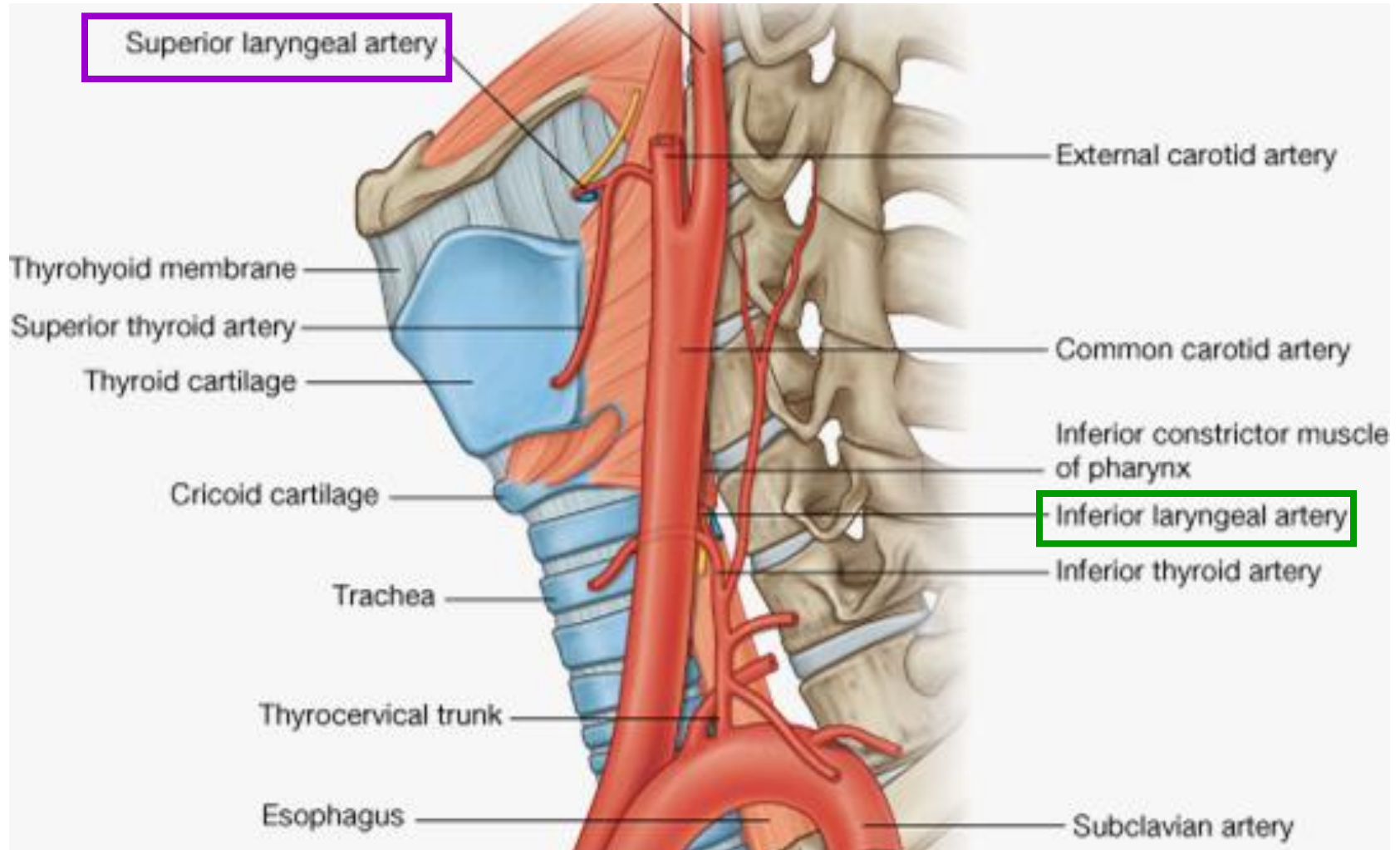
Epiglottis swings down to arytenoids

# Vessels of the larynx

## Arteries:

**Sup. laryngeal artery** (branches of sup. thyroid artery)

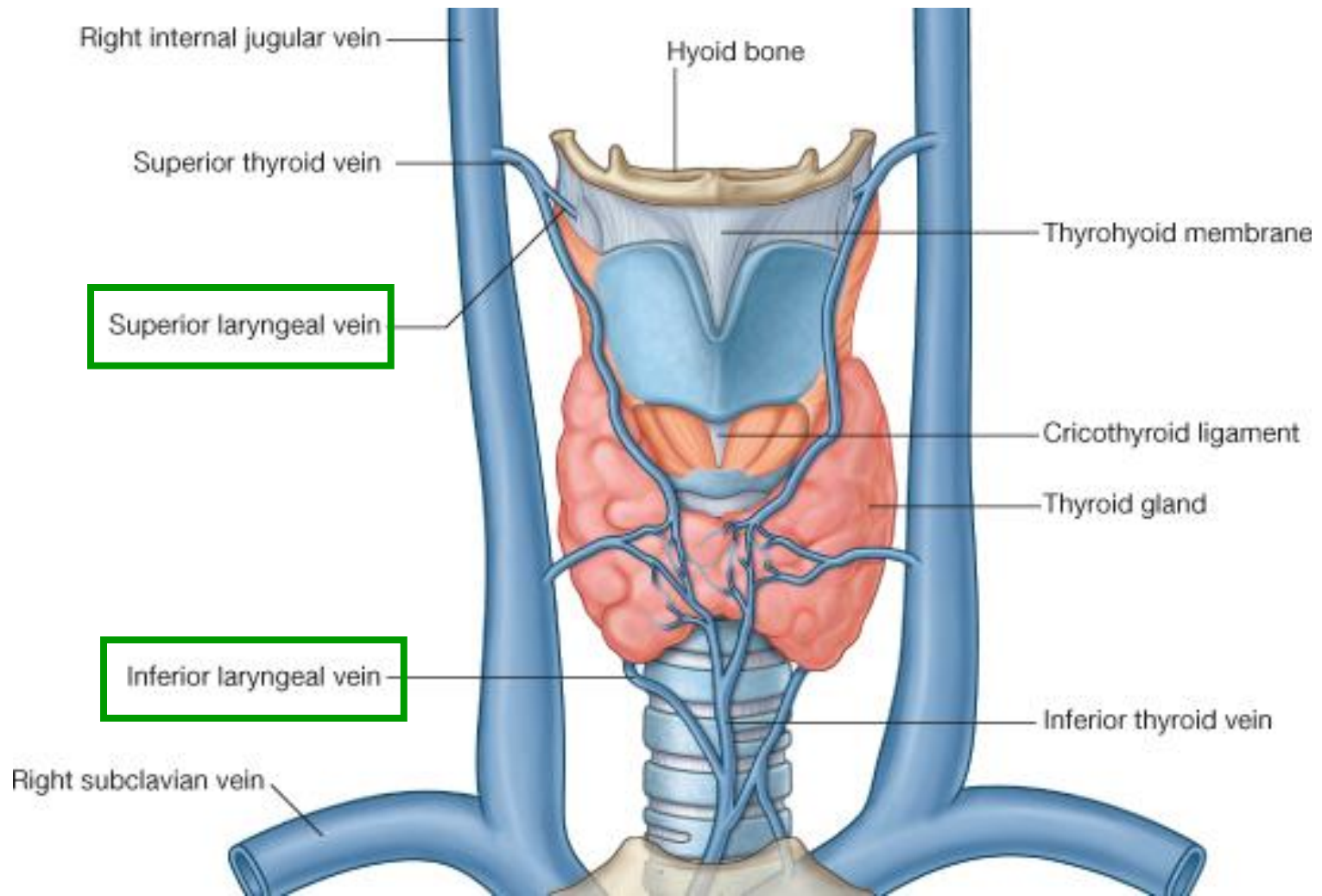
**Inf. laryngeal artery** (branches of inf. thyroid artery)



**Veins:** accompany the laryngeal arteries

**Sup. laryngeal vein** → sup. thyroid vein → IJV

**Inf. laryngeal vein** → inf. thyroid vein  
→ left brachiocephalic v.



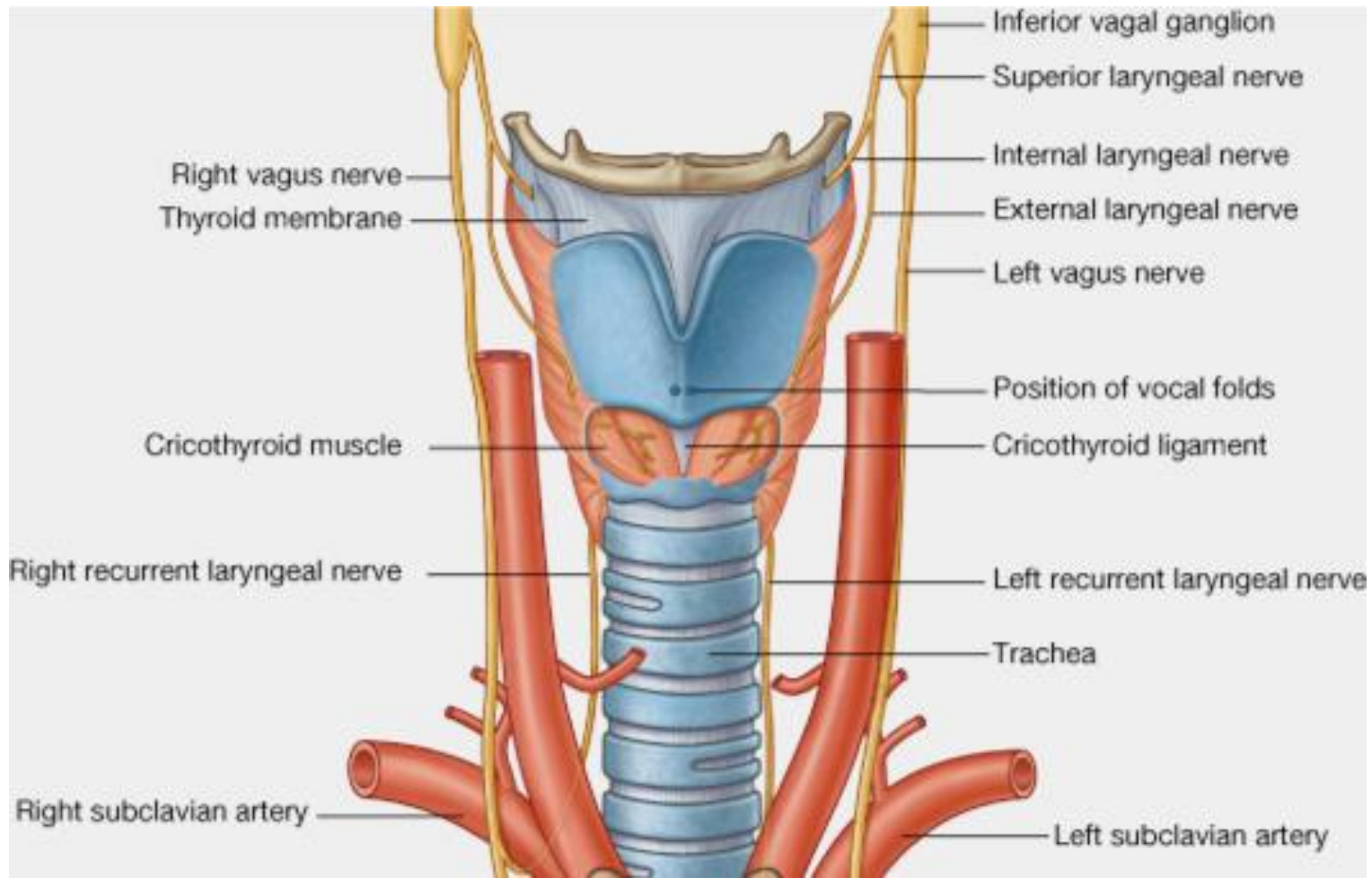
**Nerves:** branches of **vagus nerve**

**Sup. laryngeal nerve** (from inf. vagal ganglion)

→ **internal laryngeal nerve** (sensory and autonomic)  
**external laryngeal nerve** (motor)

**Inf. laryngeal nerve**

(terminal part of recurrent laryngeal n.– motor nerve)



# **Dissection of Larynx**

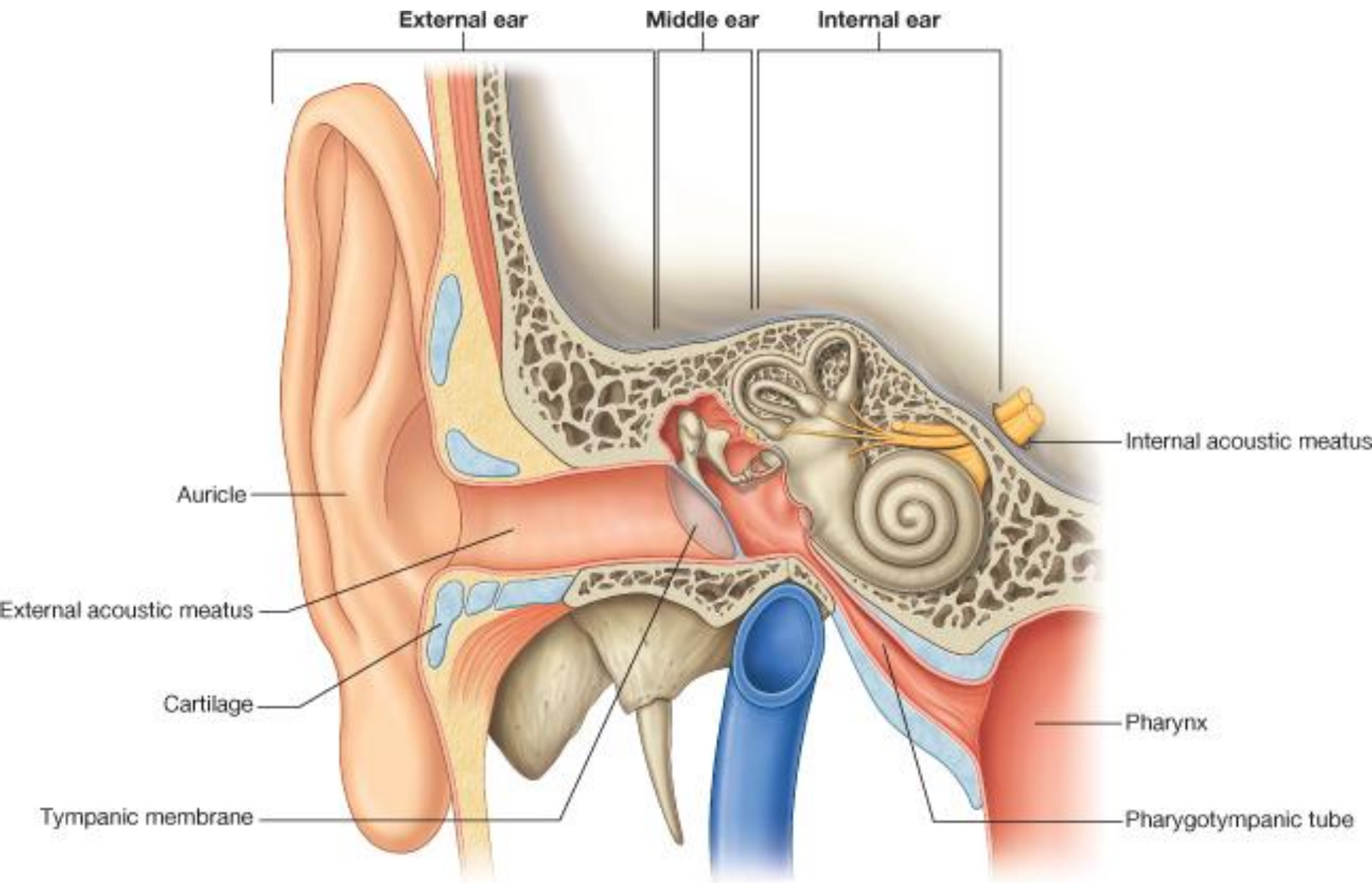
# Larynx

1. Examine **thyroid, cricoid, arytenoid, epiglottic cartilages** and **vocal ligaments**.
2. Carefully trace the **internal laryngeal nerve** & **recurrent laryngeal nerve**.
3. Remove mucosa of **piriform recess** to expose **intrinsic laryngeal muscles**.
4. Identify **posterior cricoarytenoid muscles, arytenoid muscles** (*transverse & oblique fibers*).  
*oblique fibers also called aryepiglotticus.*

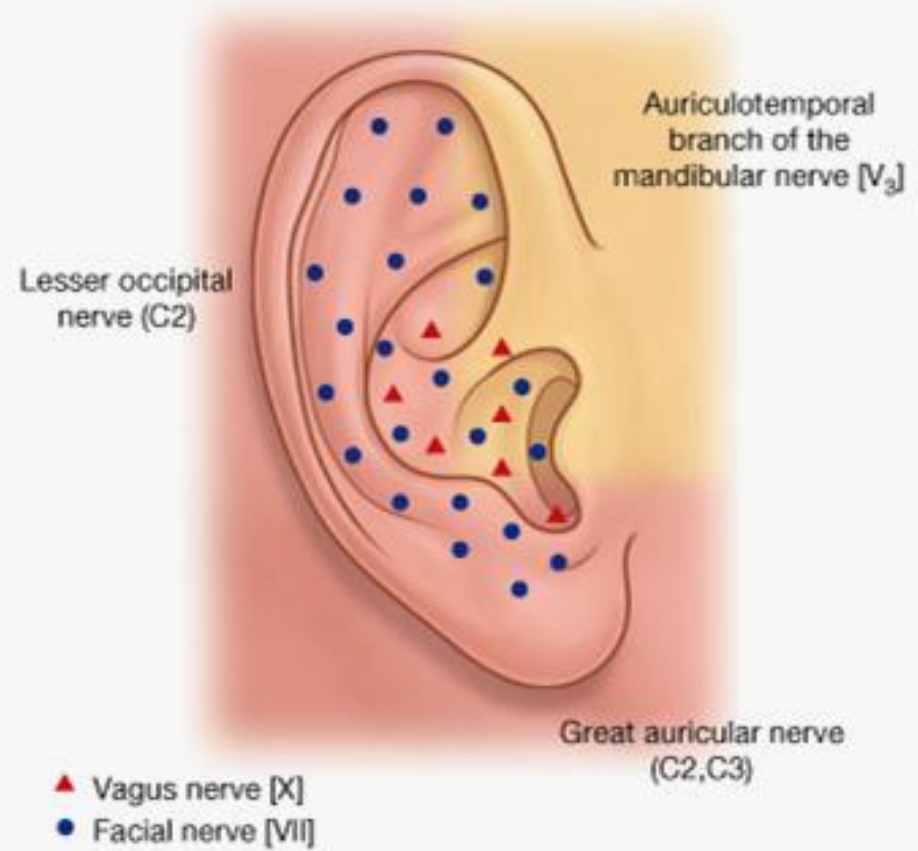
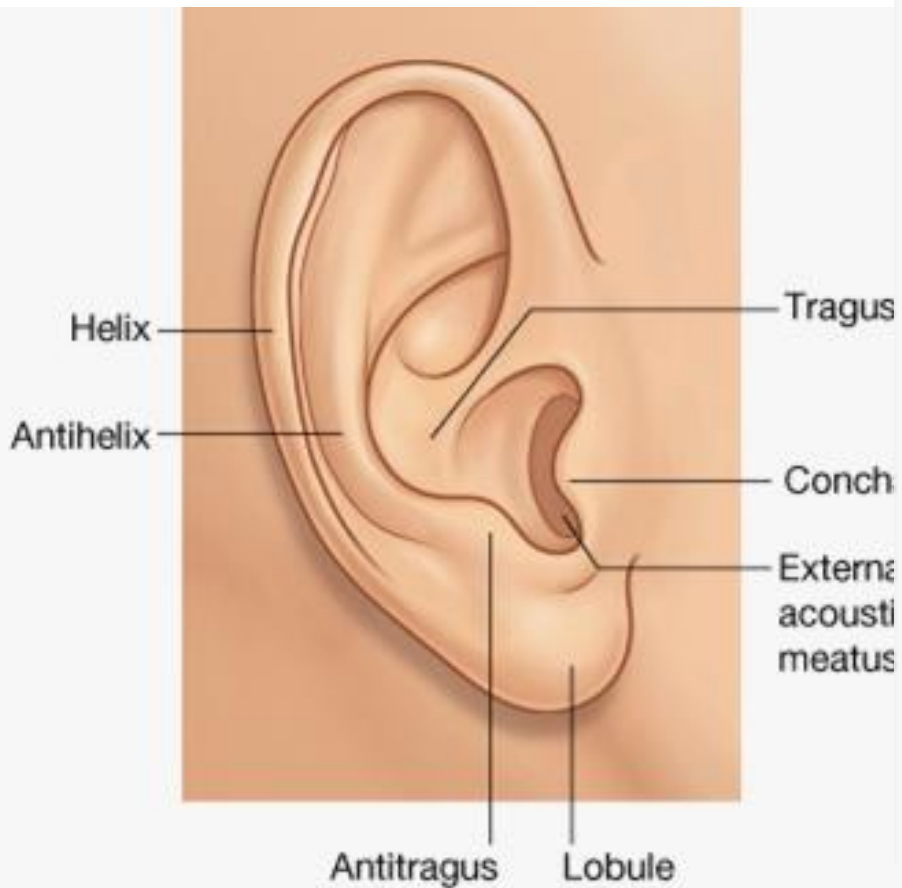
5. Define **cricothyroid joint**, just posterior to the joint run **recurrent laryngeal nerve**.
6. Cut lamina of thyroid cartilage about 8mm to the left of midline.
7. Reflect **thyroid lamina** inferiorly, **cricothyroid muscle** still attaches.
8. Identify **cricothyroid muscle**, **lateral cricoarytenoid**, **thyroarytenoid**, **vocalis & thyroepiglotticus**.
9. Examine **vestibular fold**, **vocal fold** & **ventricle**.



# Middle Ear



# Auricle

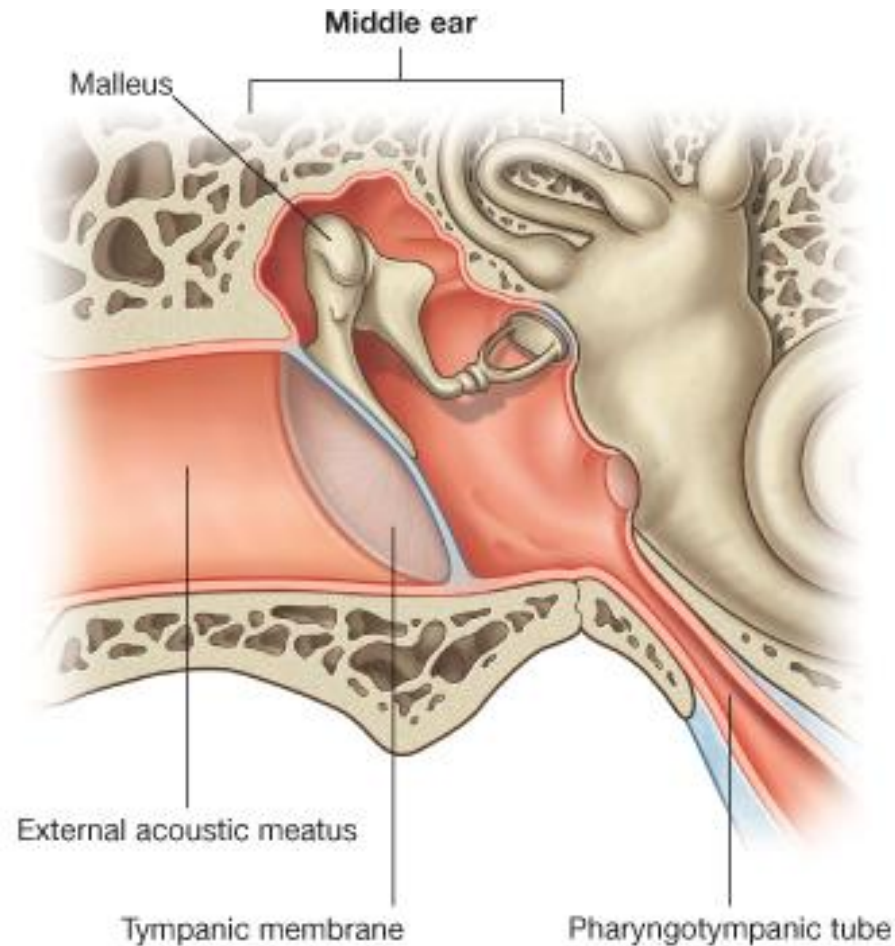


# Tympanic membrane

– fibrous membrane covered with thin skin (umbo)

External innervation: **auriculotemporal nerve (V3)**

Internal innervation: **glossopharyngeal nerve (IX)**

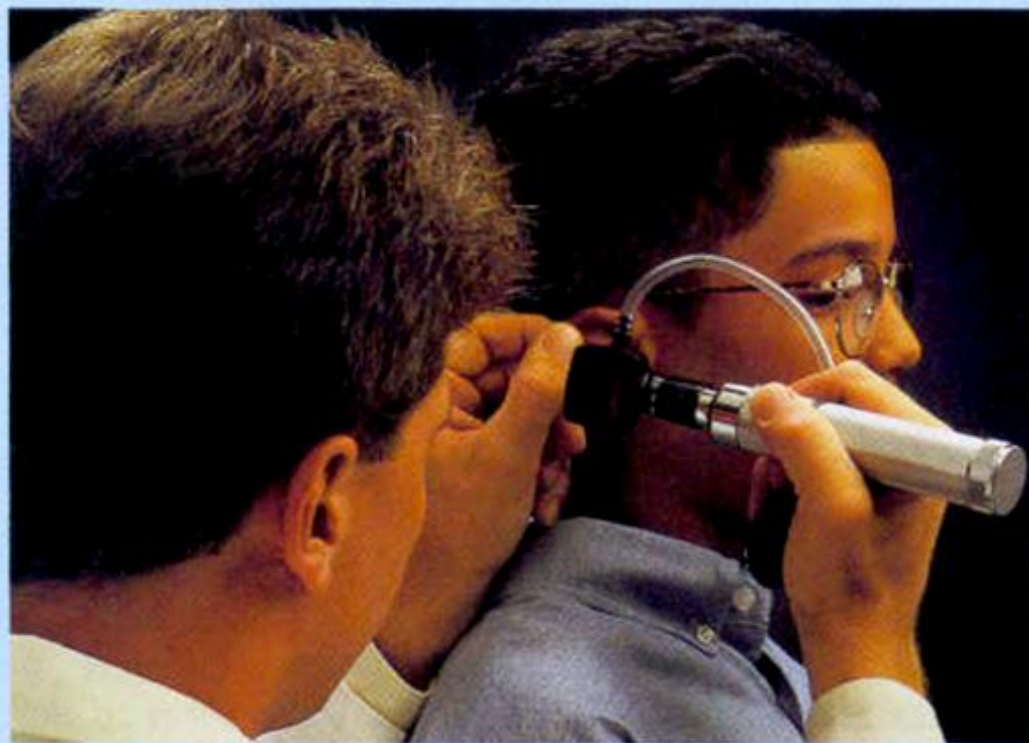


## External Ear Injury

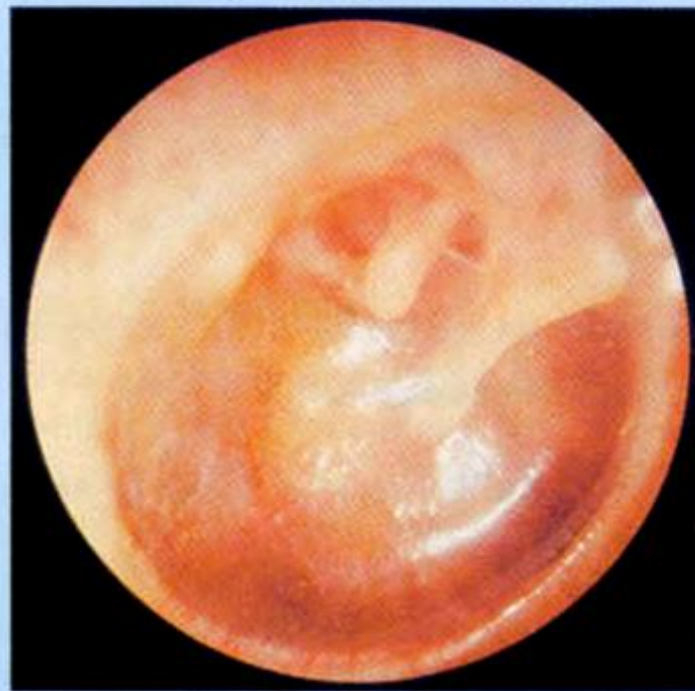Swelling within the auricle resulting from trauma may produce an *auricular hematoma*. The localized collection of blood forms between the perichondrium and auricular cartilage. As the hematoma enlarges it compromises the blood supply to the cartilage. If untreated (e.g., by aspiration), fibrosis—formation of fibrous tissue—develops in the underlying skin, forming a malformed auricle (e.g., the “ cauliflower ear” that occurs in some wrestlers).

## Otoscopic Examination

Examination of the external acoustic meatus and tympanic membrane begins by straightening the meatus. In addition, the helix is grasped and pulled posterosuperiorly (up, and back). These movements reduce the curvature of the external acoustic meatus, facilitating insertion of the *otoscope* (A). The external acoustic meatus is relatively short in infants; therefore, extra care must be exercised to prevent injury to the tympanic membrane. The meatus is straightened by

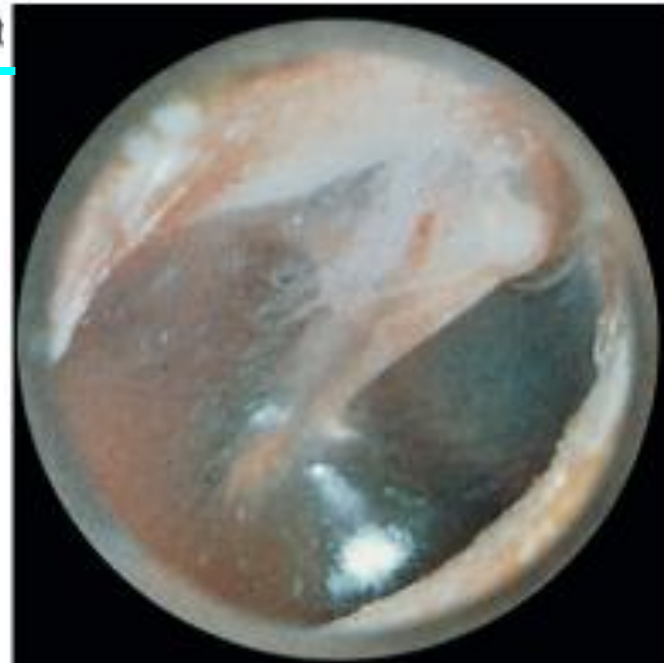
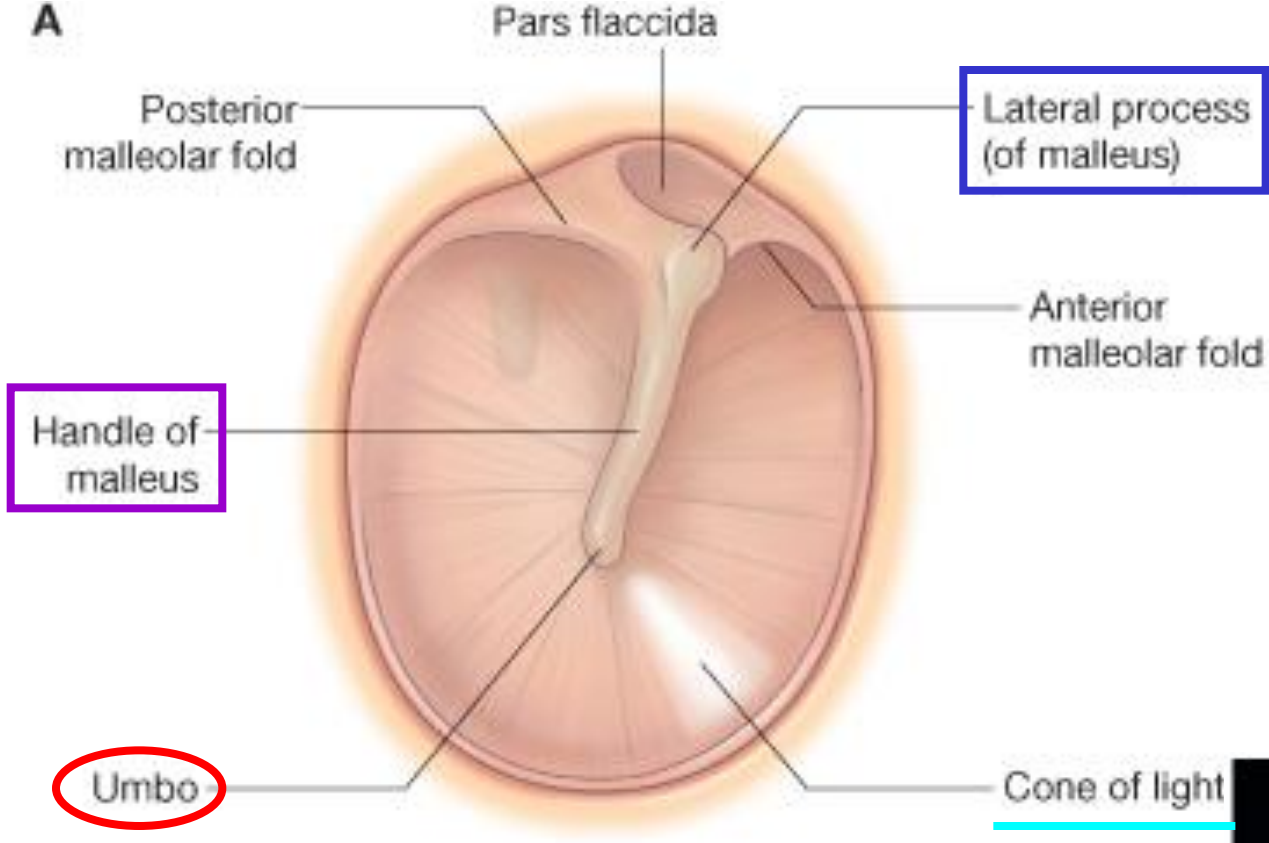


(A) Otoscopic examination



(B) Normal tympanic membrane

**A**



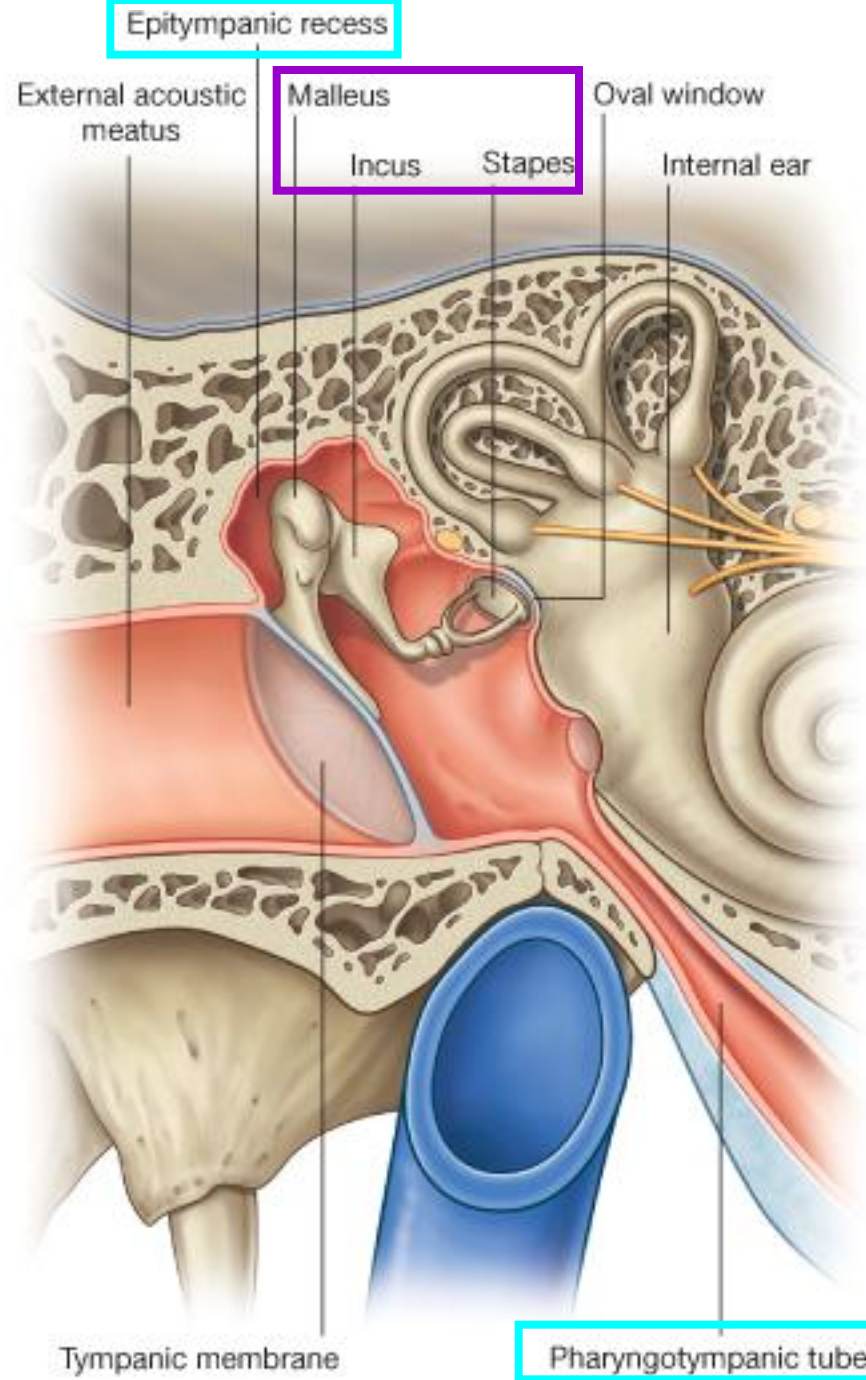
# Middle ear

Include: **tympanic cavity & epi-tympanic recess**

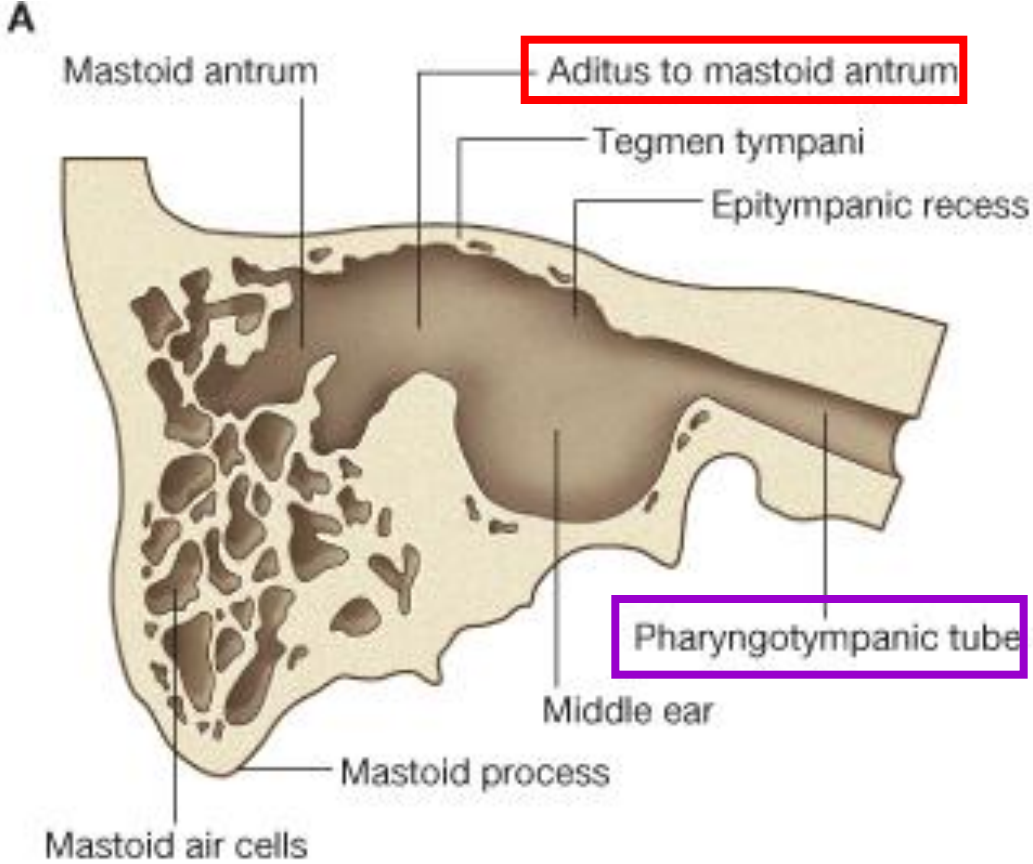
Connect: **pharyngo-tympanic tube & mastoid antrum**

Contents:

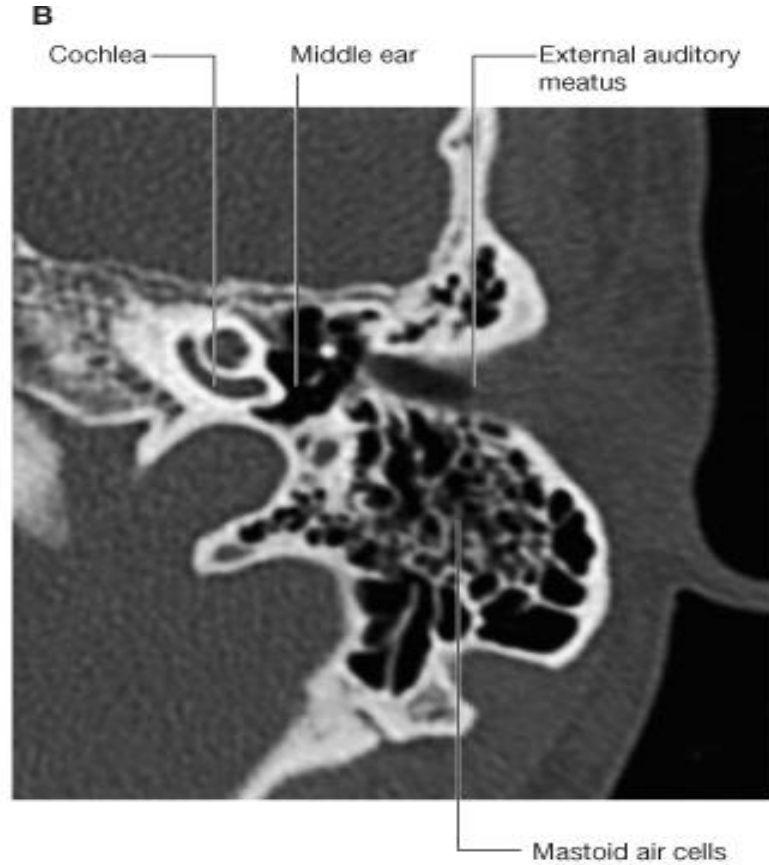**auditory ossicles (malleus, incus & stapes)**  
**stapedius & tensor tympani** muscles  
**chorda tympani nerve (CN VII) &**  
**tympanic plexus of nerve (CN IX)**







Ltd. Drake et al: Gray's Anatomy for Students www.studentc



r Ltd. Drake et al: Gray's Anatomy for Students www.studentc

# Walls of the tympanic cavity

roof: plate of bone

floor: near superior bulb of the IJV

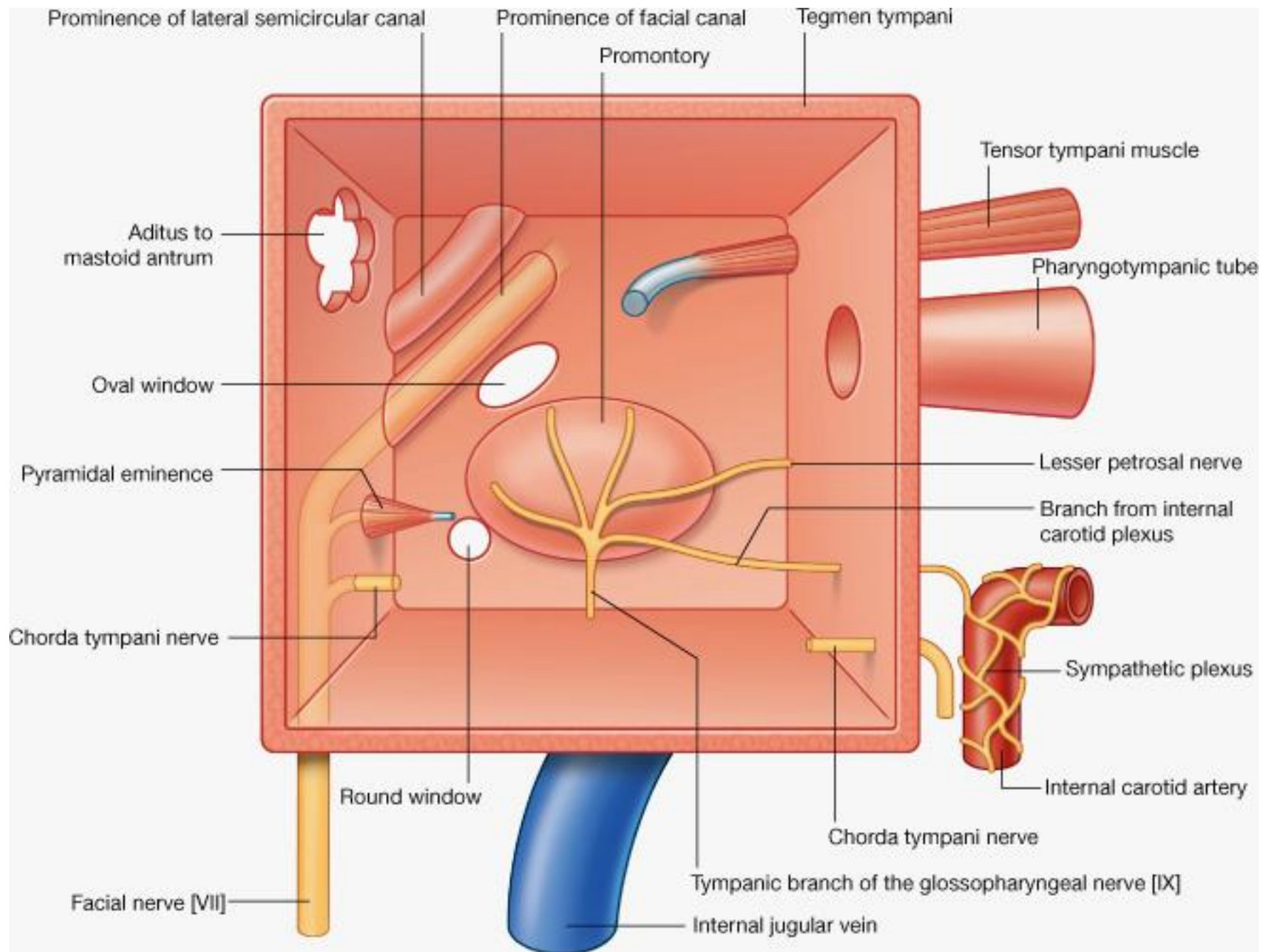
lateral wall: tympanic membrane

medial wall :

**promontory** – basal turn of the cochlea,  
**tympanic plexus**  
**oval window & round window**

anterior wall : opening for **auditory tube** &  
canal for **tensor tympani m.**

posterior wall : aditus to **mastoid antrum**  
origin of **stapedius** (pyramid eminence),  
**chorda tympani nerve**



# Auditory ossicles

(1) malleus      (2) incus      (3) stapes

## Muscles associated with the ossicles

(1) **tensor tympani:**

origin – cartilaginous part of auditory tube

insertion – handle of malleus

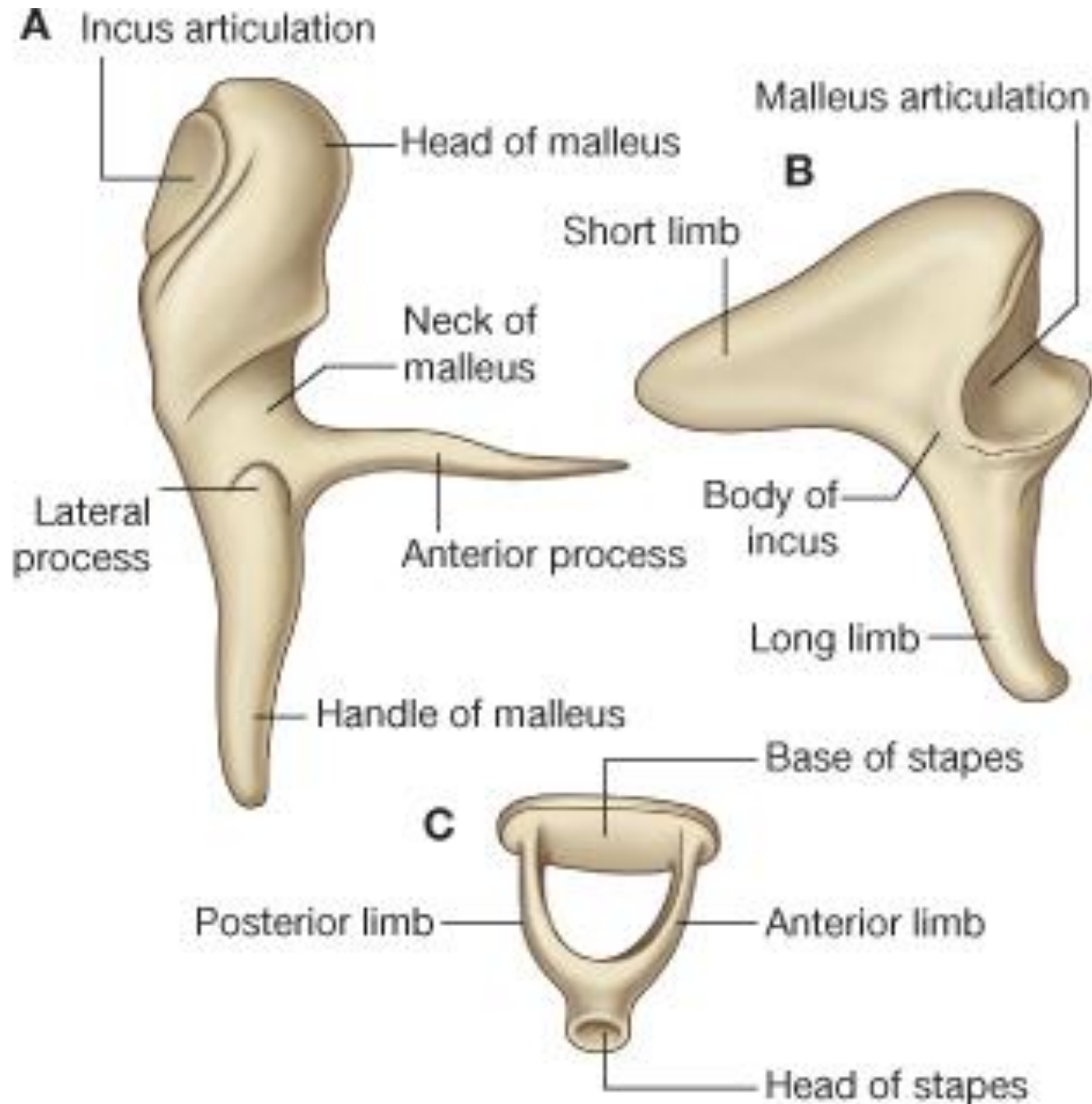
nerve: **mandibular nerve (CN V3)**

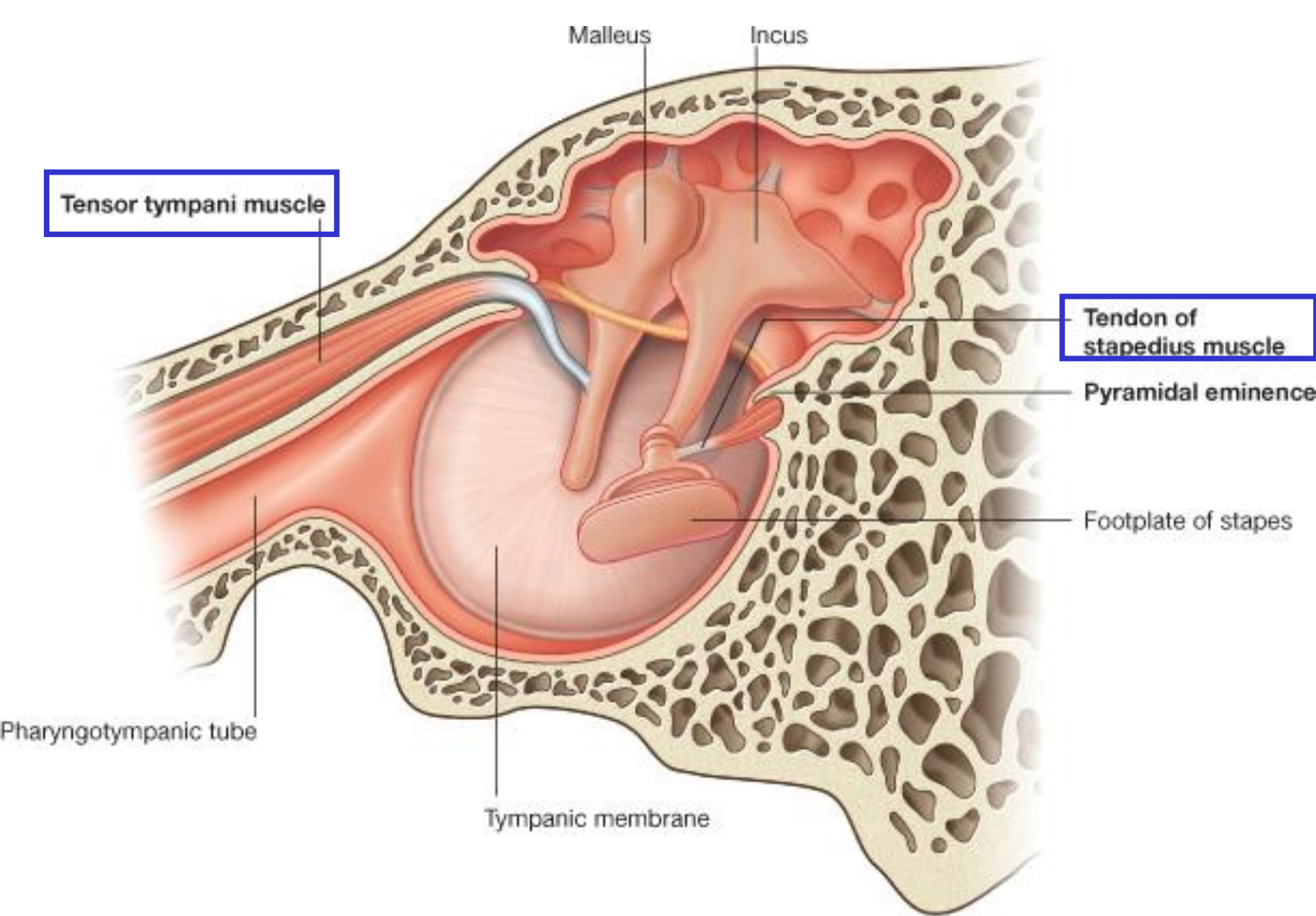
(2) **stapedius:**

origin – pyramid eminence

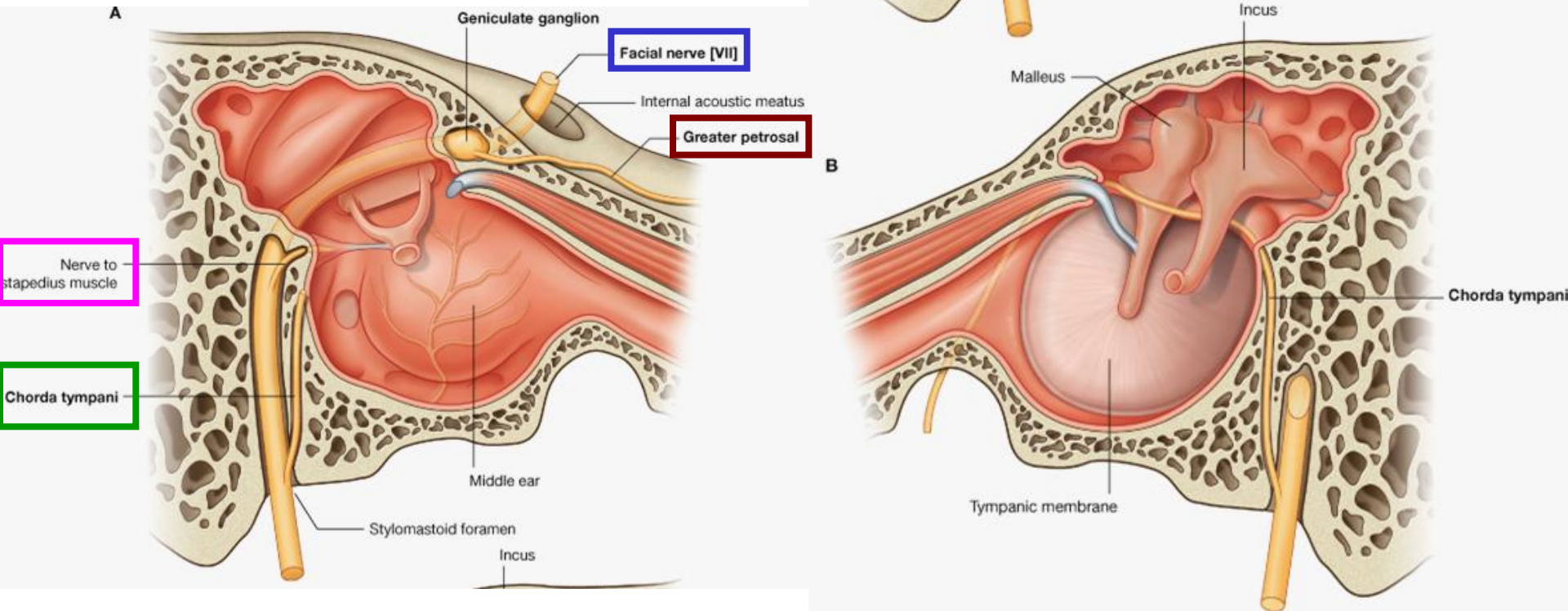
insertion – neck of stapes

nerve: **facial nerve (CN VII)**

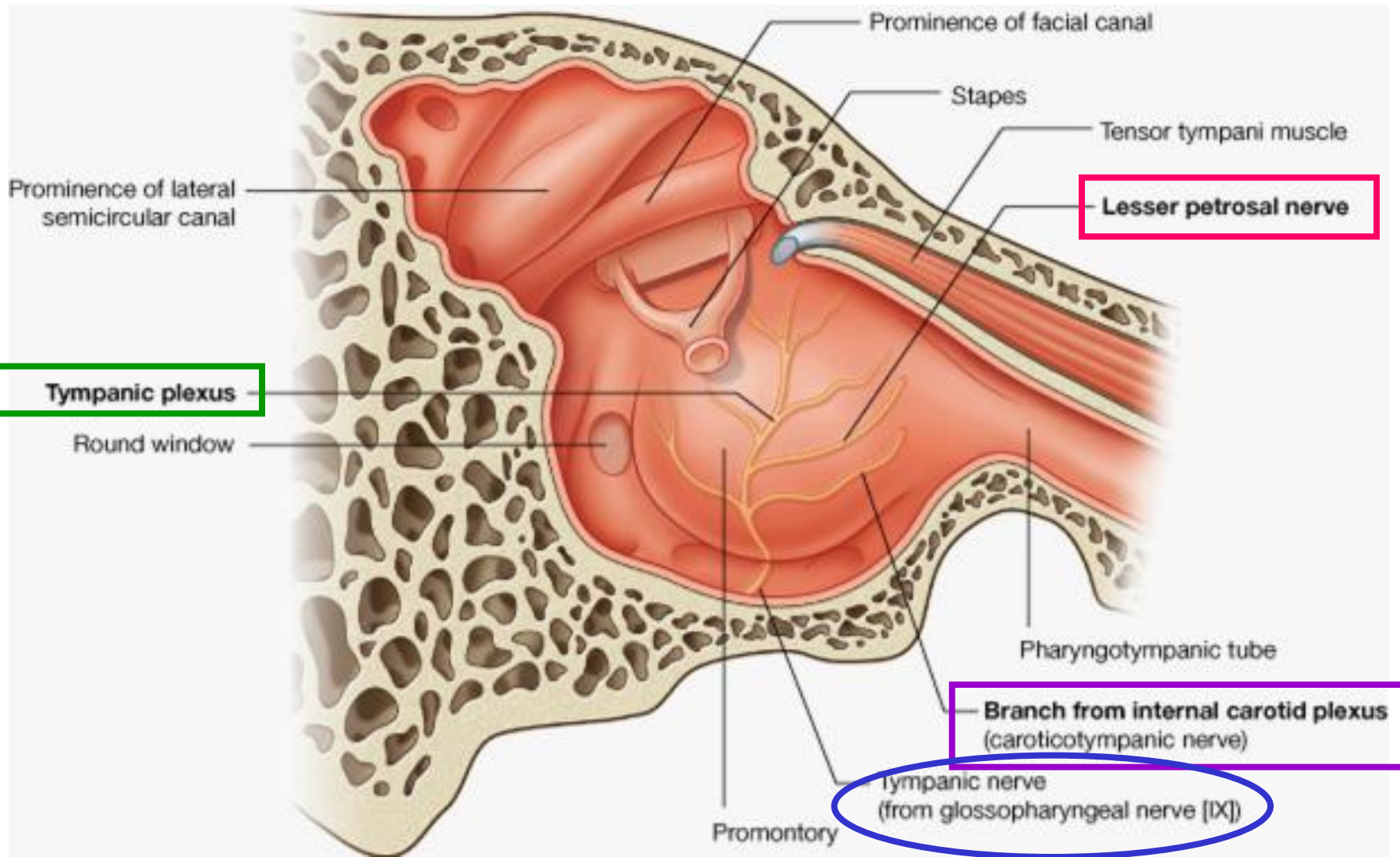




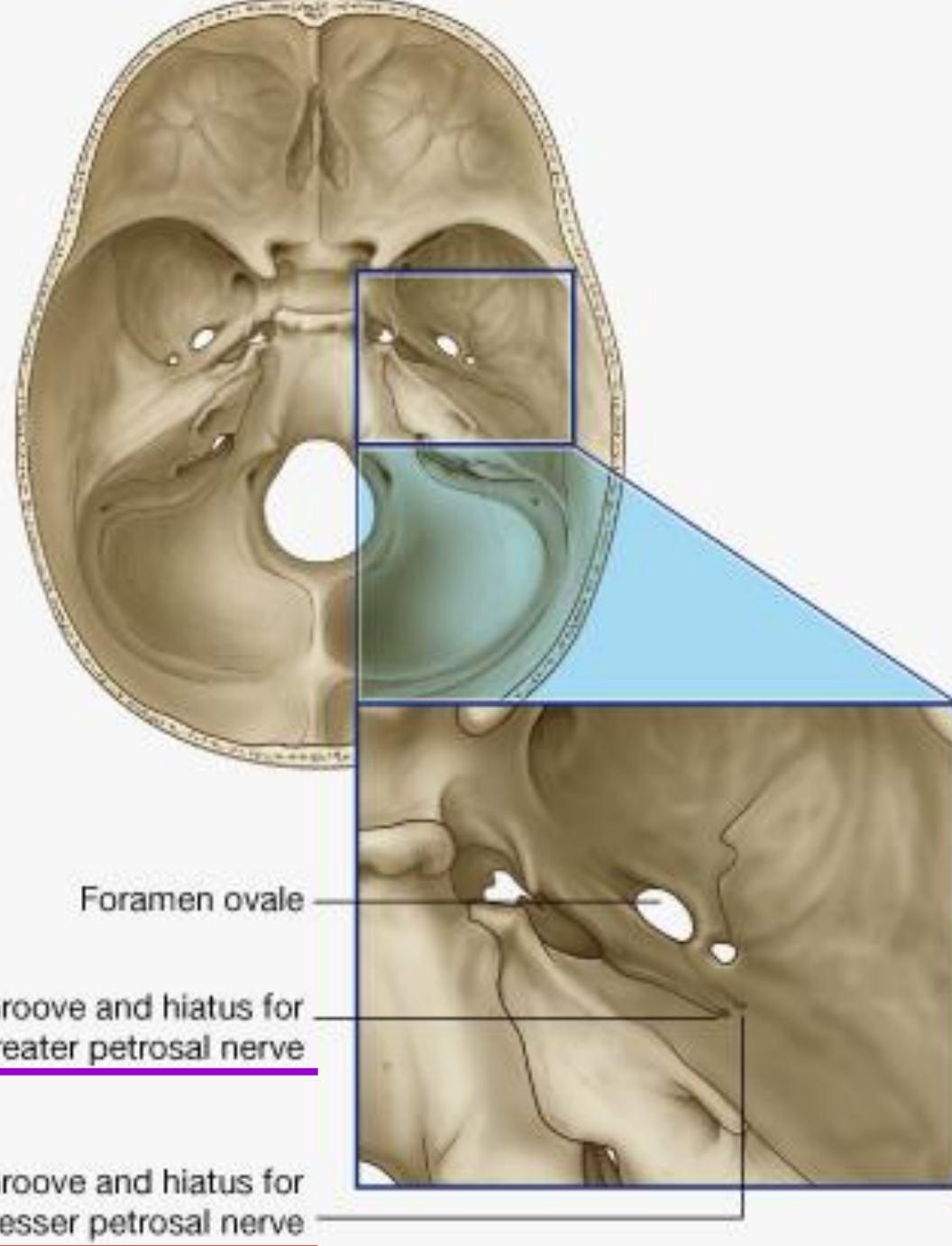
# Facial nerve (CN VII) in the temporal bone



# Glossopharyngeal nerve (CN IX) in the temporal bone







Foramen ovale

Groove and hiatus for greater petrosal nerve

Groove and hiatus for lesser petrosal nerve

# Pharyngo-tympanic tube (auditory tube)

Opening: posterior to the inferior meatus of nasal cavity

Function: *equalize pressure in middle ear*

Arteries: **ascending pharyngeal artery**

(external carotid artery)

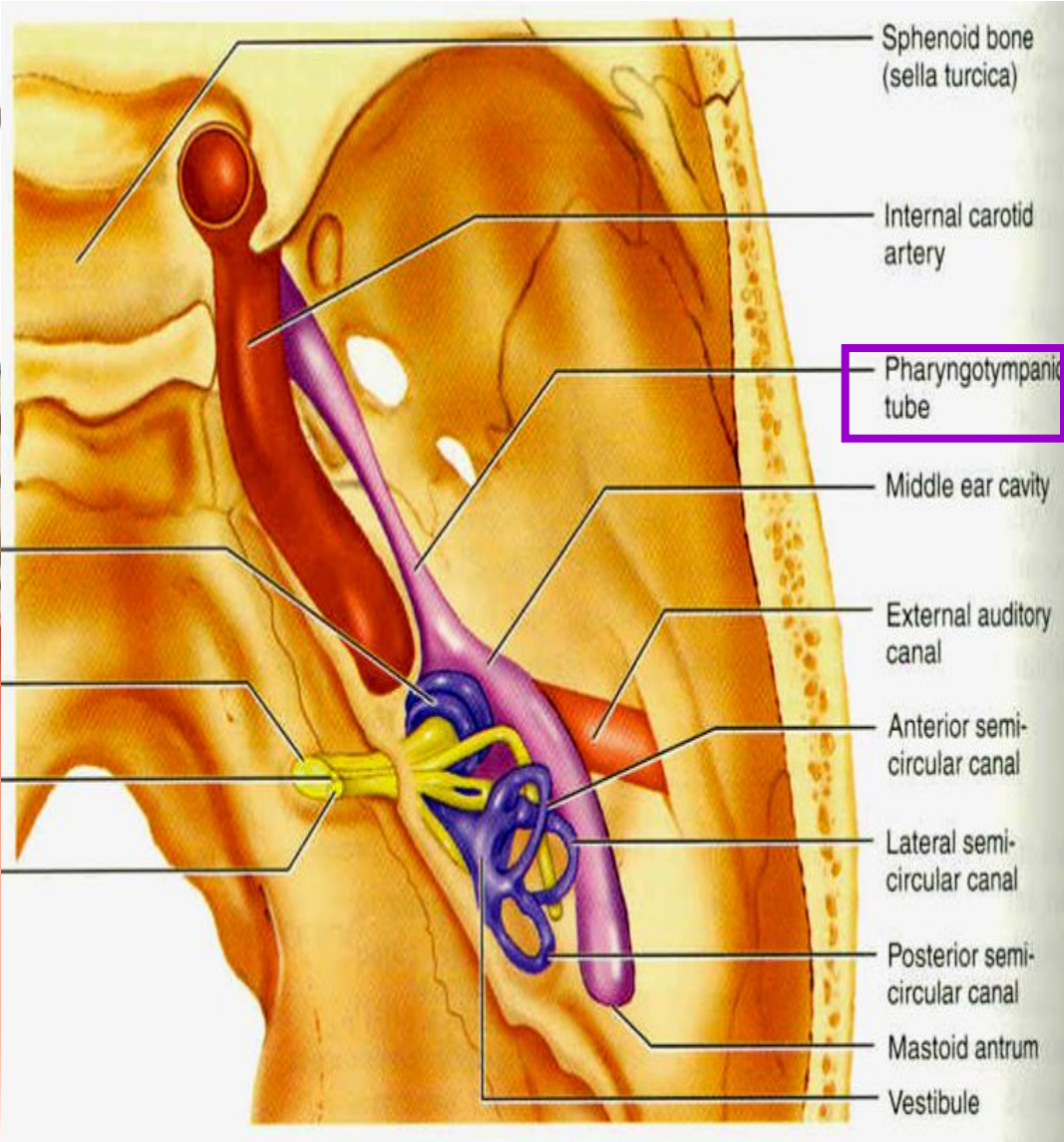
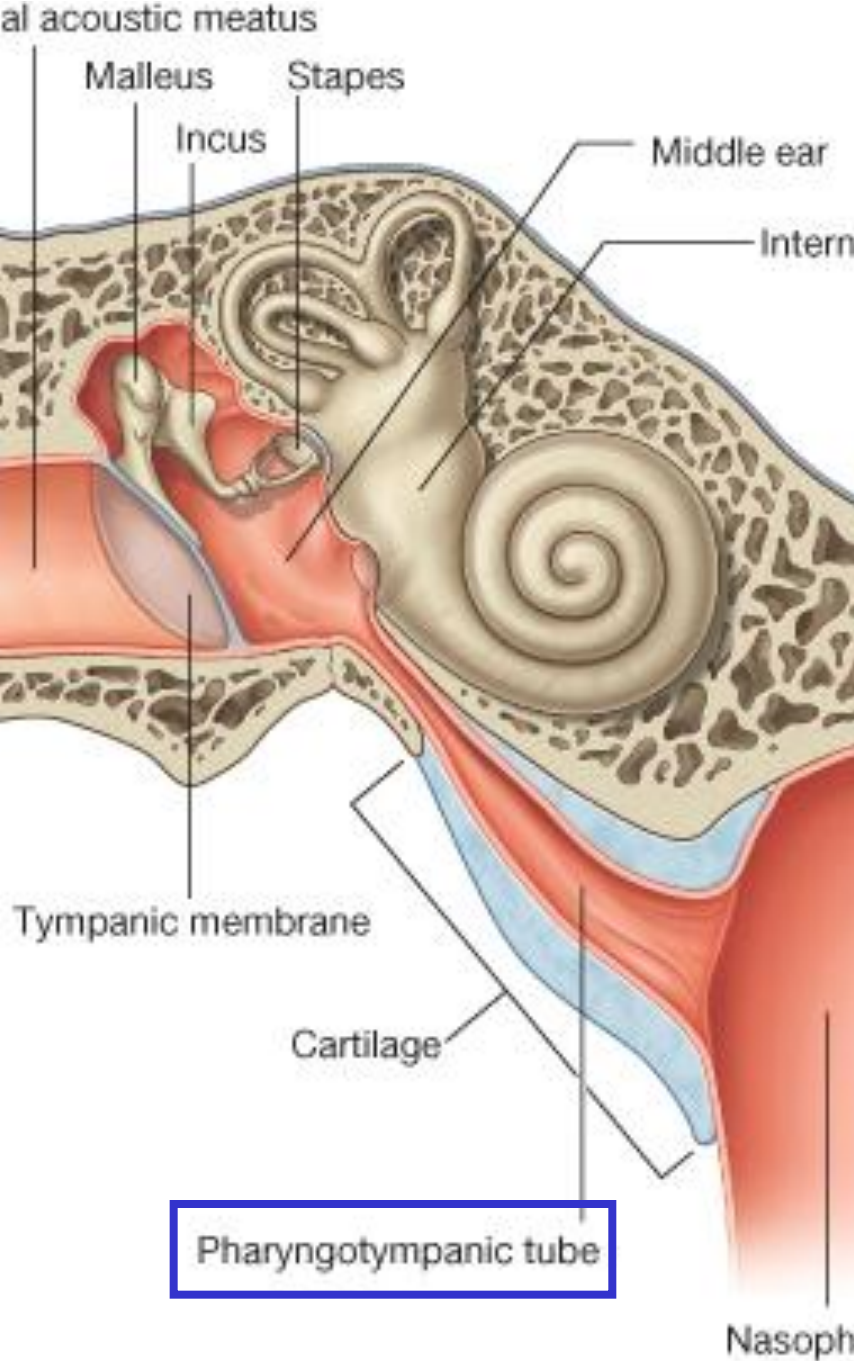
**middle meningeal artery** &

**artery of pterygoid canal** (maxillary artery)

Veins: drain into **pterygoid venous plexus**

Nerves: **tympanic plexus** &

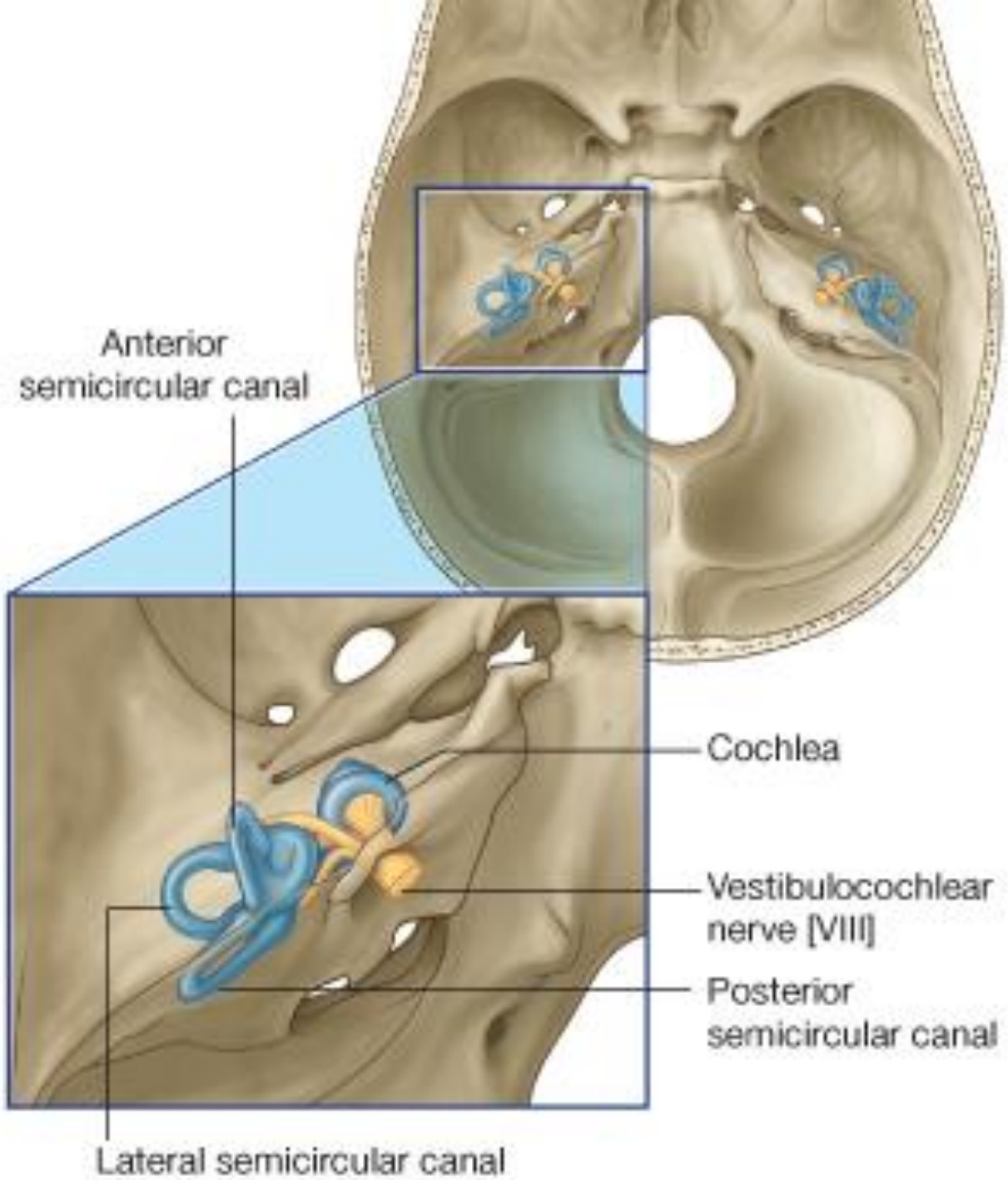
nerve fibers of pterygopalatine ganglion

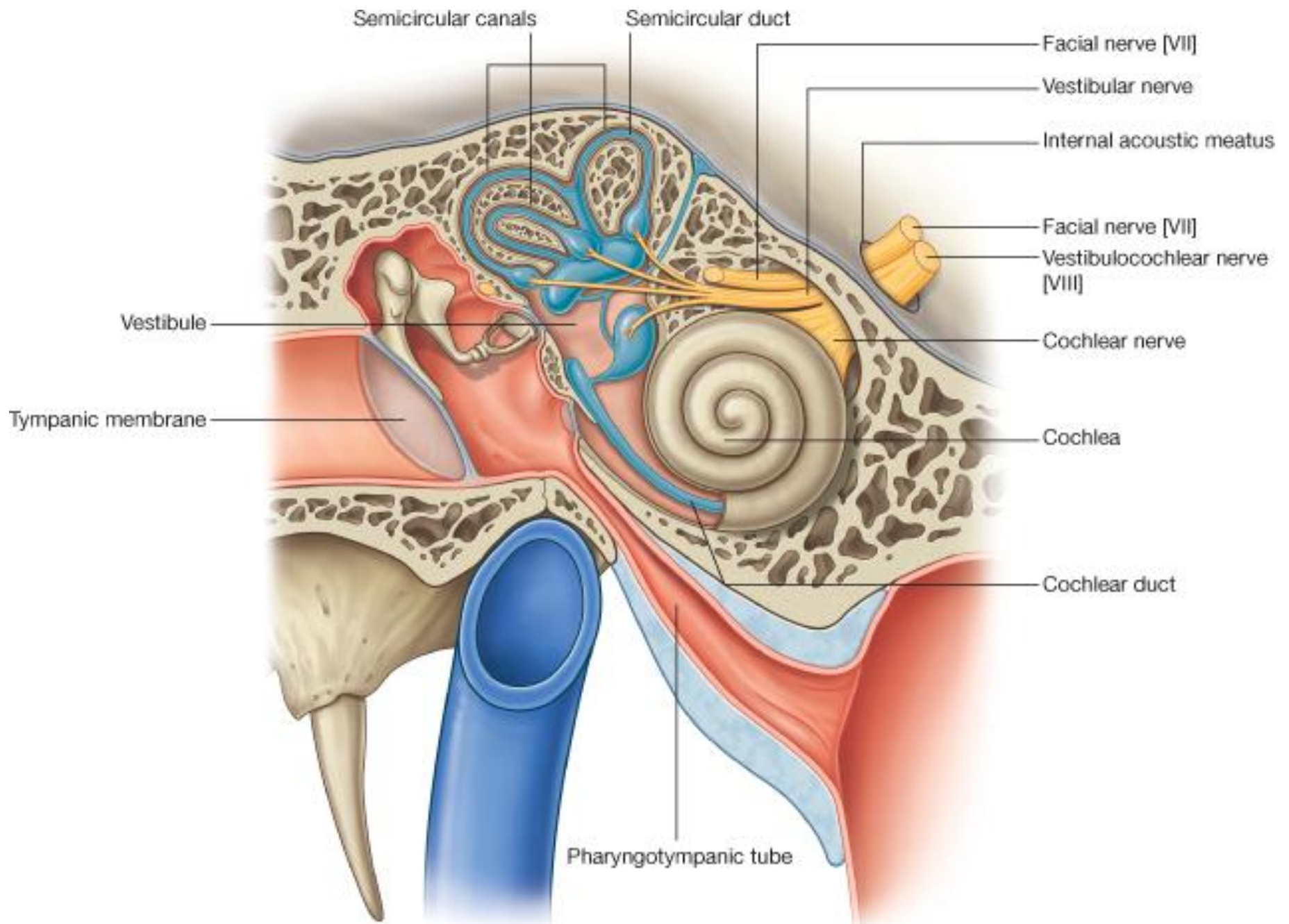


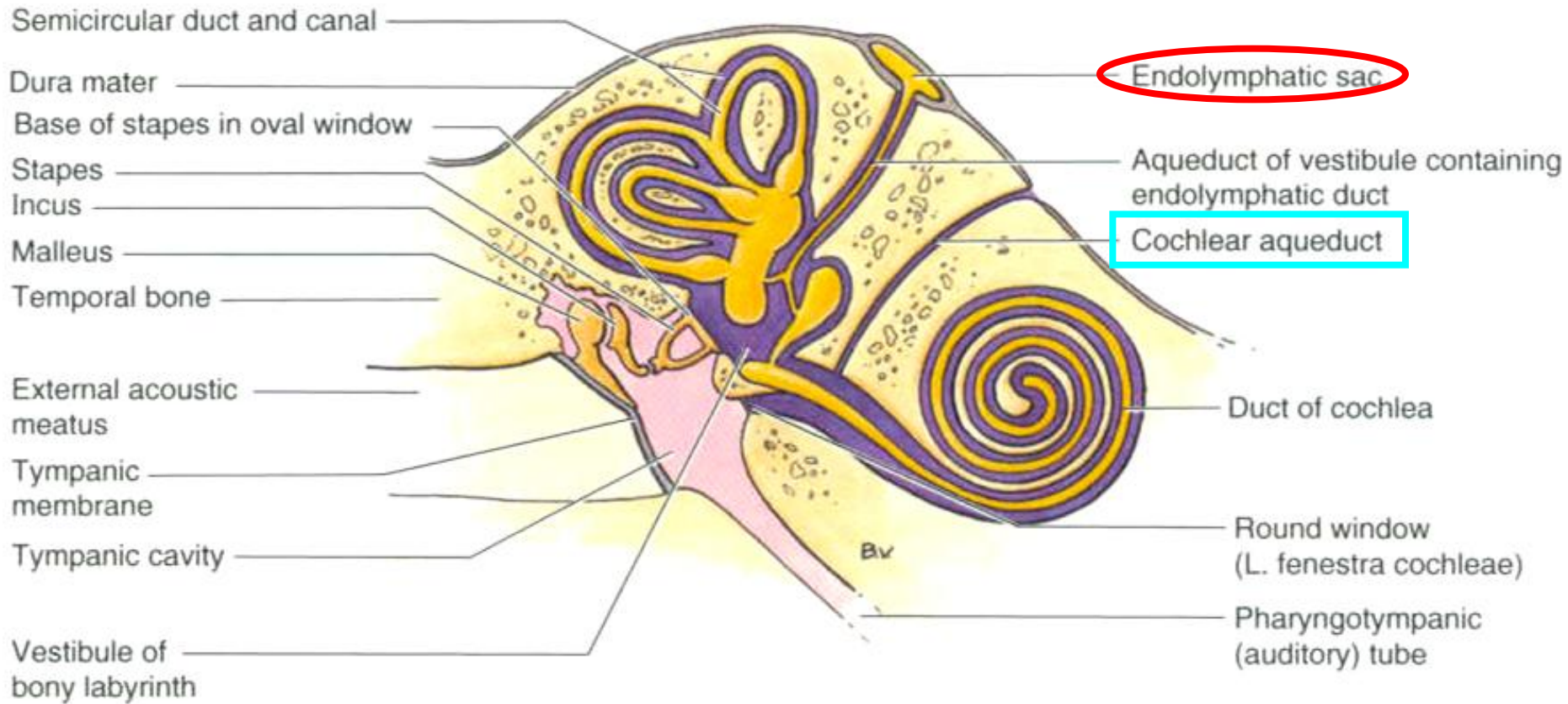
# Internal ear (contains vestibulocochlear organ)

## Bony labyrinth – perilymph

- (1) **cochlea** : modiolus (a bony core for vessels & nerves)  
**cochlear canaliculus (aqueduct)**  
– communicates with subarachnoid space
- (2) **vestibule** : contains **utricle** and **sacculle**  
(balancing apparatus)  
**vestibule aqueduct**  
(contains endolymphatic duct)
- (3) **semicircular canals**: ant., post. and lateral  
semicircular canals  
**ampulla** – end swelling







(B)

**Figure 7.76.** (Continued) **B.** The middle and internal parts of the ear. The *middle ear* (tympanic cavity)

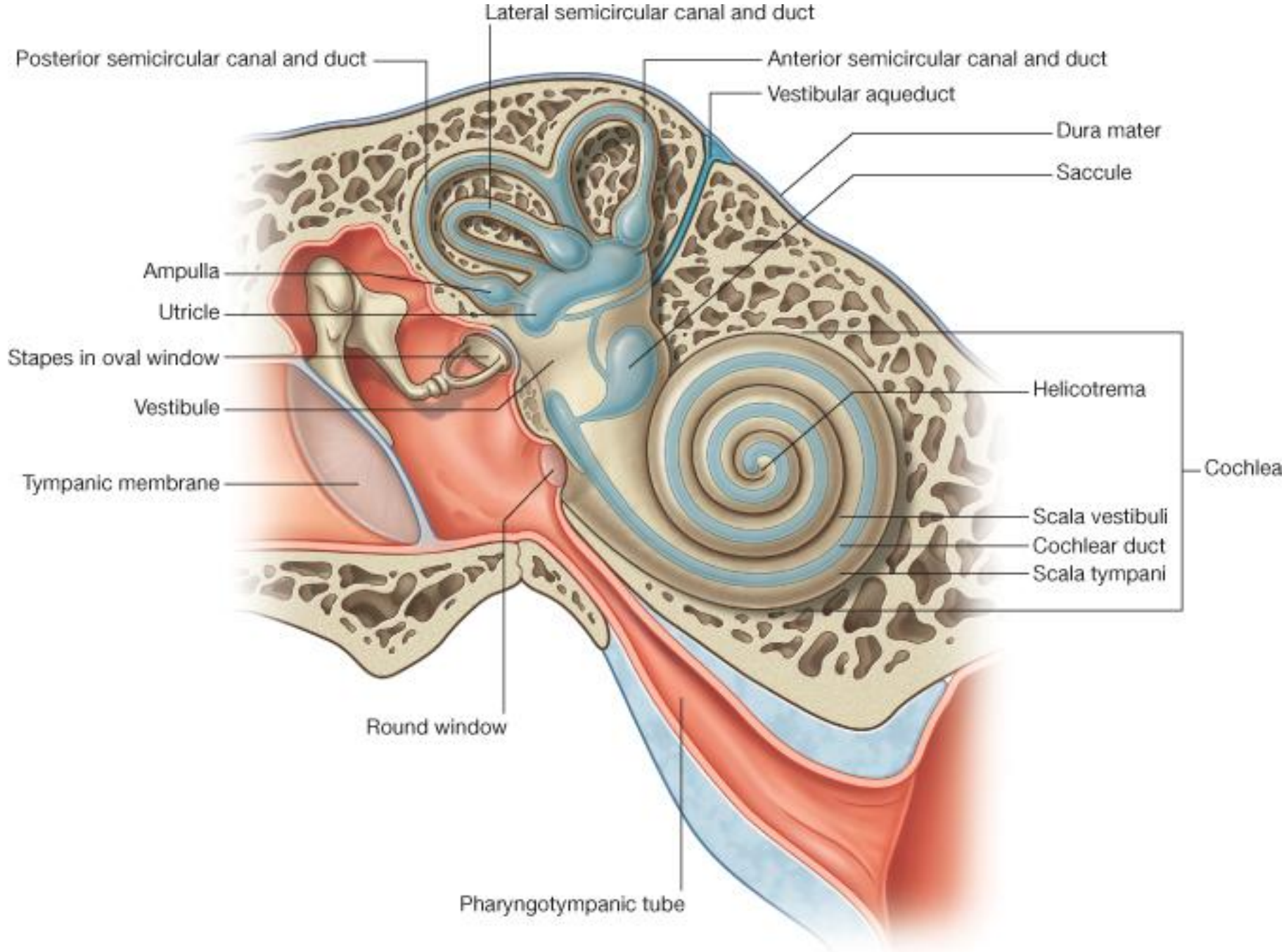
# Membrane labyrinth – **endolymph**

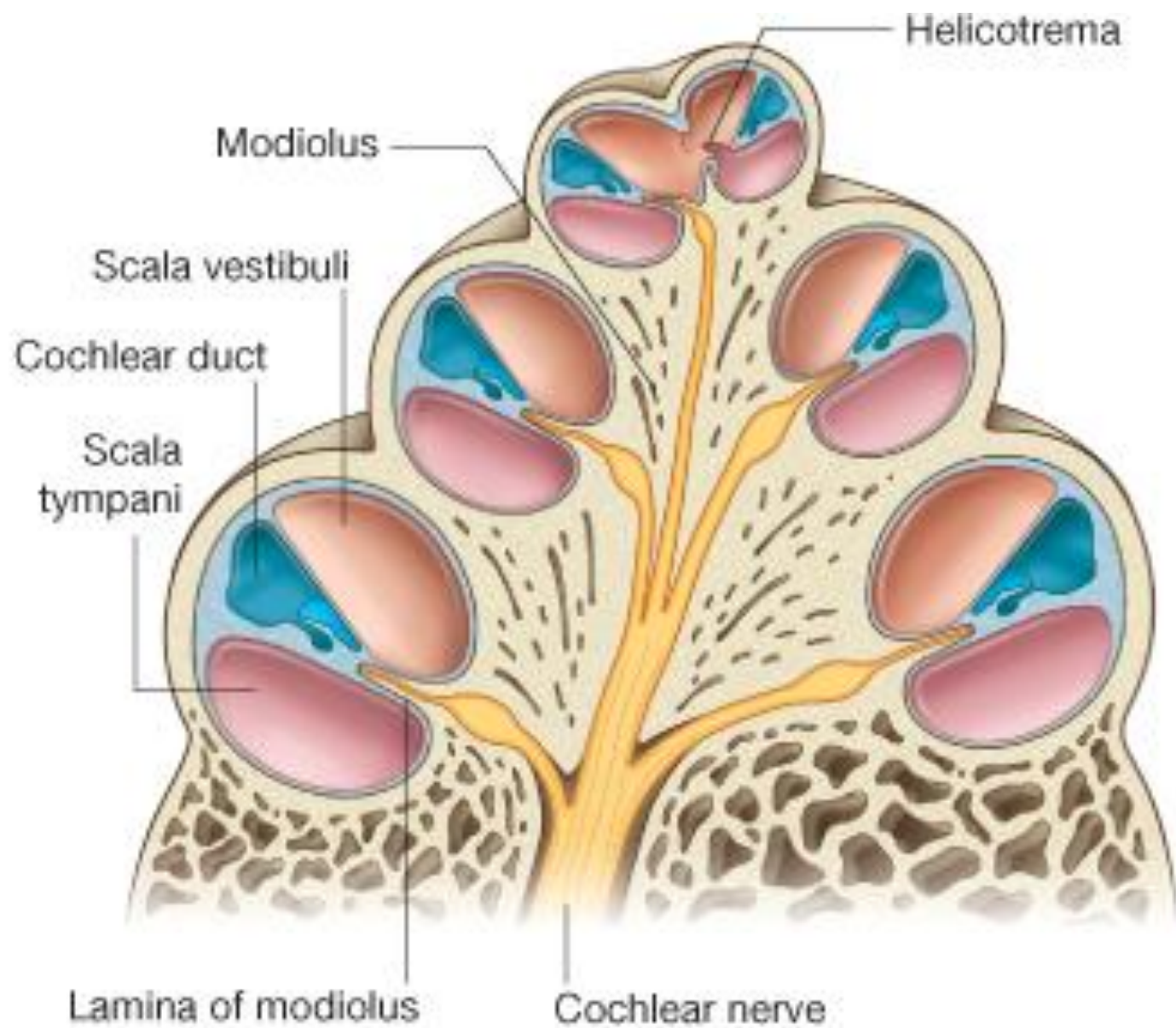
- (1) **cochlear duct** in cochlea  
(is fixed by **spiral ligament**)
- (2) **utricle** & **sacculle** in vestibule  
(**macula** – primary static organ)
- (3) **semicircular canals**  
(**crista ampullaris** in ampulla)

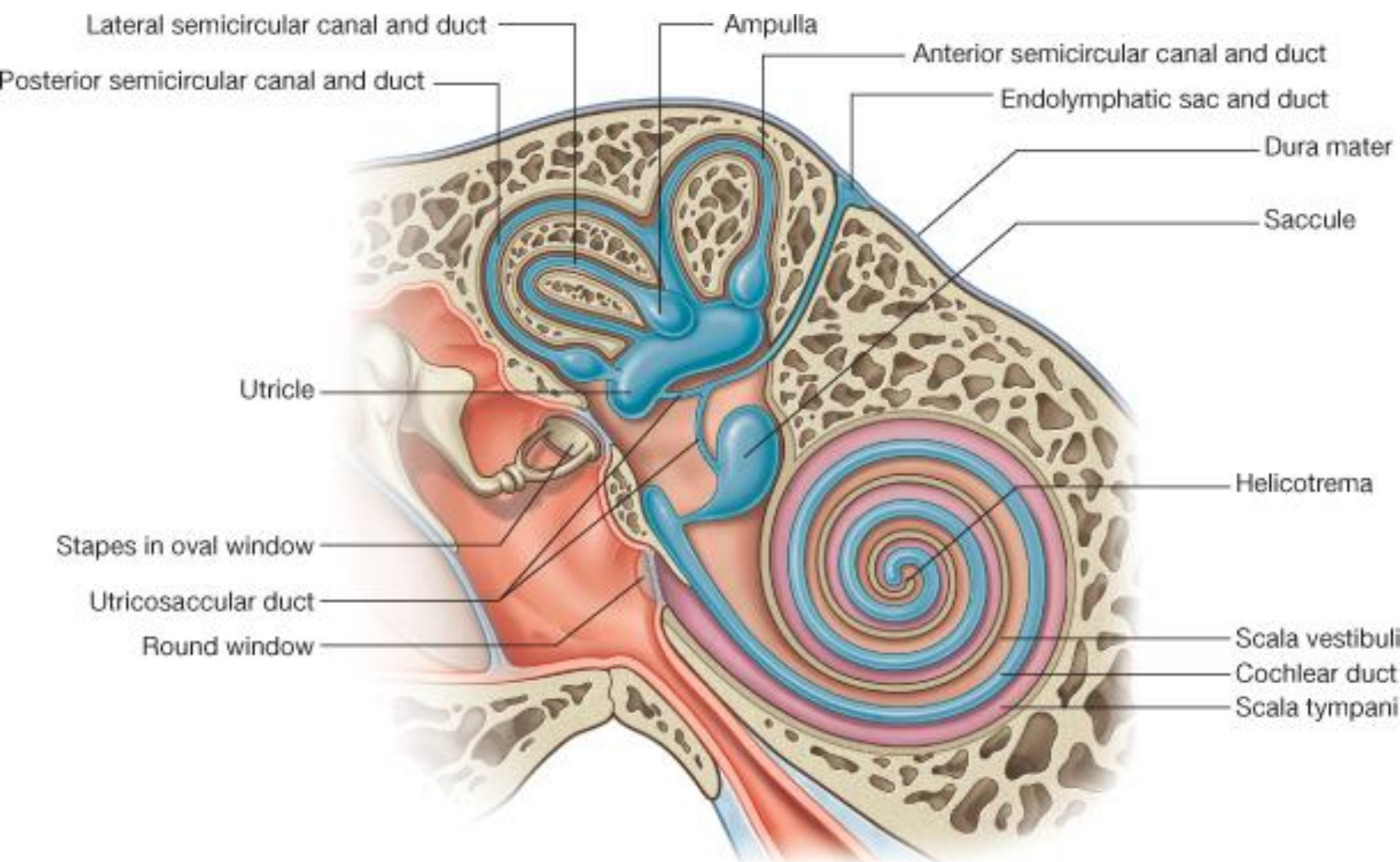
Ultrastructure of cochlear duct :

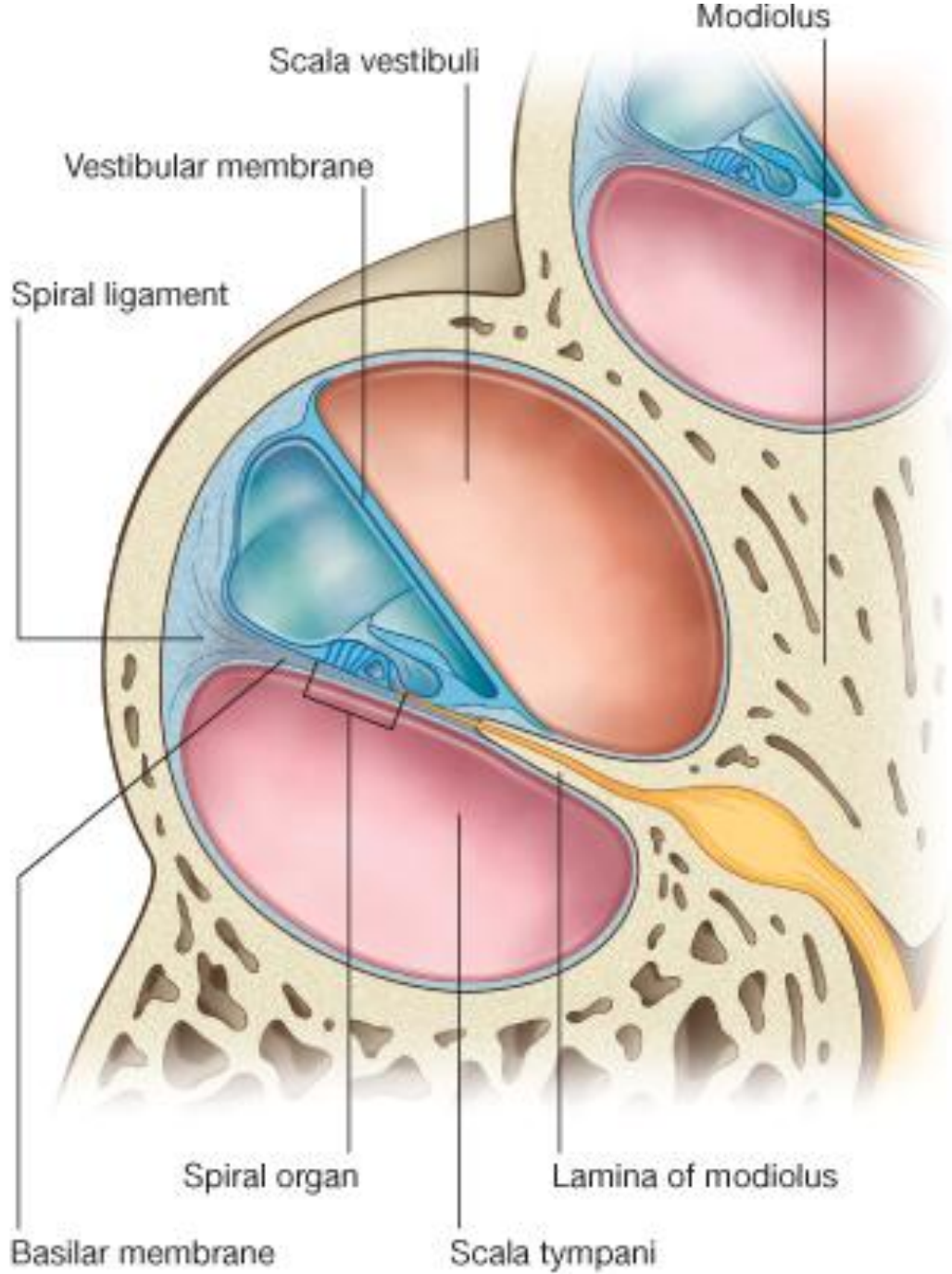
**vestibular membrane, basilar membrane**  
scala vestibuli, **cochlear duct**, scala tympani  
**spiral ganglion**,  
**organ of Corti** – **tectorial membrane**











# *Pathway for conduction of sound*

Sound waves collected by auricle

→ **tympanic membrane**

→ **auditory ossicles**

→ **perilymph** in oval window

→ **endolymph** in cochlear duct

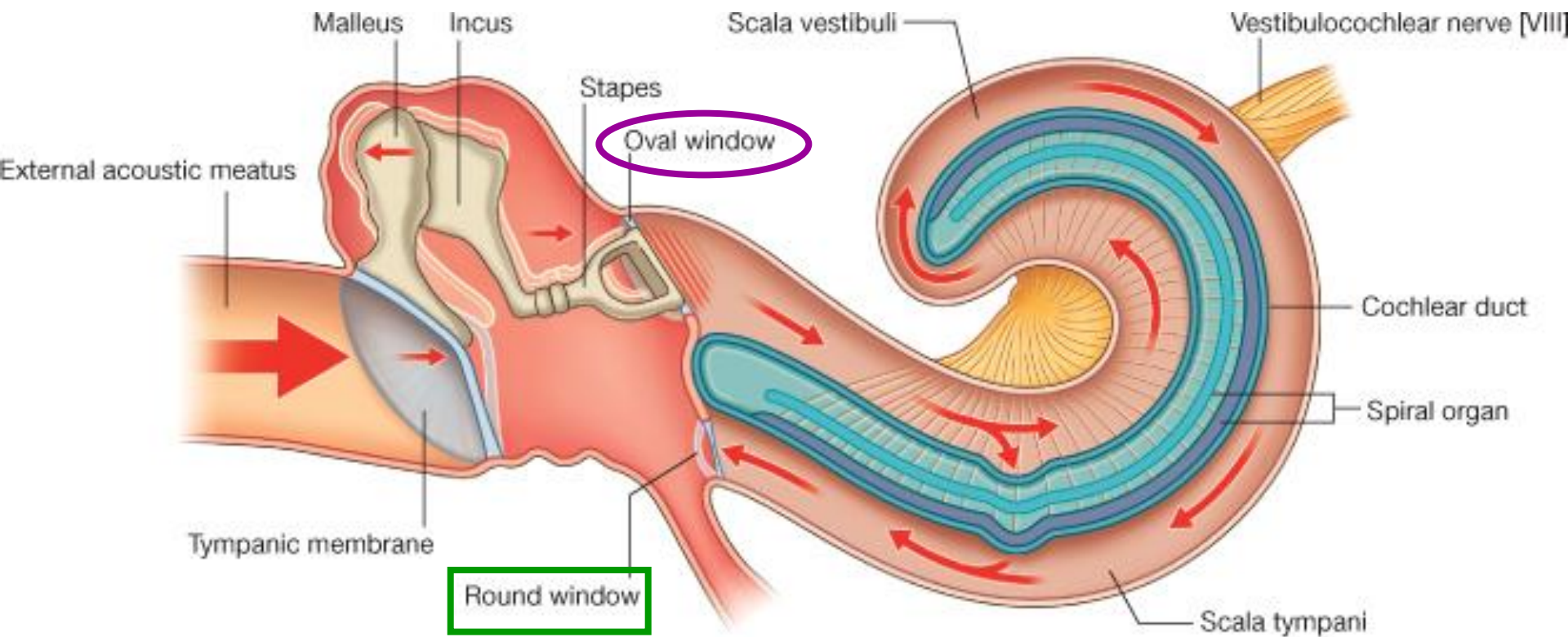
→ **tectorial membrane**

→ bending of hair cells

→ **spiral ganglion**

→ **cochlear nerve**

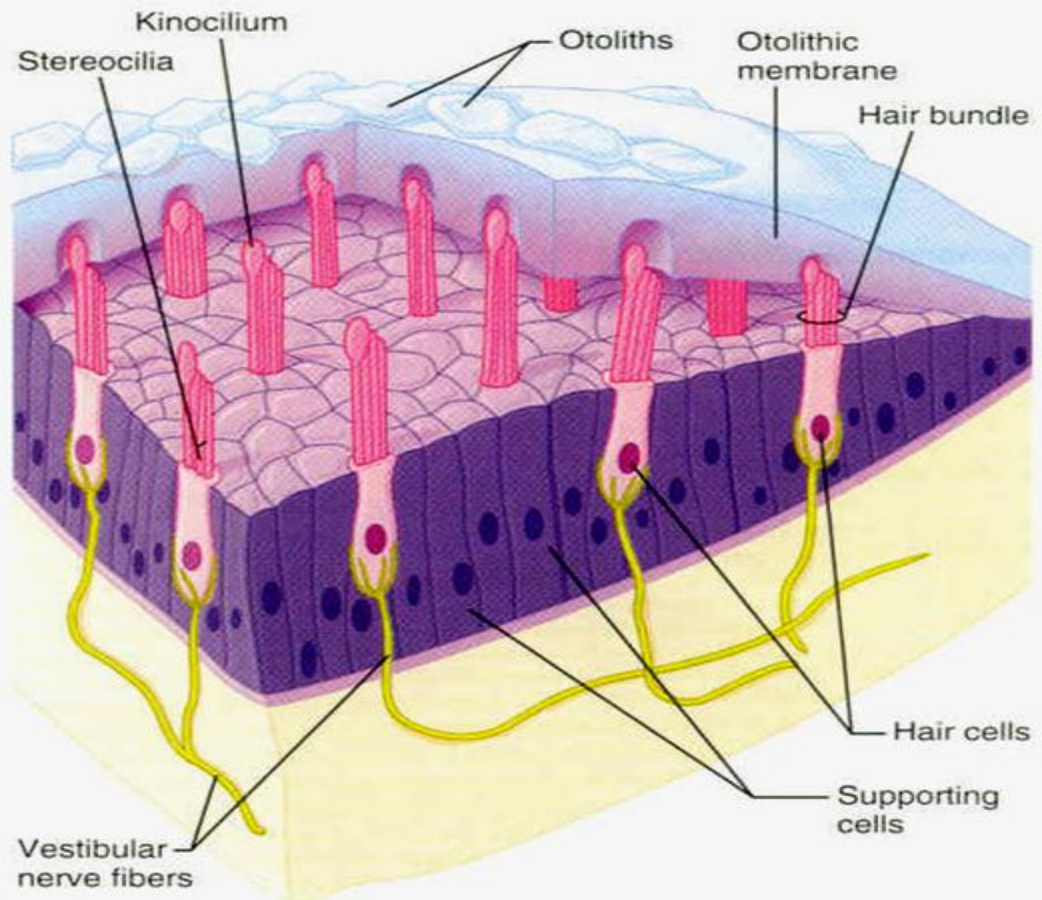
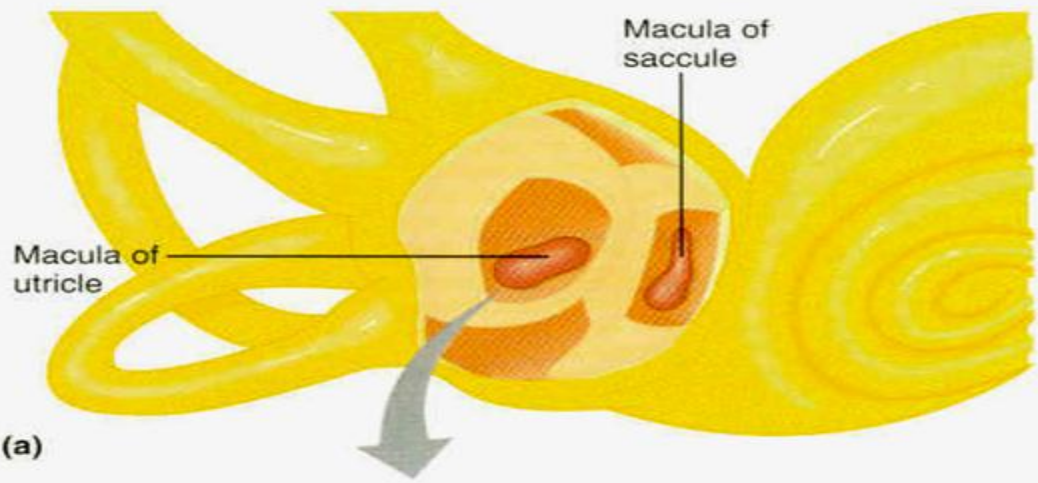
→ cochlear nuclei (in medulla oblongata)



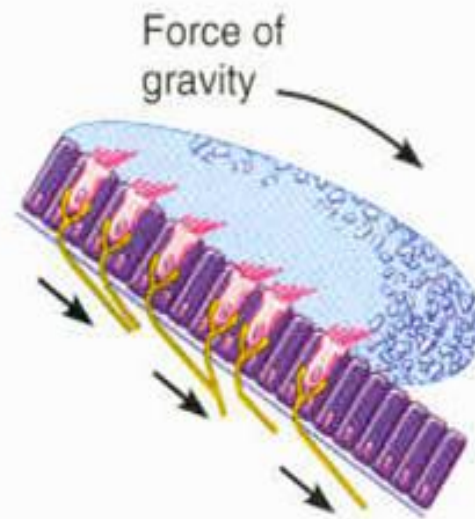
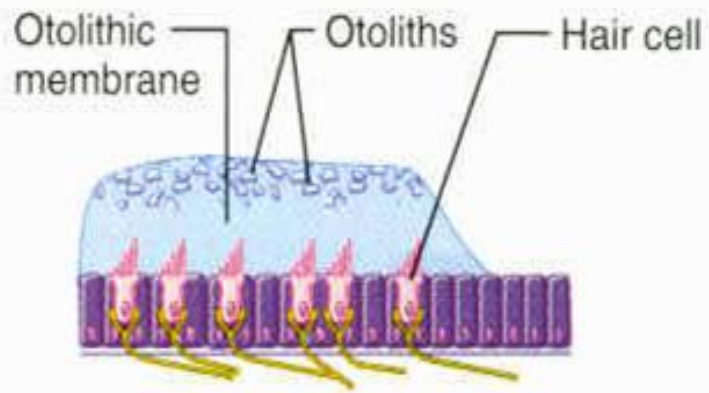
## *Pathway for balance*

Position of body

- **macula utriculi, macula sacculi & crista ampullaris**
- **vestibular ganglion**
- **vestibular nerve**
- vestibular nuclei (in medulla oblongata)







Head upright

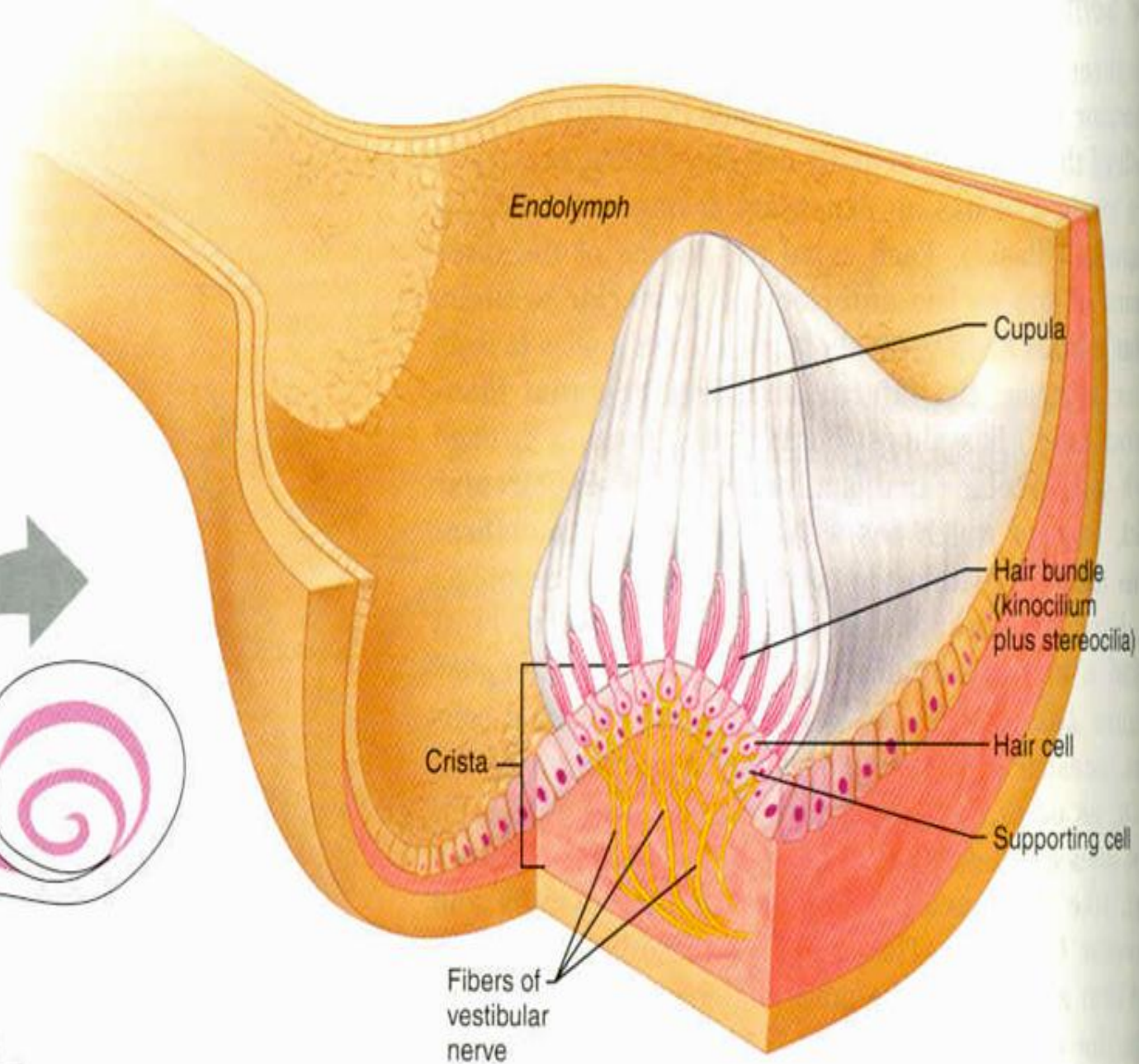



Head tilted

(c)

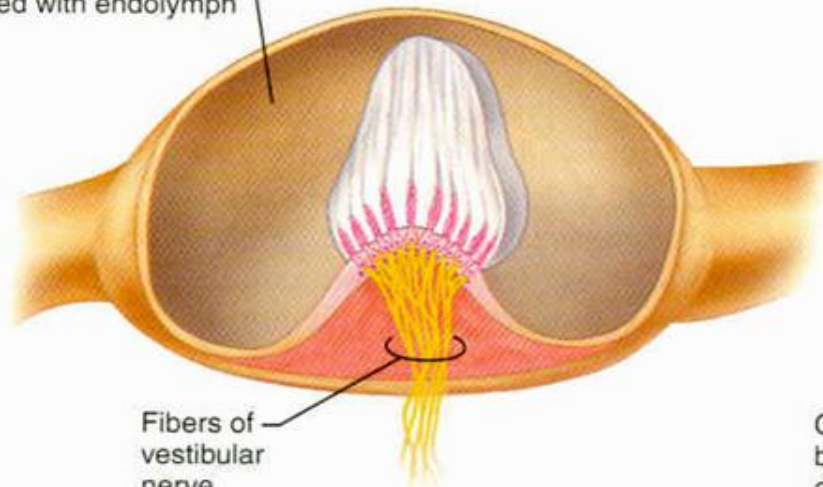
Crista  
ampullaris

Membranous labyrinth

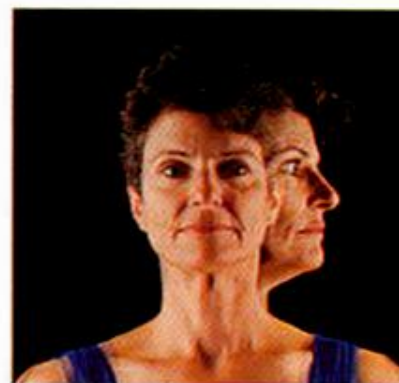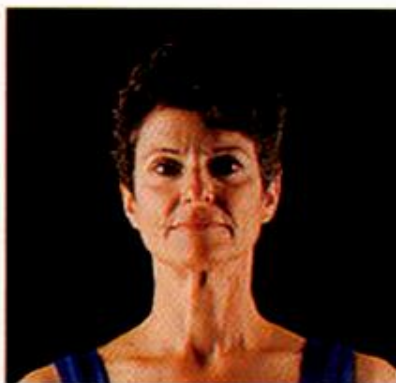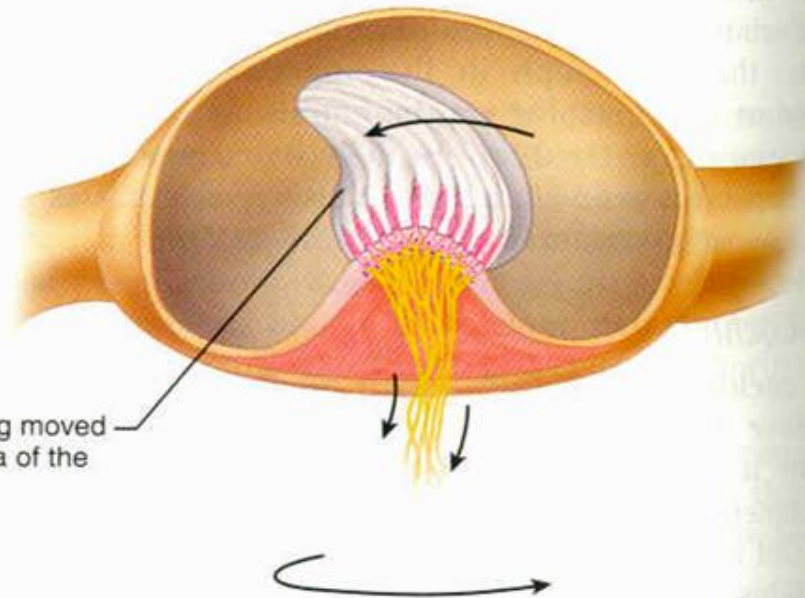


(a) Anatomy of a crista

Section of ampulla,  
filled with endolymph

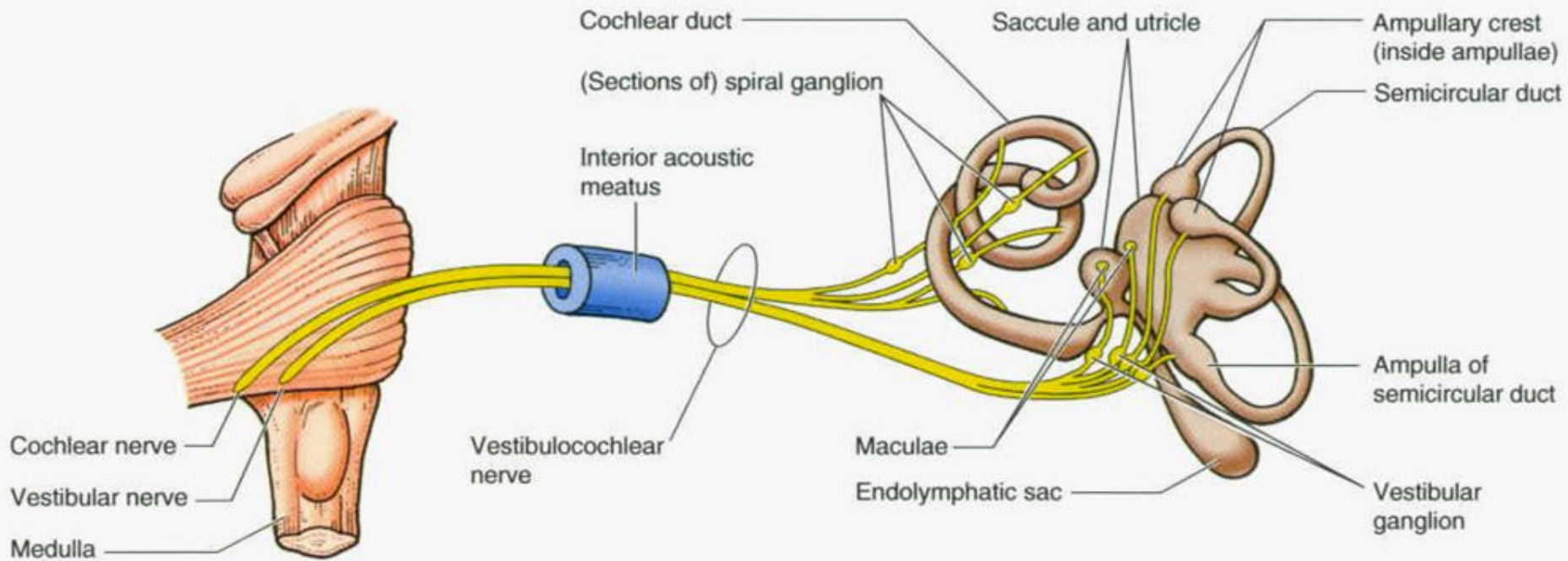


Cupula being moved  
by the inertia of the  
endolymph



### (b) Function of the crista

**FIGURE 16.22** Structure and function of the crista ampullaris in the inner ear. (a) Microscopic anatomy of the crista and cupula in the lateral semicircular duct, which has been cut in half. (b) Function of the crista: During rotational acceleration of the head, the endolymph in the semicircular duct lags, bending the cupula away from the direction of head movement and stimulating the hair cells.

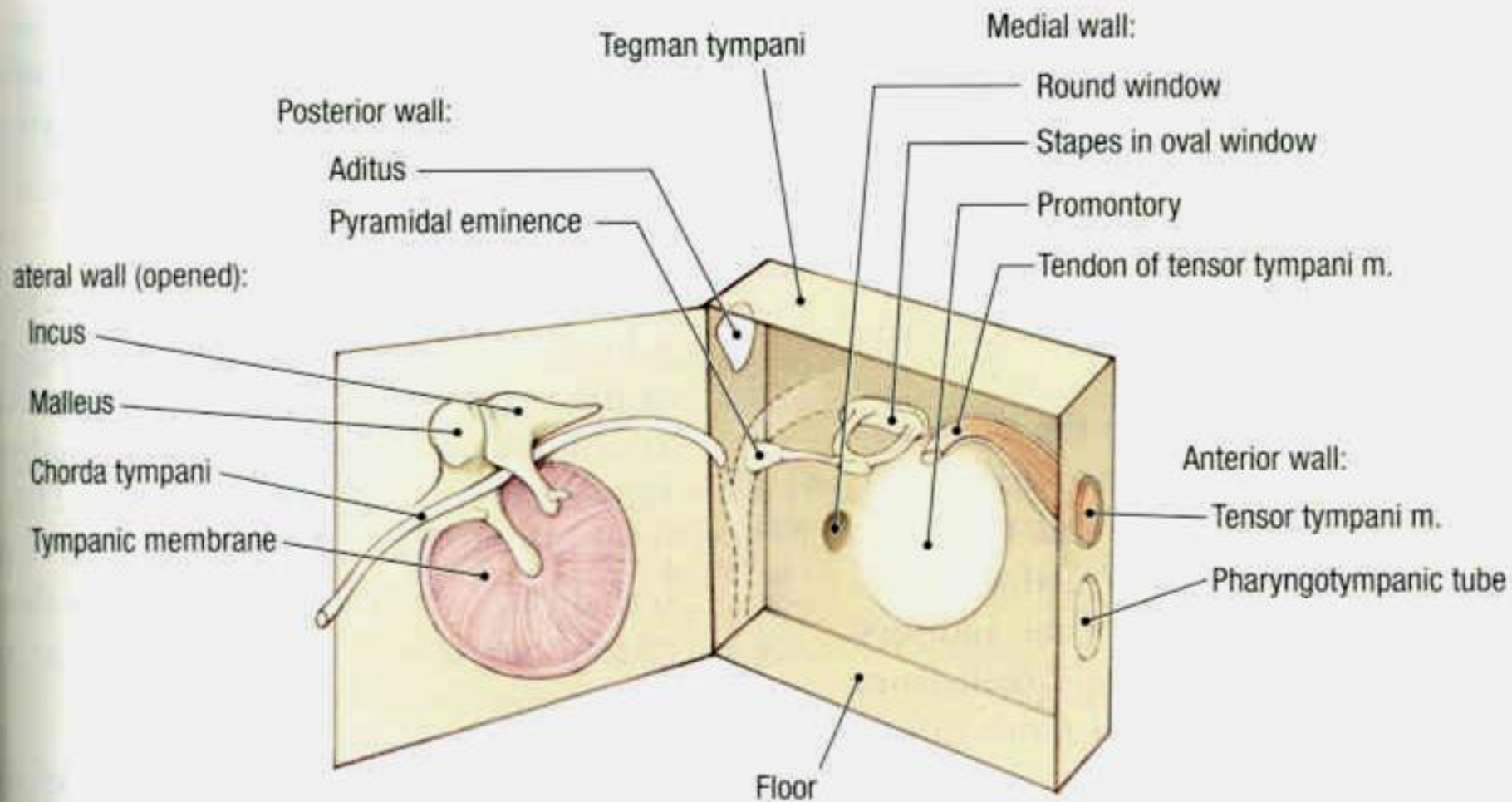


**Figure 7.82. The vestibulocochlear nerve (CN VIII).** Note that it has two parts: the cochlear nerve, or the nerve of hearing, and the vestibular nerve, or the nerve of balance. The cell bodies of the sensory fibers (only) that comprise the two parts of this nerve constitute the spiral and vestibular ganglia.

# Dissection of Middle Ear

## Middle Ear

1. Carefully remove tegmen tympani, examine **facial nerve**, **geniculate ganglion**, **greater petrosal nerve**, chorda tympani, **vestibulo-cochlear nerve**.
2. Identify **malleus**, **incus** (easy detached), **stapes** and **semicircular canals**.



**Figure 7.94.** Schematic drawing of the walls of the tympanic cavity. Right ear in lateral view with the lateral wall opened.

