

Bisection of Head & Nasal Cavity

頭部對切 以及 鼻腔

解剖學科 馮琮涵 副教授

分機 3250

E-mail: thfong@tmu.edu.tw

Outline:

- The structure of nose
- The concha and meatus in nasal cavity
- The openings of paranasal sinuses

- Canals, foramens and fissures in pterygopalatine fossa
- Contents in pterygopalatine fossa

The Nose

The functions of the nose:

**olfaction, respiration, filtration,
humidification & reception of secretions**

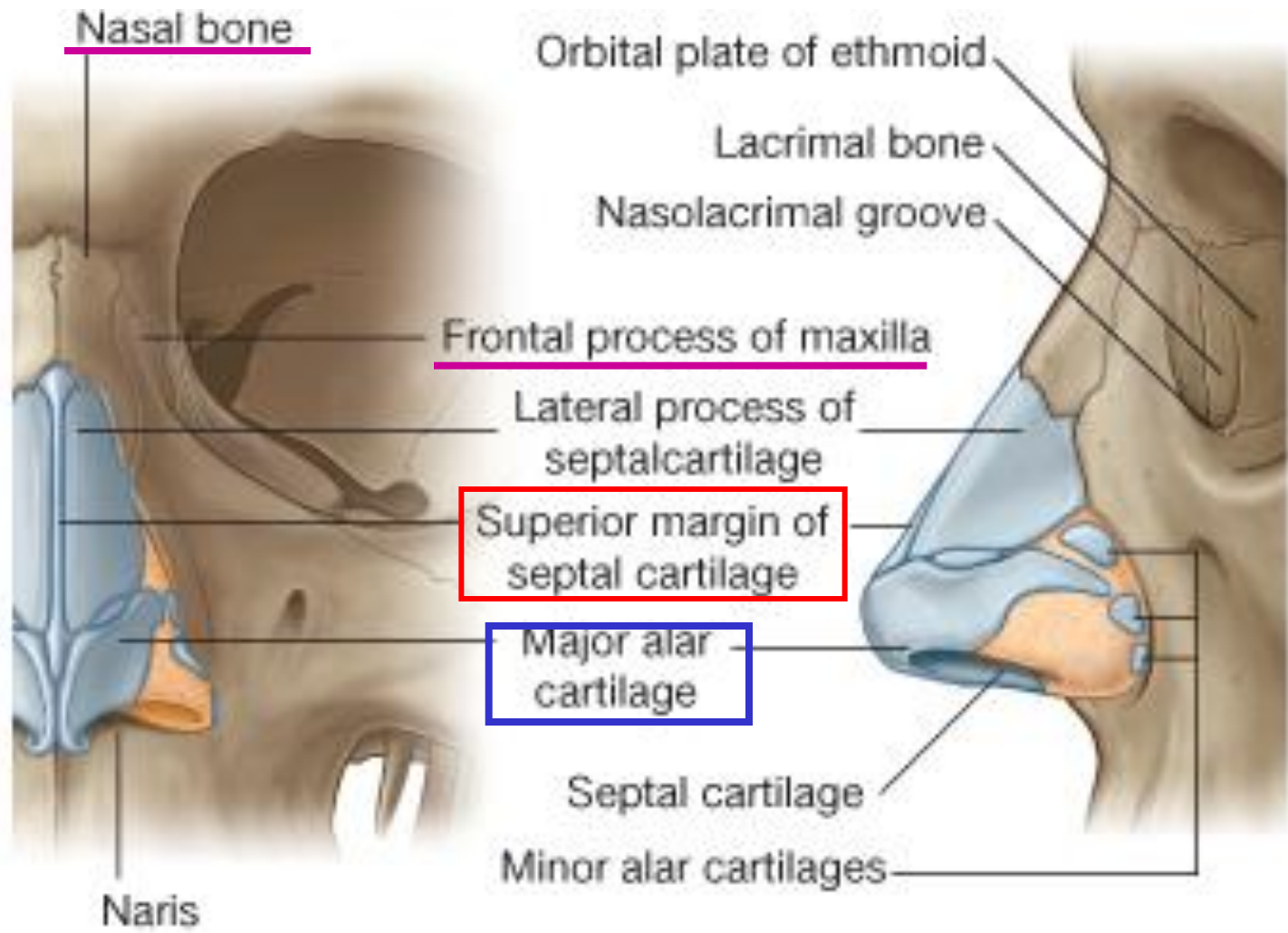
The external nose

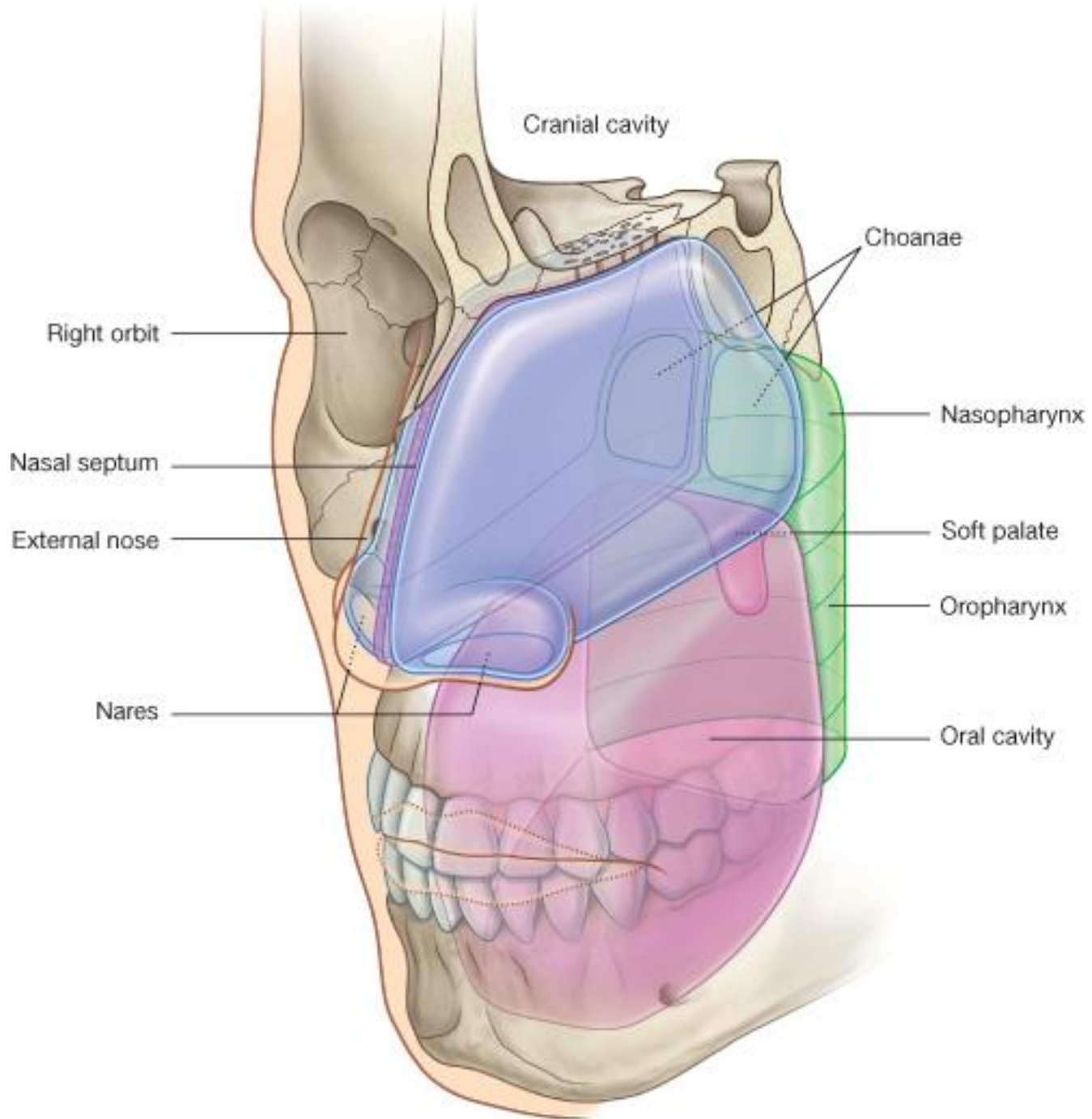
Root, apex, nasal septum & vestibule, naris

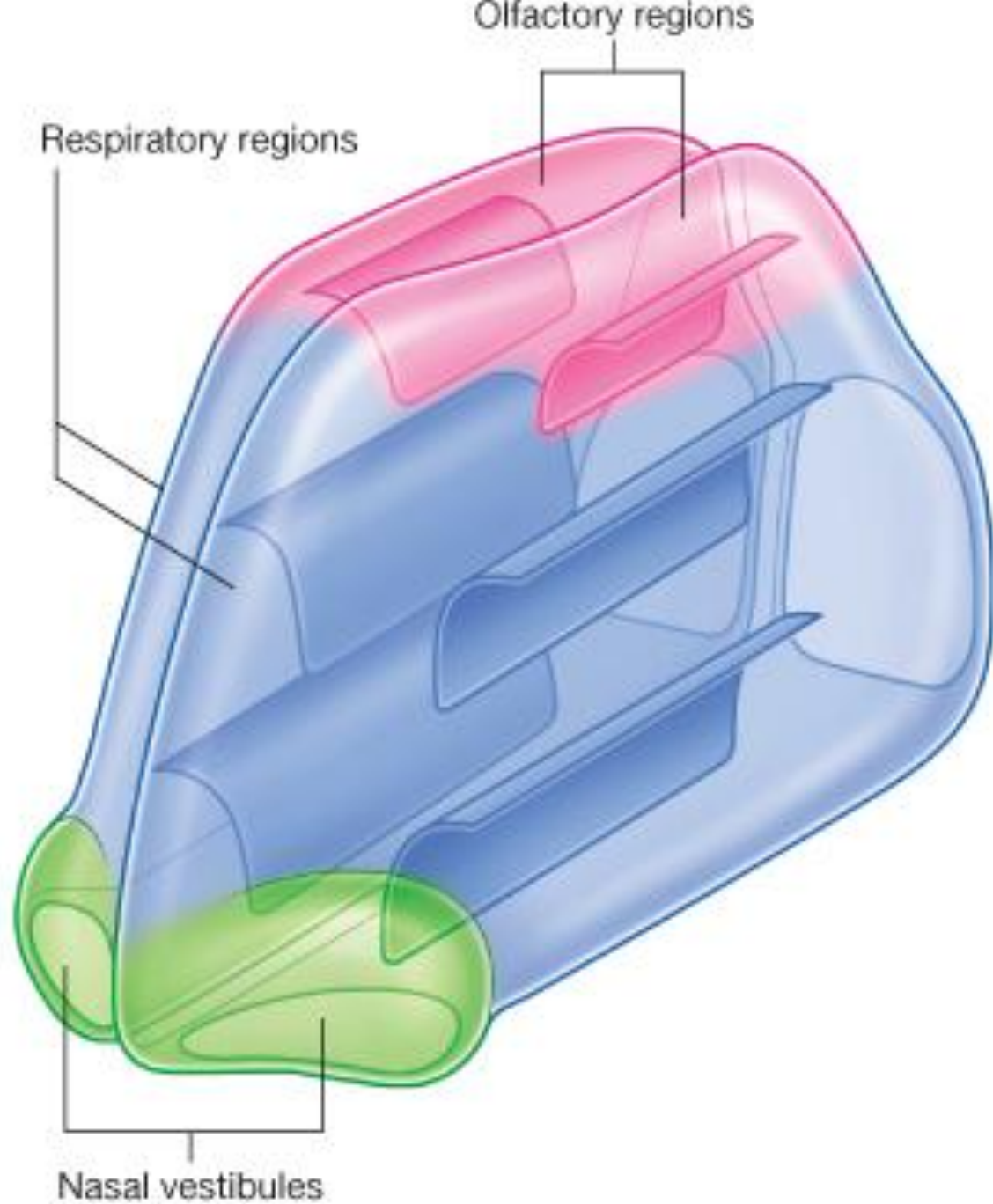
Structure of nasal septum – *slight to the right*

Three components :

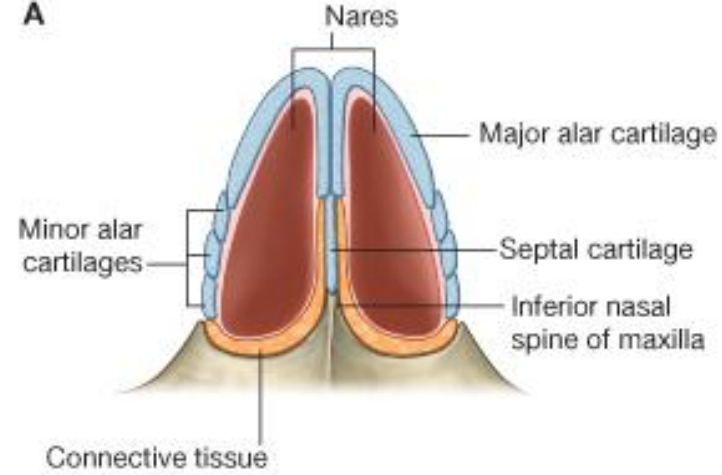
- (1) **perpendicular plate of ethmoid bone**
- (2) **vomer**
- (3) **septal cartilage**



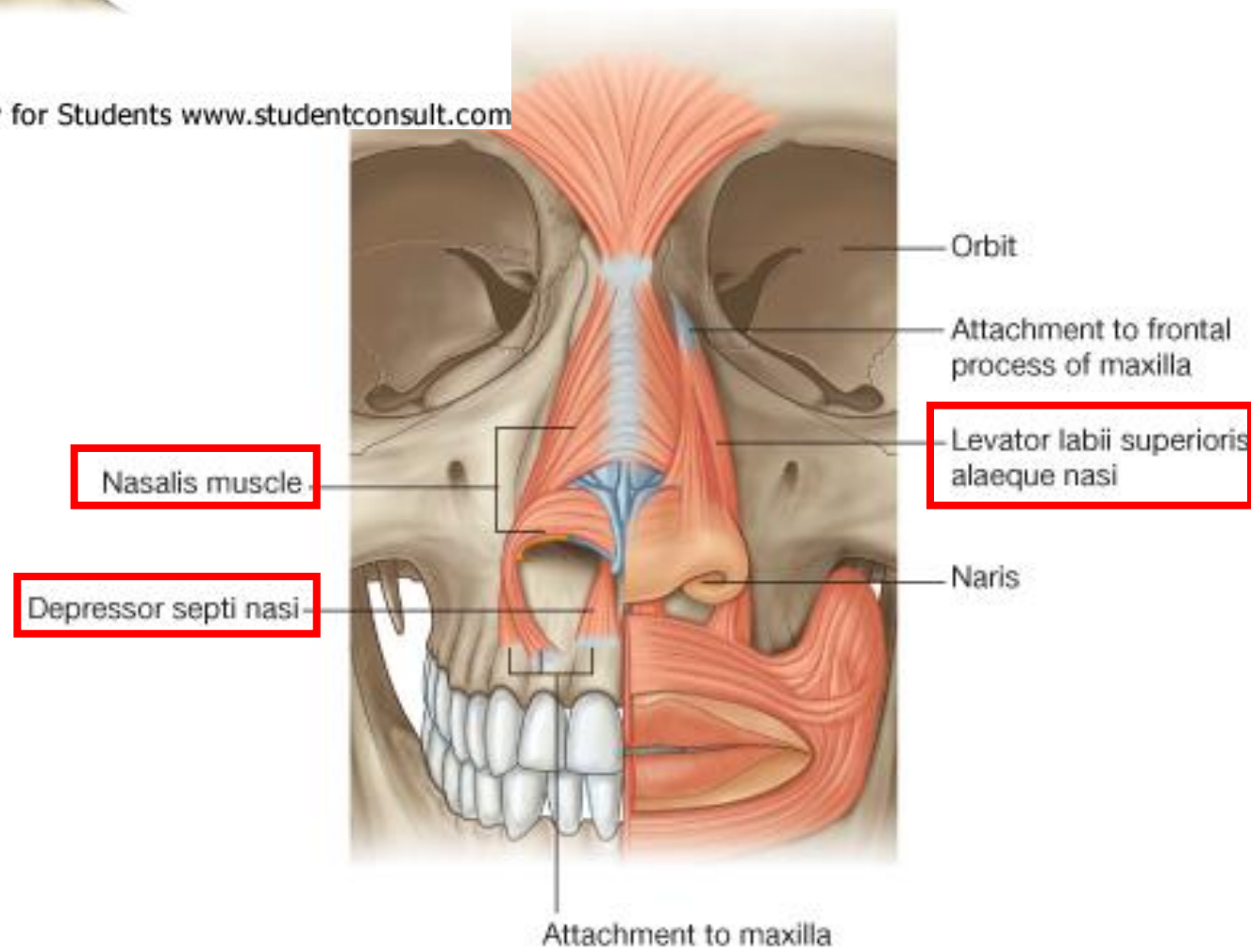




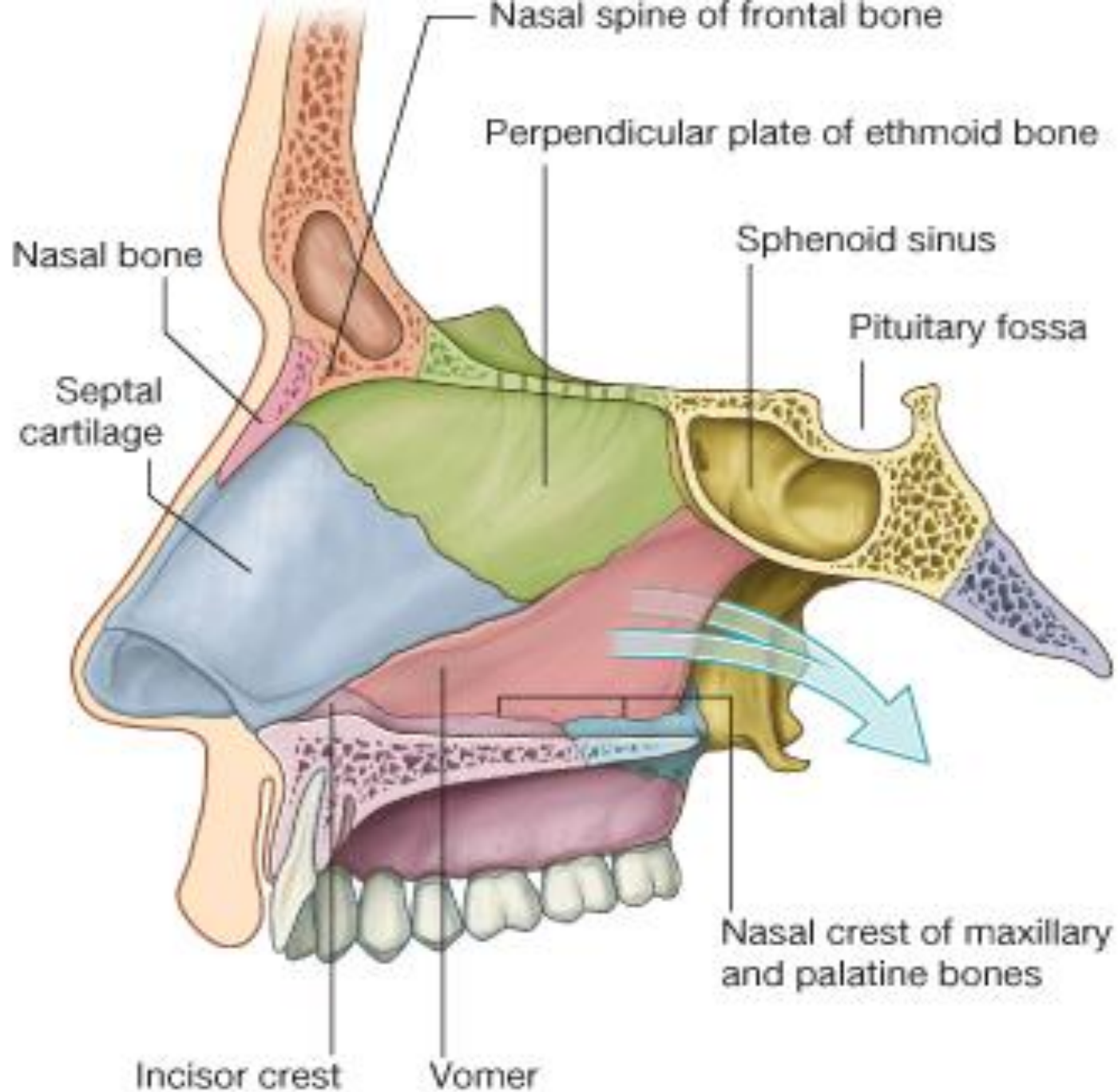
A



© Elsevier Ltd. Drake et al: Gray's Anatomy for Students www.studentconsult.com



© Elsevier Ltd. Drake et al: Gray's Anatomy for Students www.studentconsult.com



Nasal cavities

Roof – frontonasal, ethmoidal and sphenoidal parts

Floor – **palatine process of the maxilla** +
horizontal plate of the palatine bone

Medial wall – nasal septum

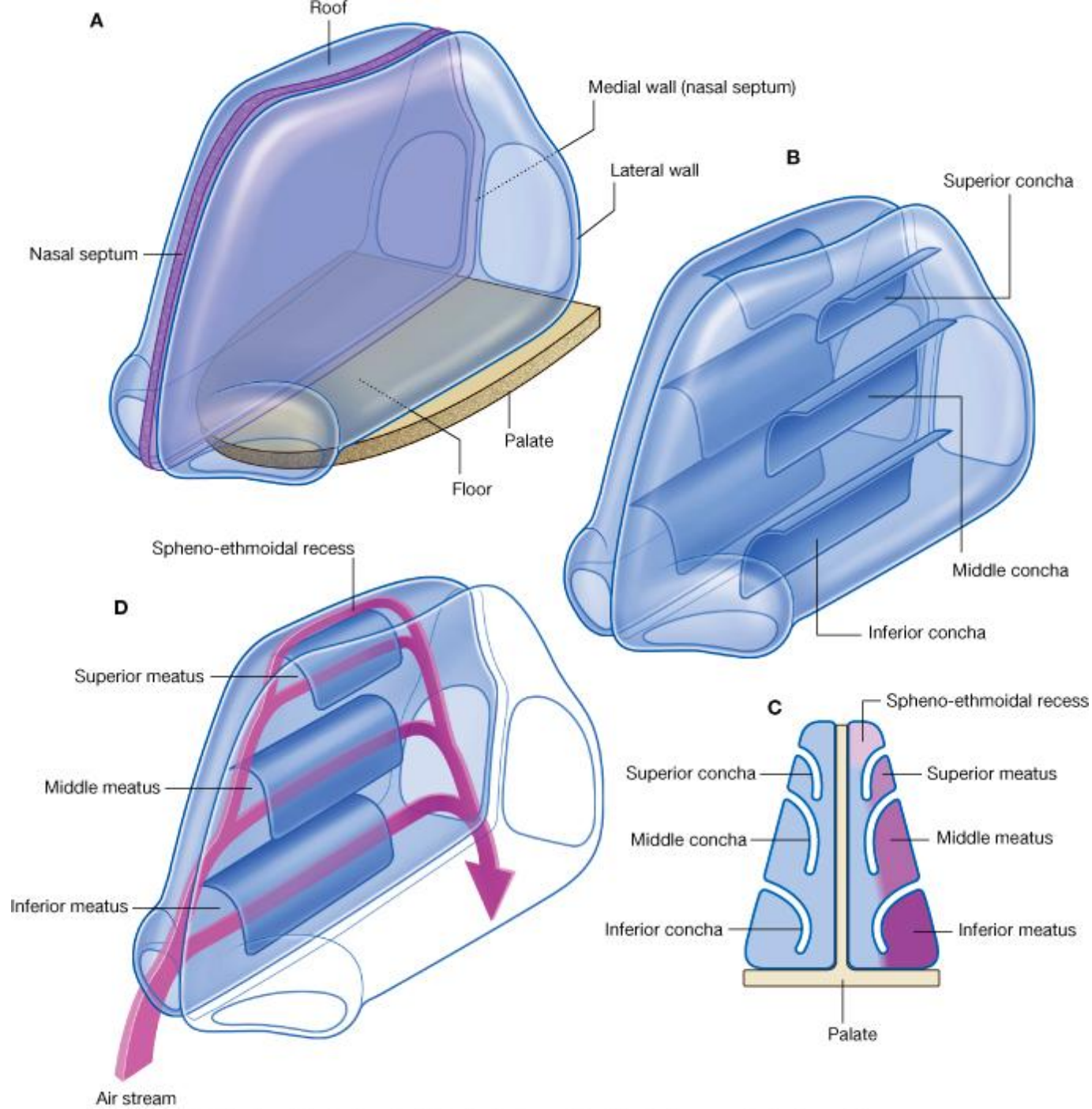
Lateral wall – nasal conchae and meatus

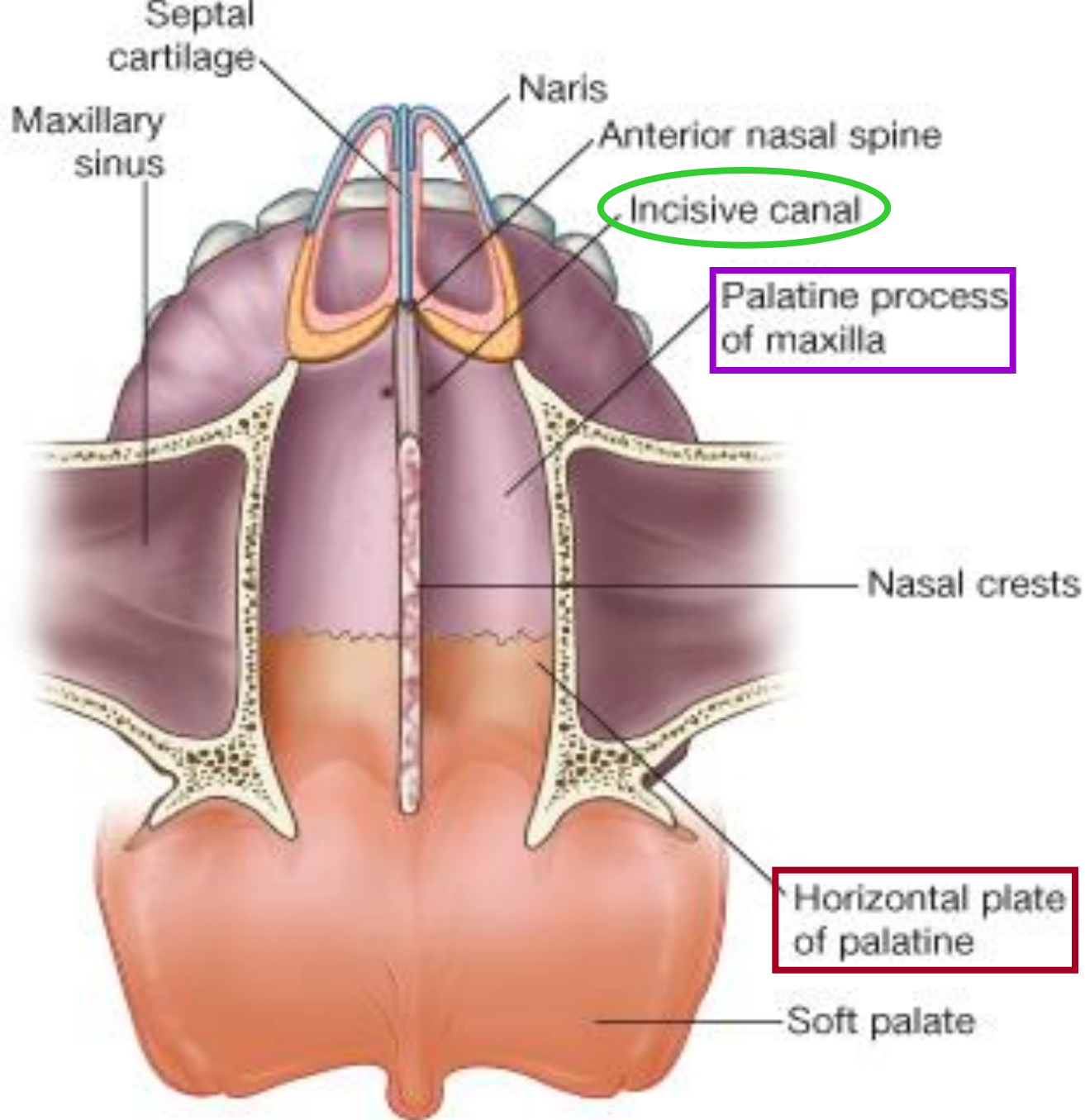
spheno-ethmoidal recess,

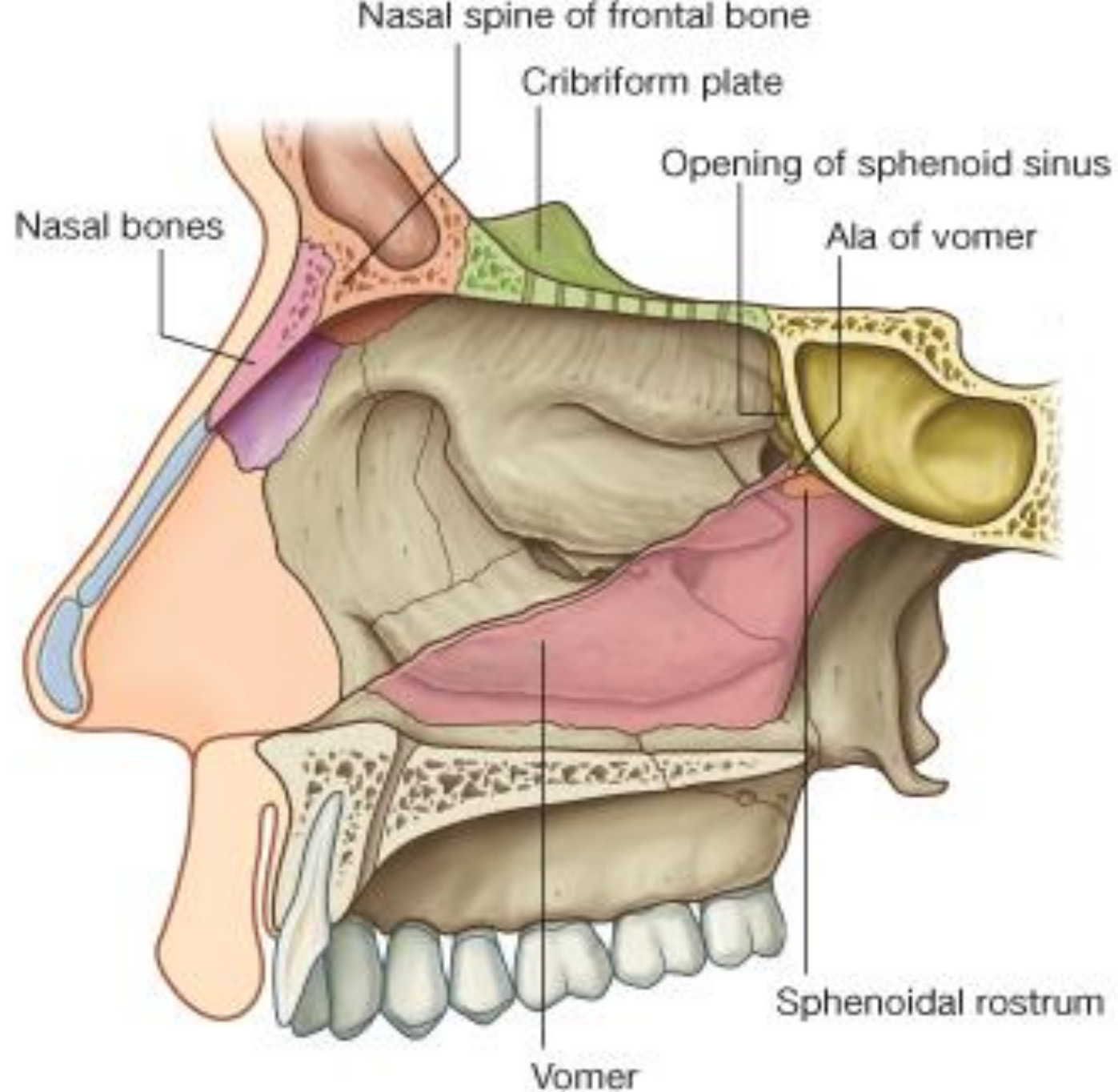
superior meatus,

middle meatus – **semilunar hiatus (ethmoidal bulla)**

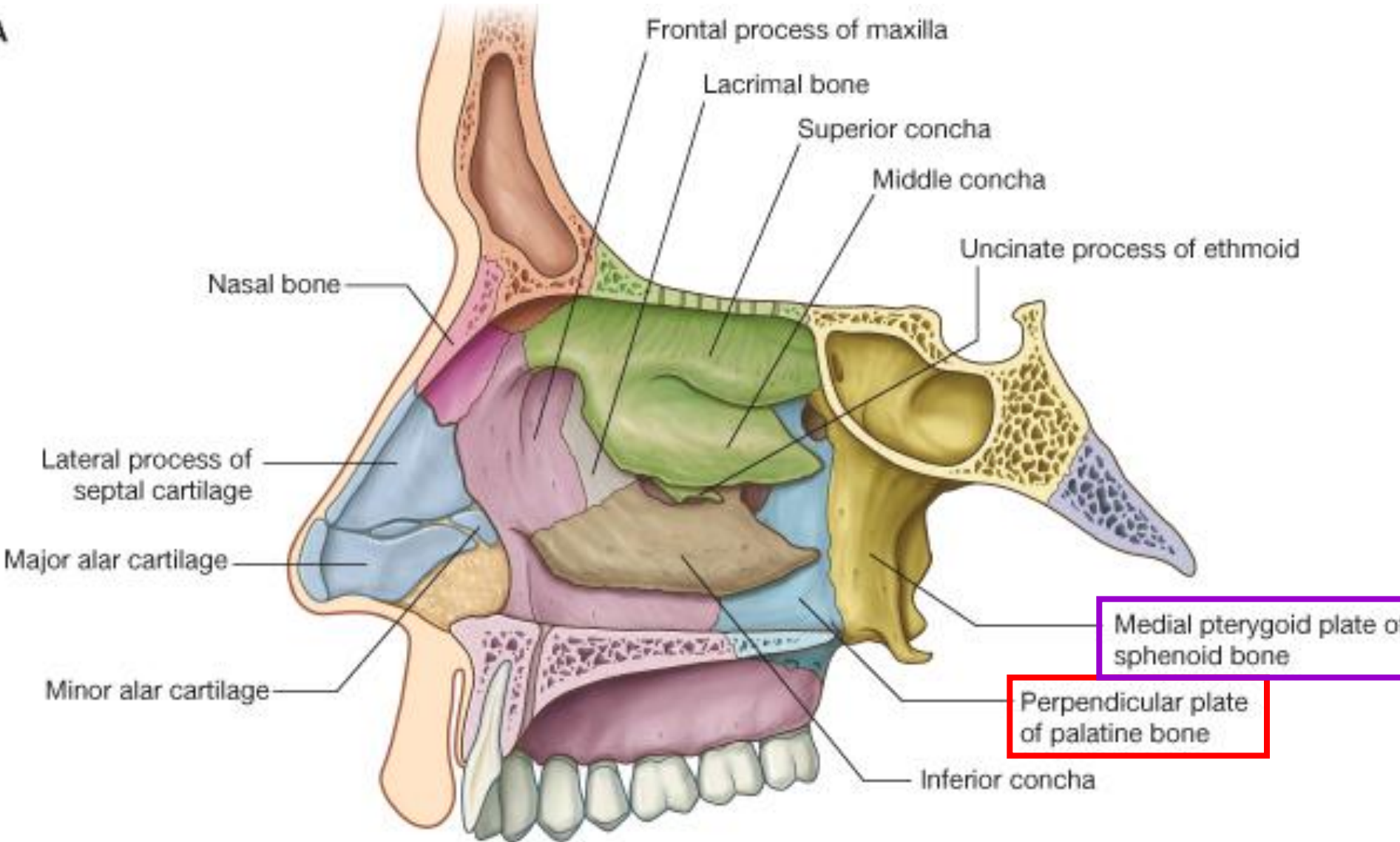
inferior meatus – **nasolacrimal duct**



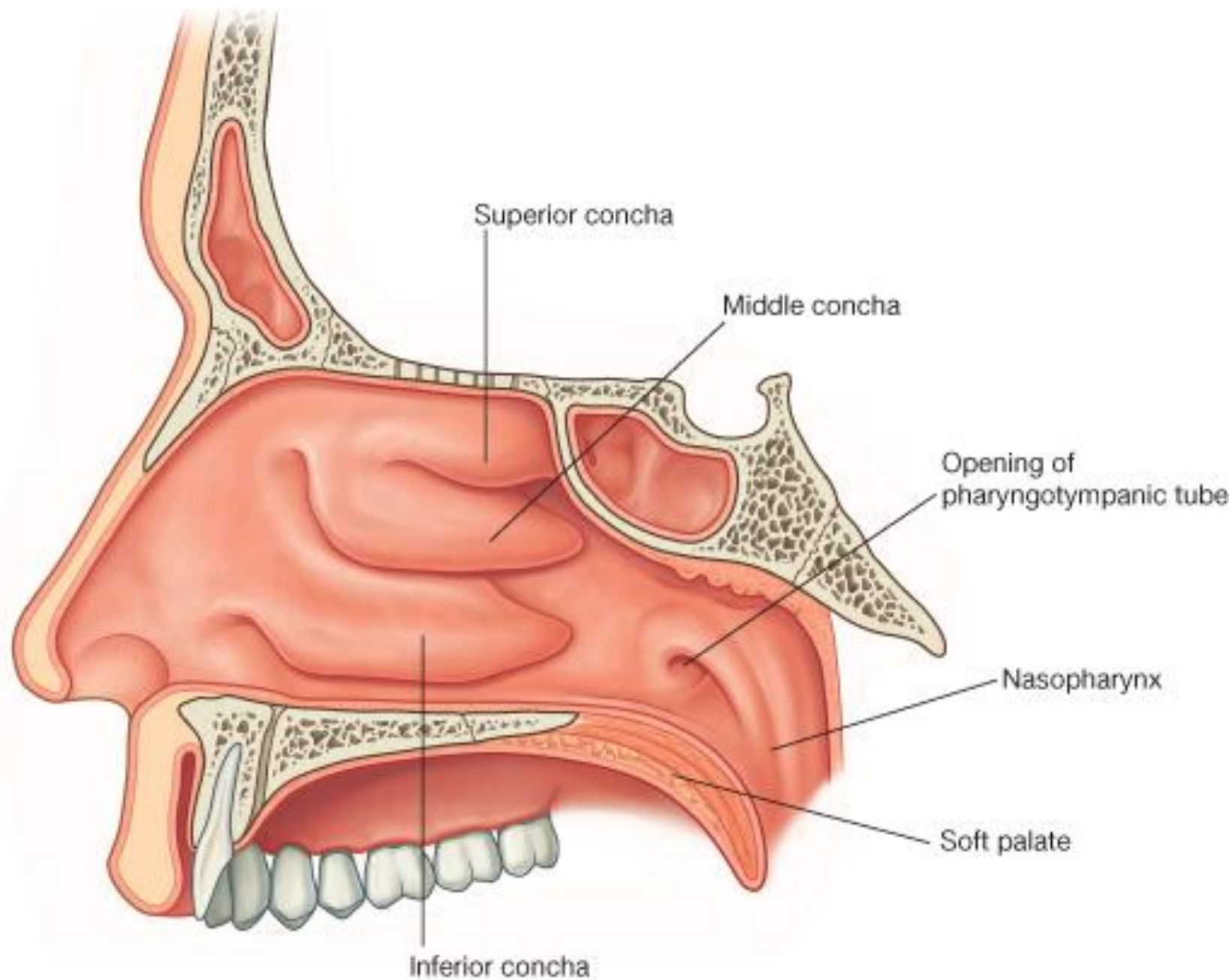


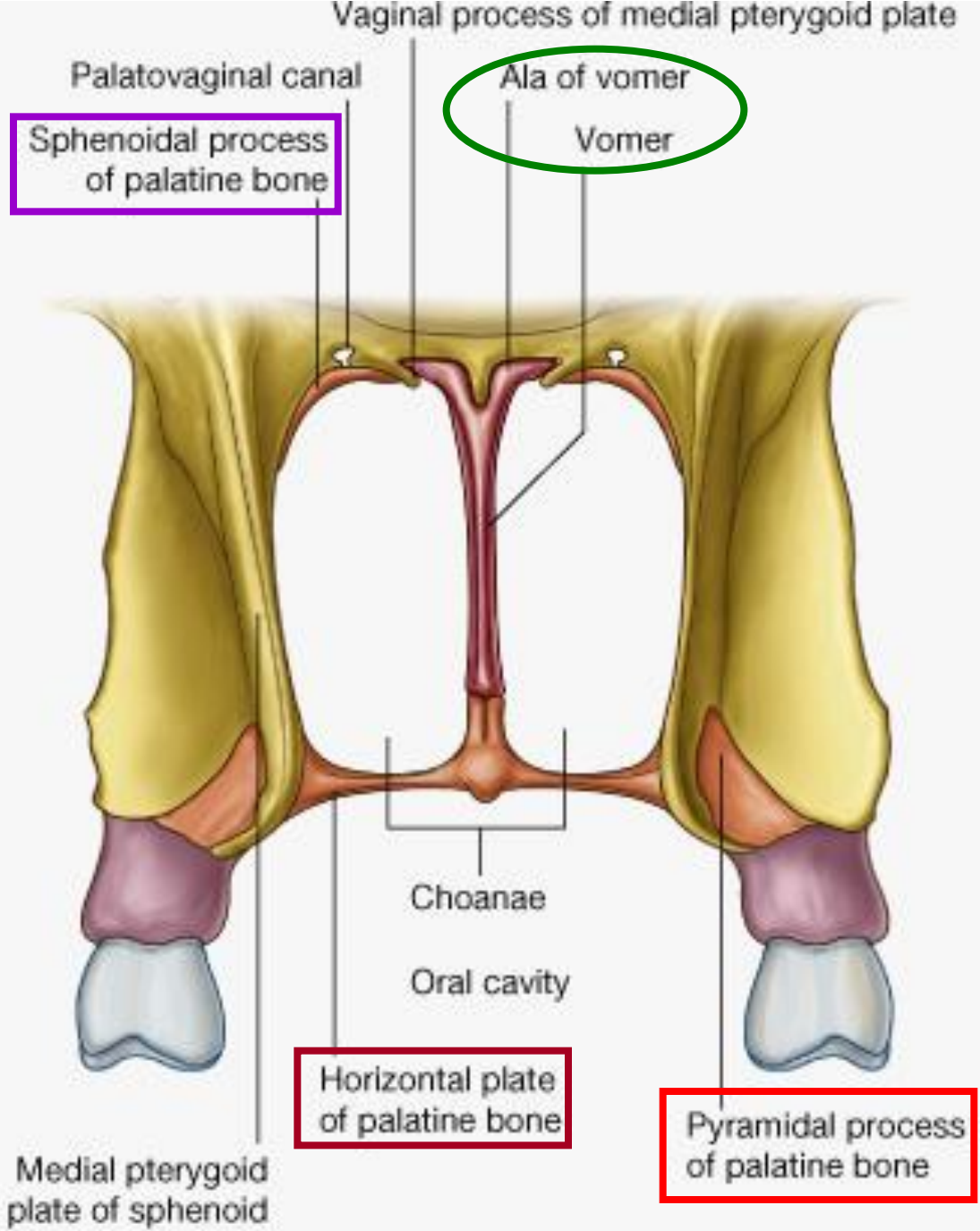


A



B





Paranasal sinuses

frontal sinus → **semilunar hiatus** of **mid. meatus**
innervated by branches of supraorbital nerves

ethmoid sinus

anterior & **middle** ethmoidal cells

→ **semilunar hiatus** of **middle meatus**

posterior ethmoidal cells → **superior meatus**

innervation: ant. & post. ethmoidal br. of nasociliary nerve

blood supply: ant. & pos. ethmoidal br. of ophthalmic a.

Paranasal sinuses

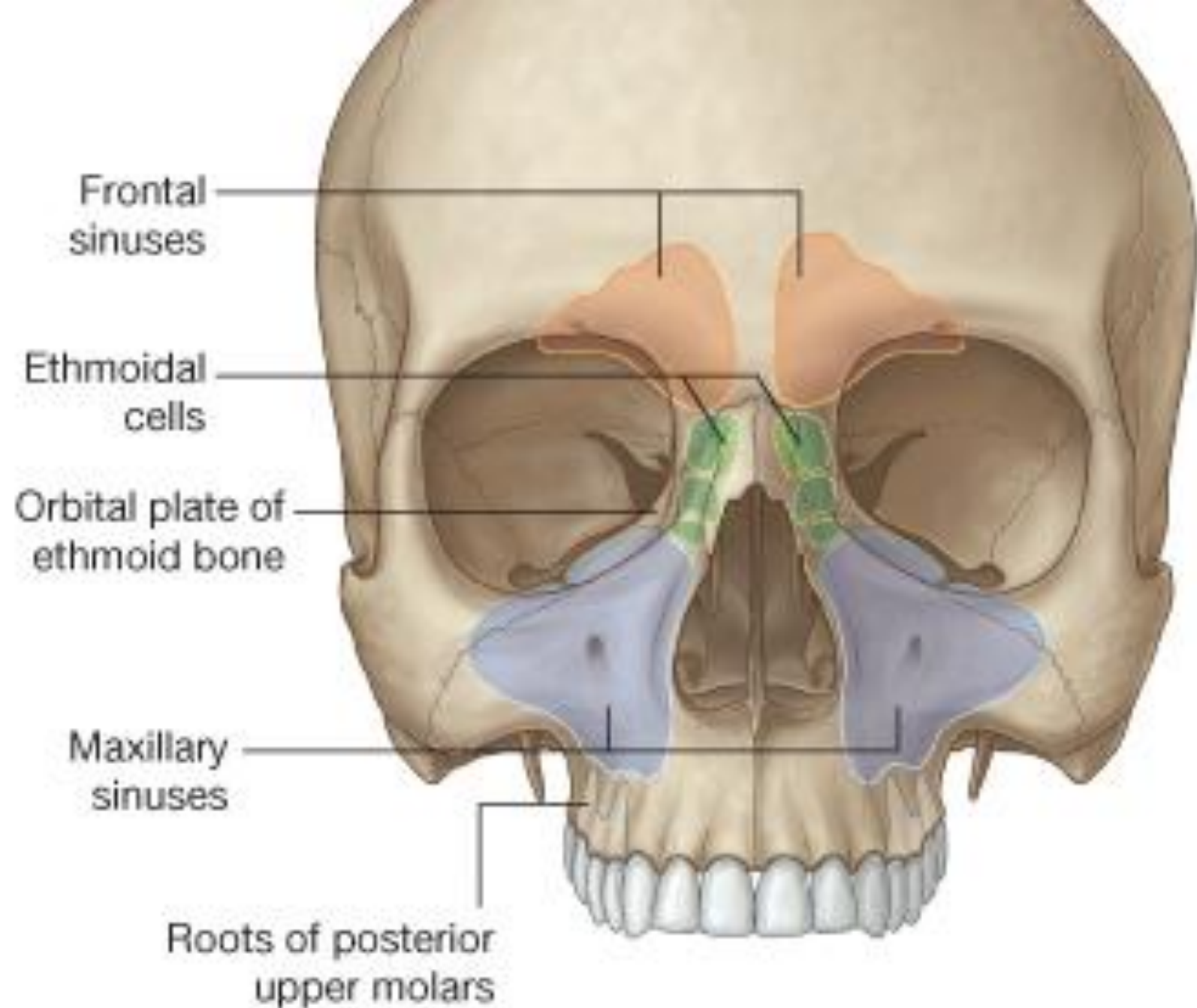
sphenoidal sinus → **spheno-ethmoidal recess**

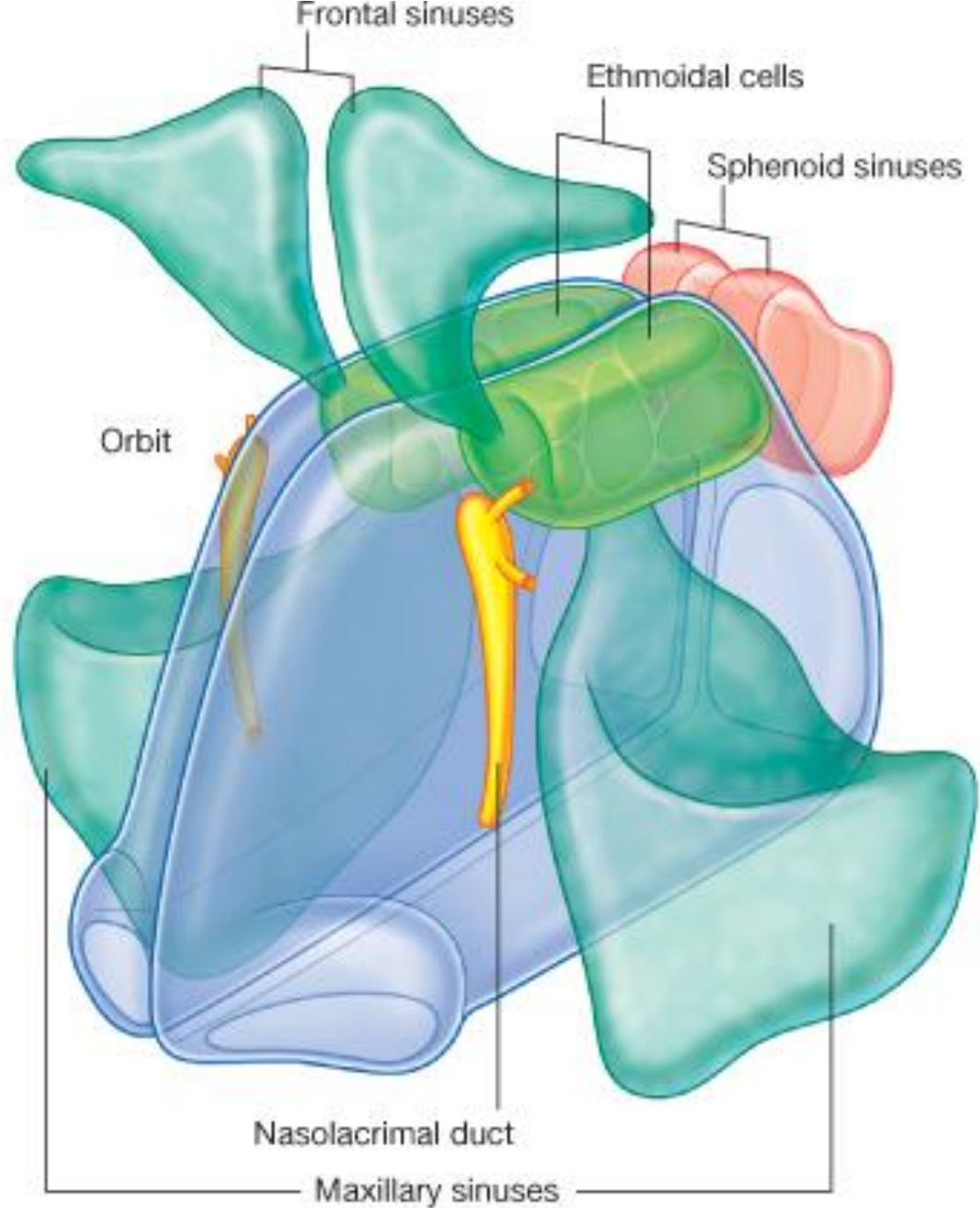
posterior ethmoidal nerve and artery

maxillary sinus → **semilunar hiatus** of
middle meatus

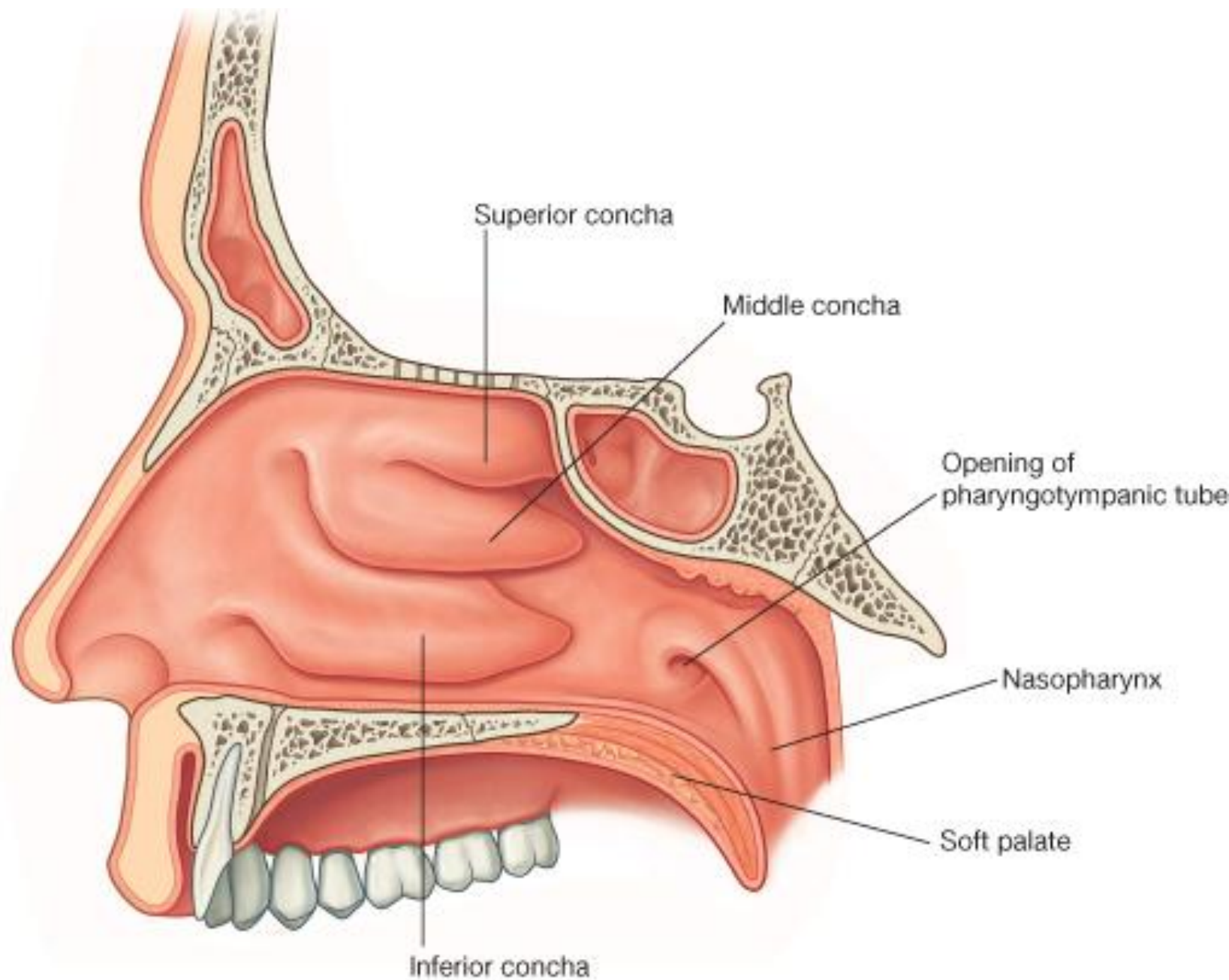
innervation: ant., mid., post. superior alveolar nerves

*blood supply: superior alveolar branches of
maxillary artery and greater palatine artery*

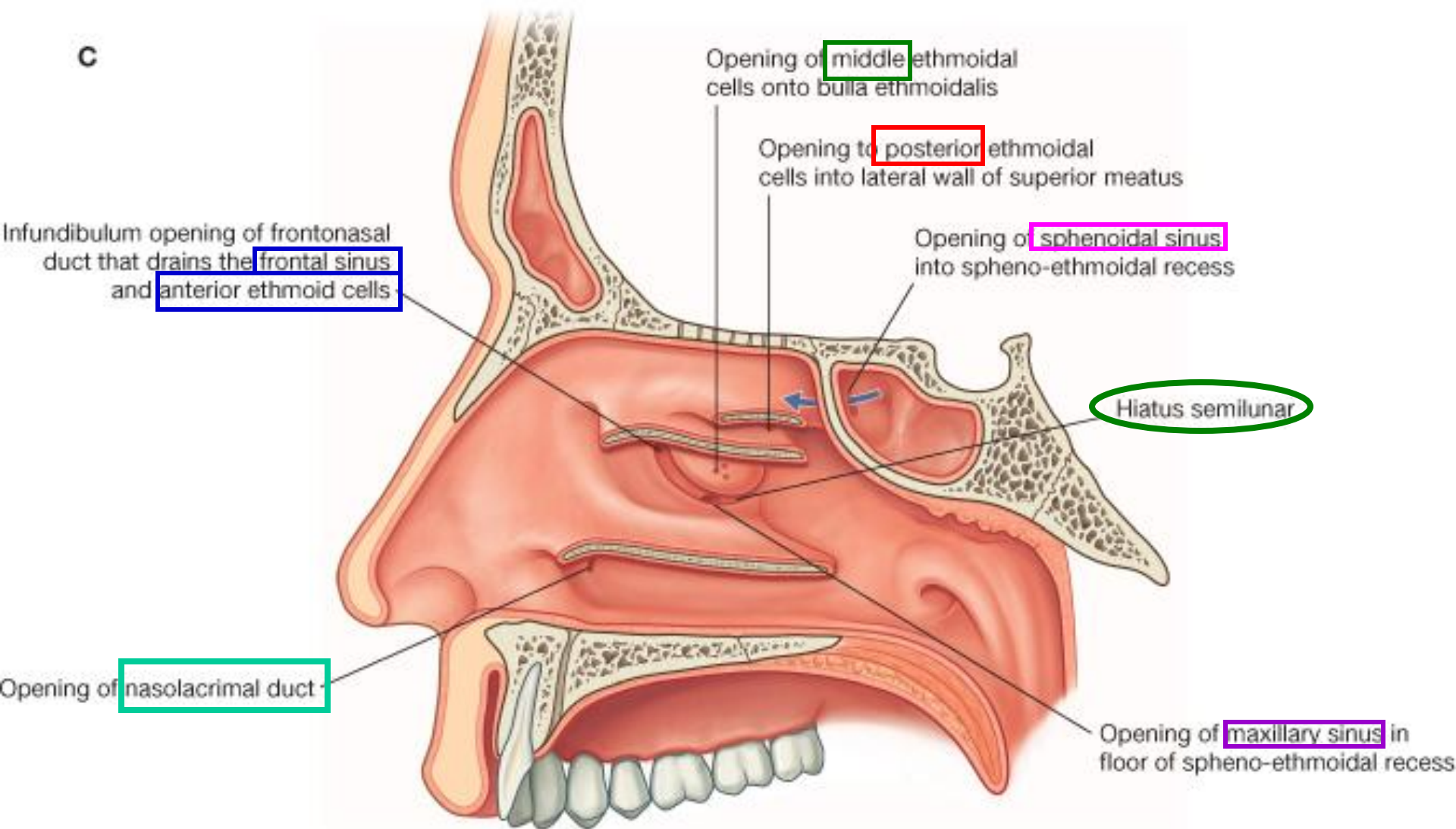




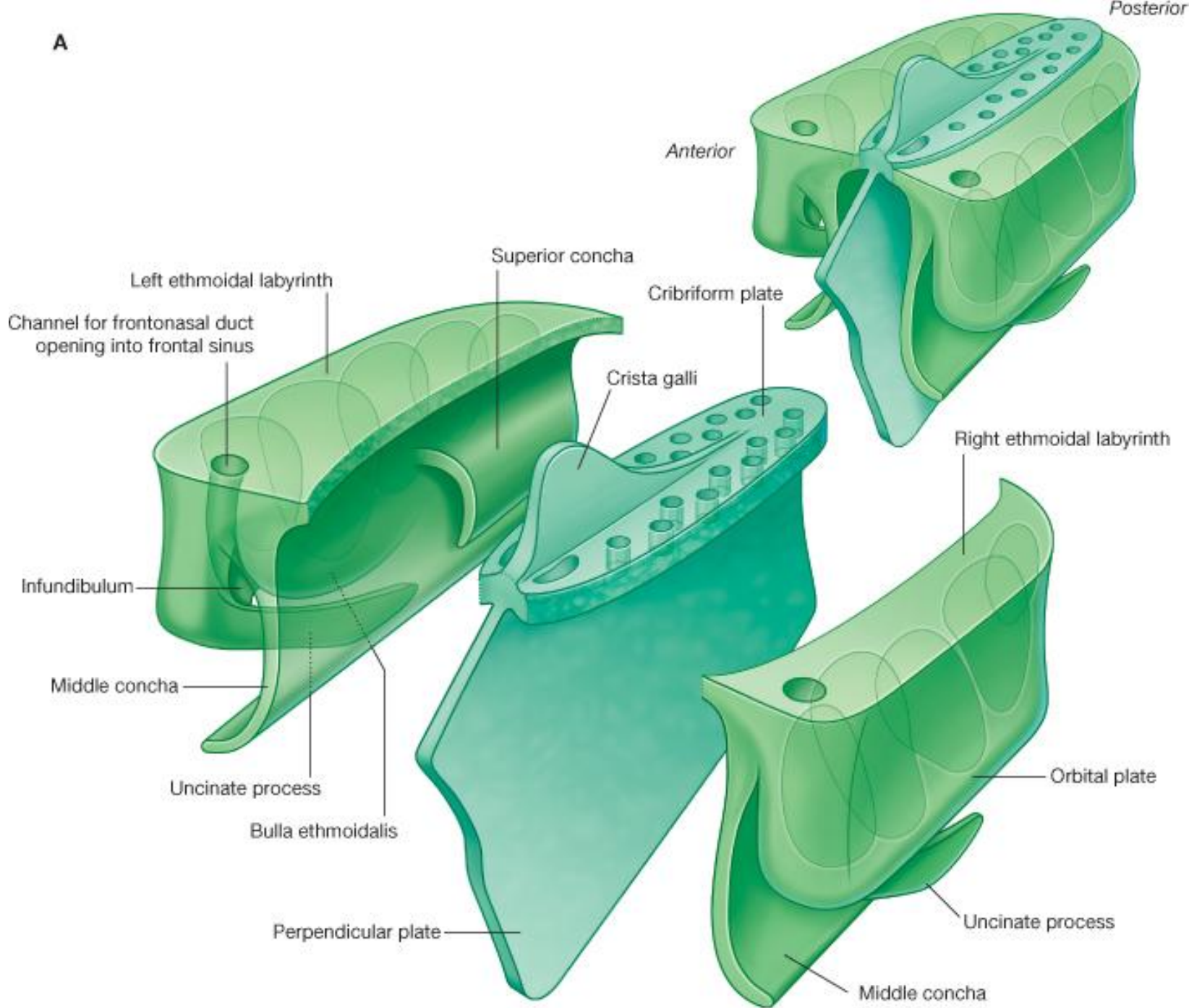
B

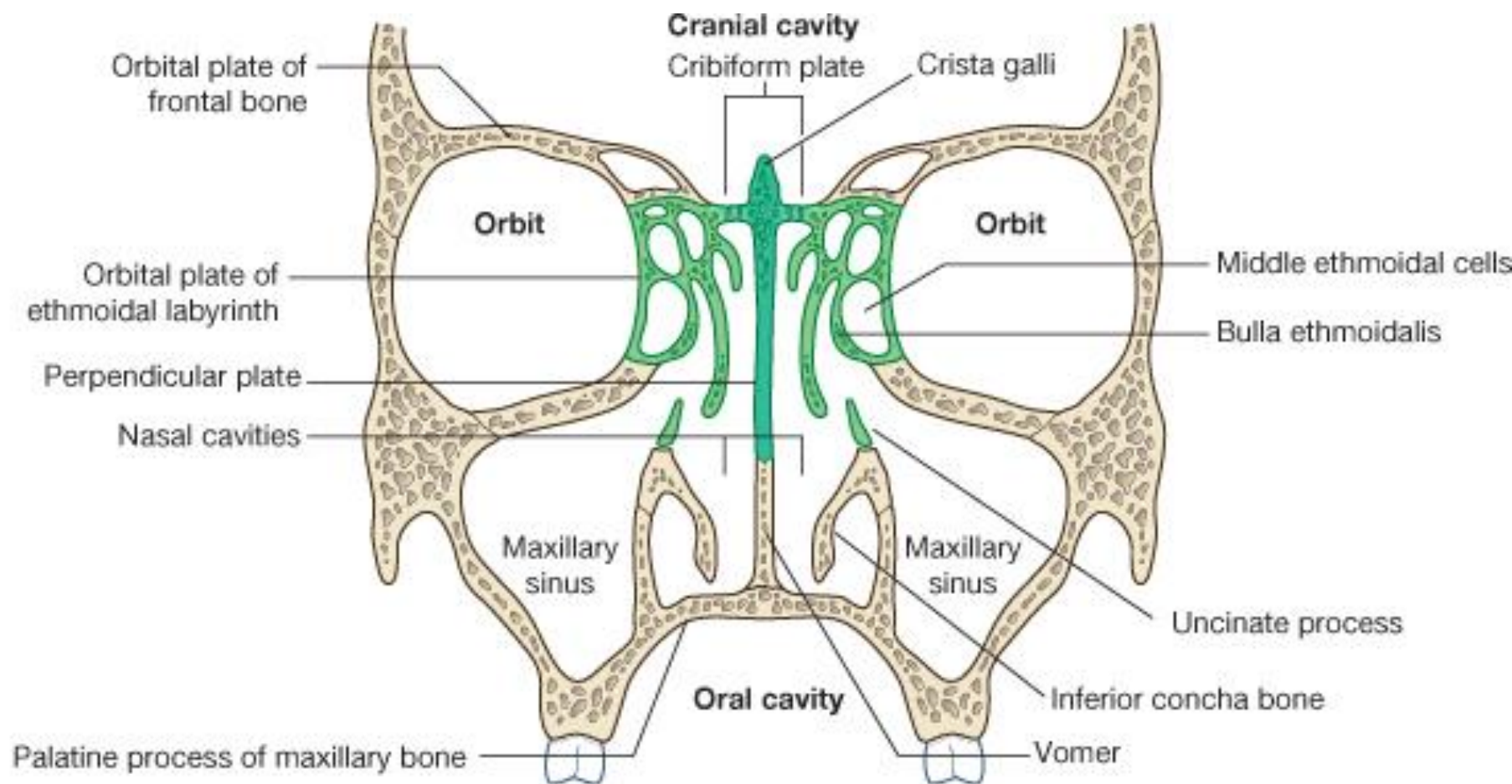


C



A



B

Arteries of nasal mucosa

Maxillary artery

spheno-palatine artery

septal branch & lateral branch

descending palatine artery

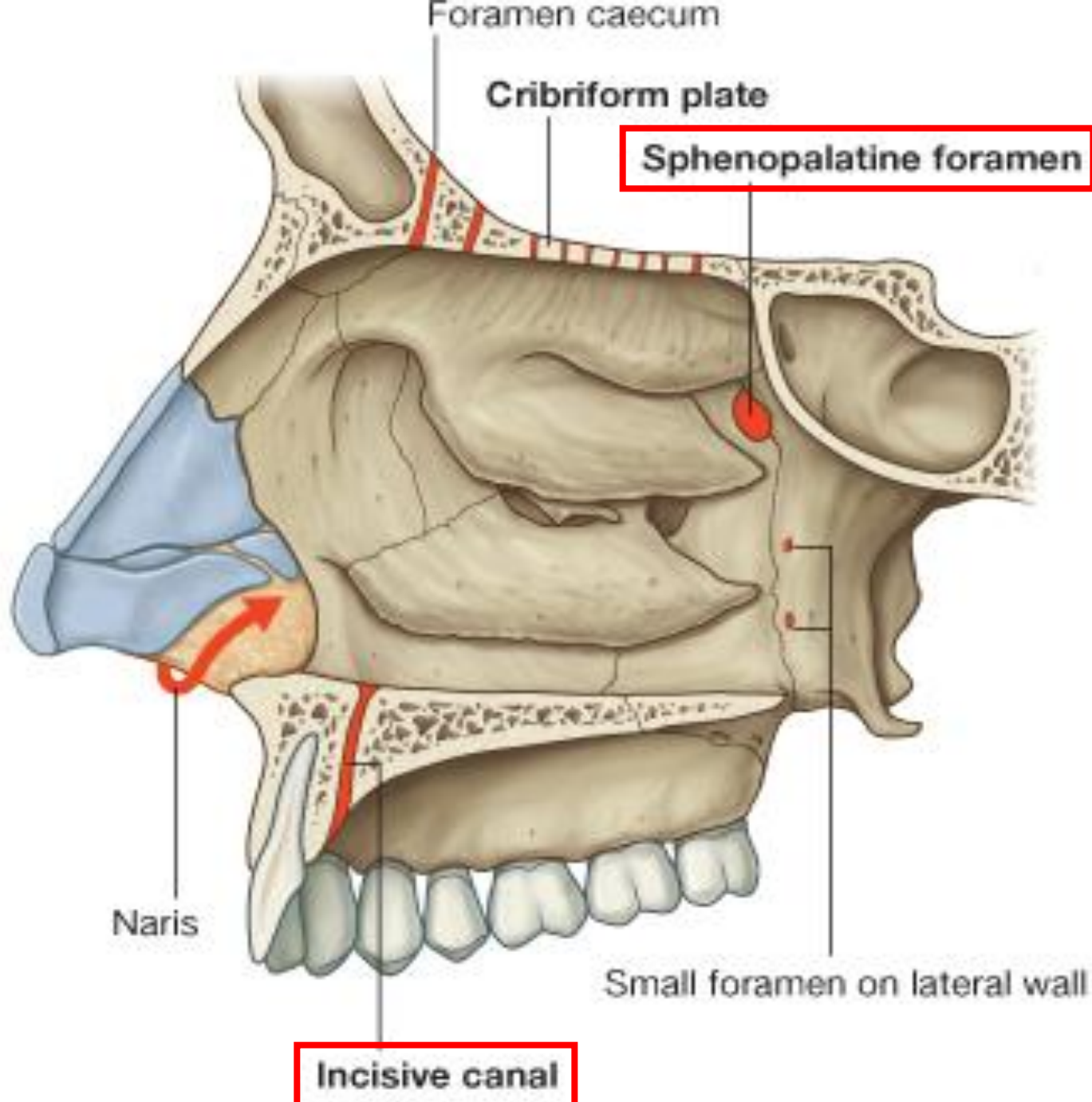
greater & lesser palatine arteries

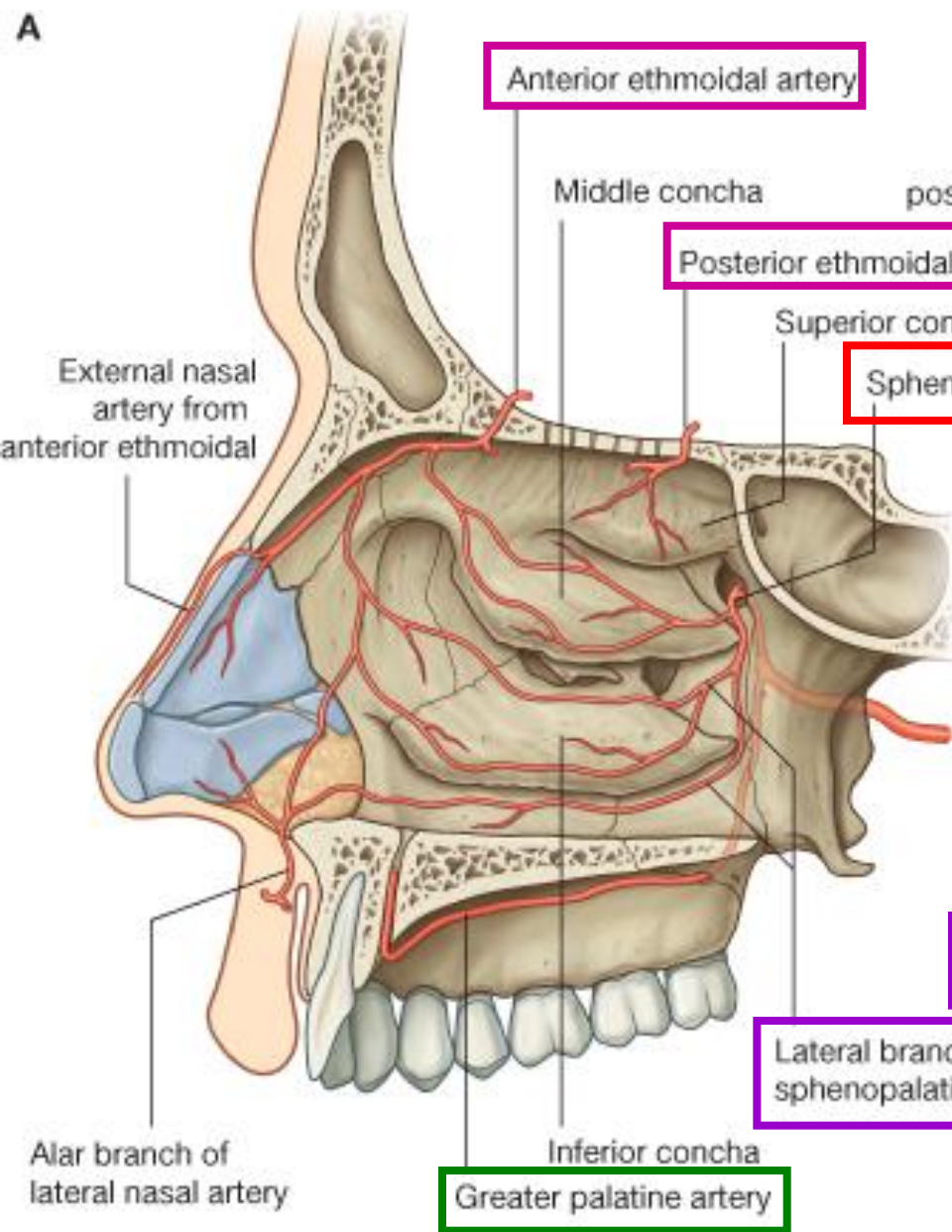
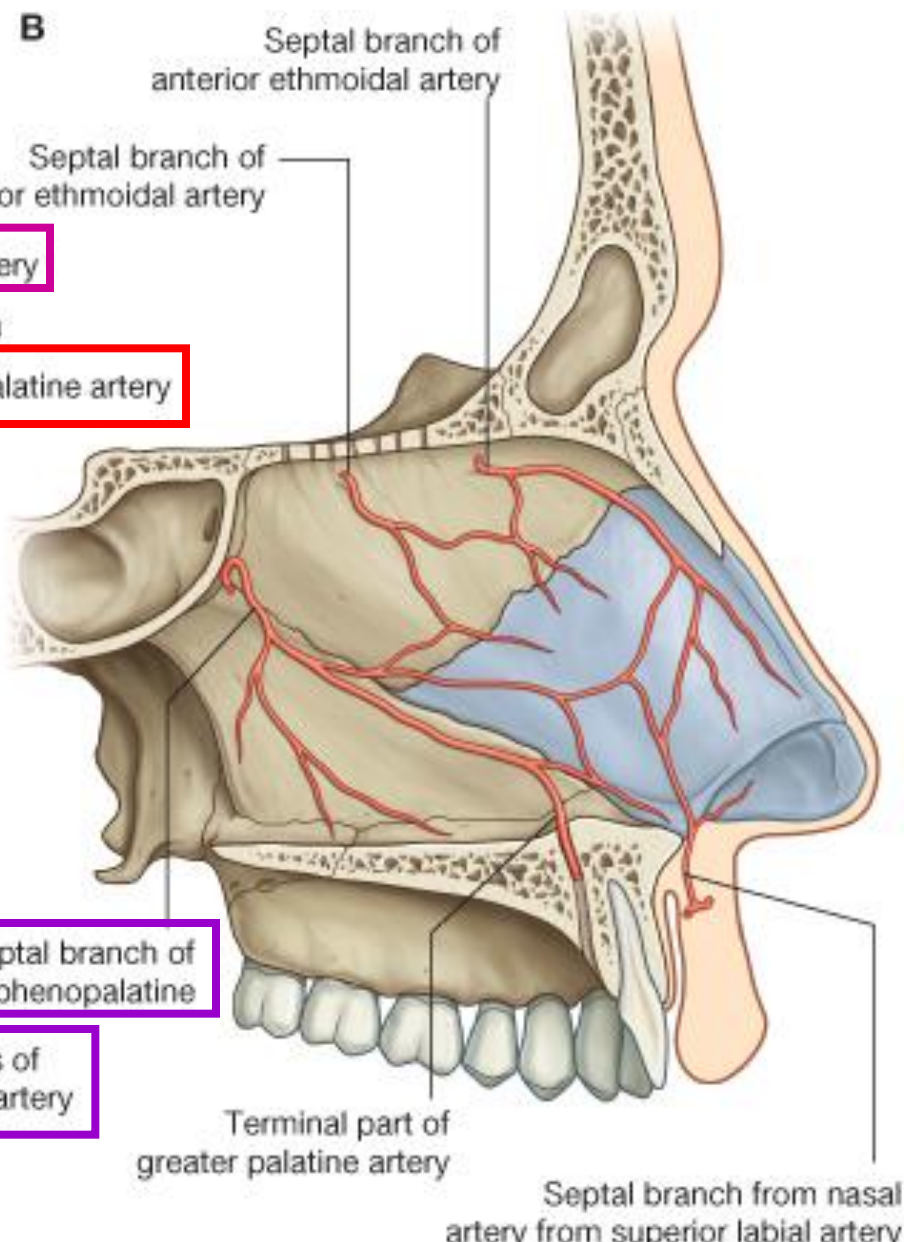
Ophthalmic artery

anterior & posterior ethmoidal arteries

Facial artery

superior & lateral nasal artery



A**B**

Veins of nasal mucosa

posterior region

Sphenopalatine vein

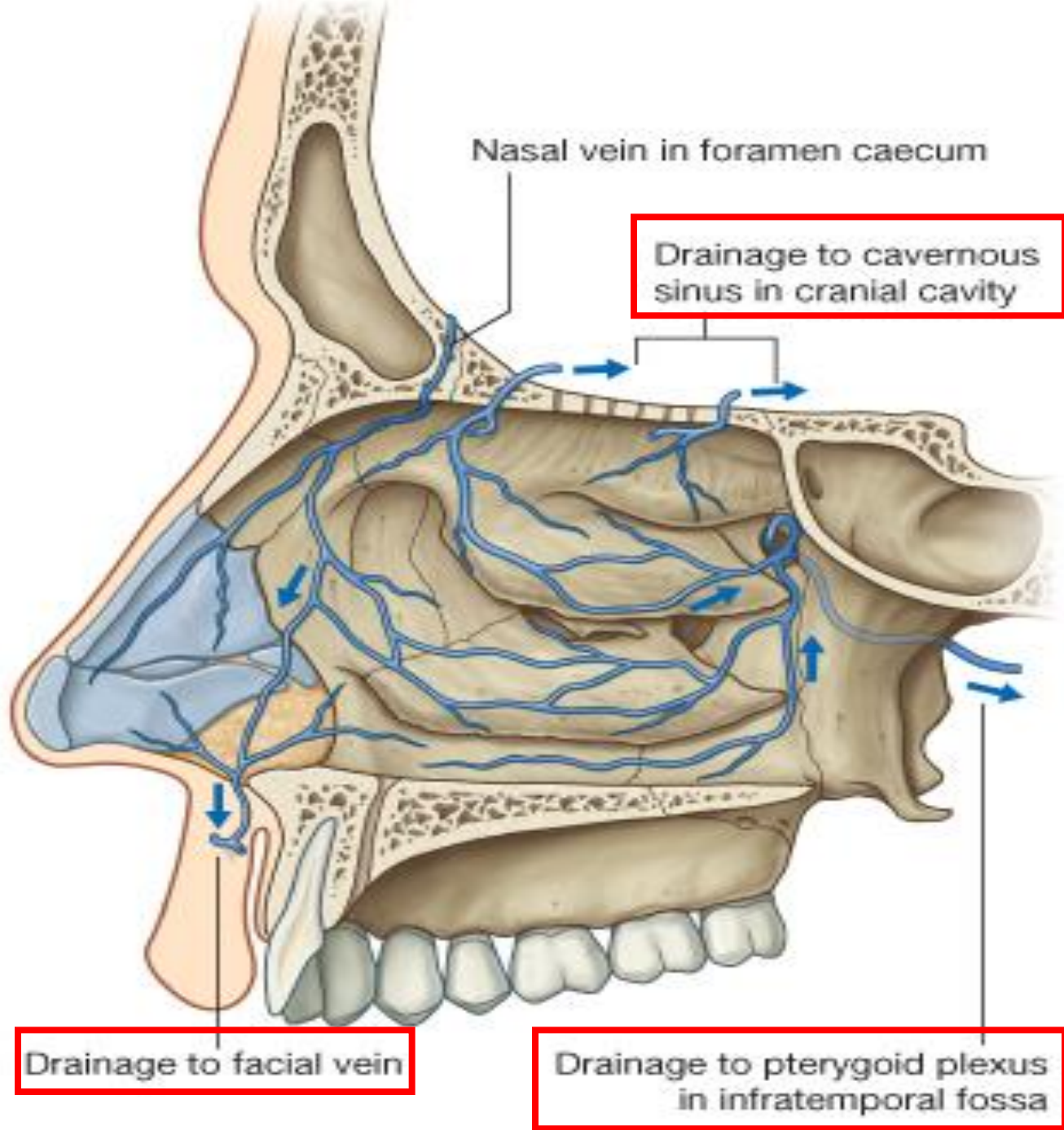
→ **pterygoid venous plexus**

anterior region

Facial vein

superior region

Ophthalmic vein → **cavernous sinus**



Nerves of nasal cavity

nasopalatine nerve

- division of **maxillary nerve (CN V2)**

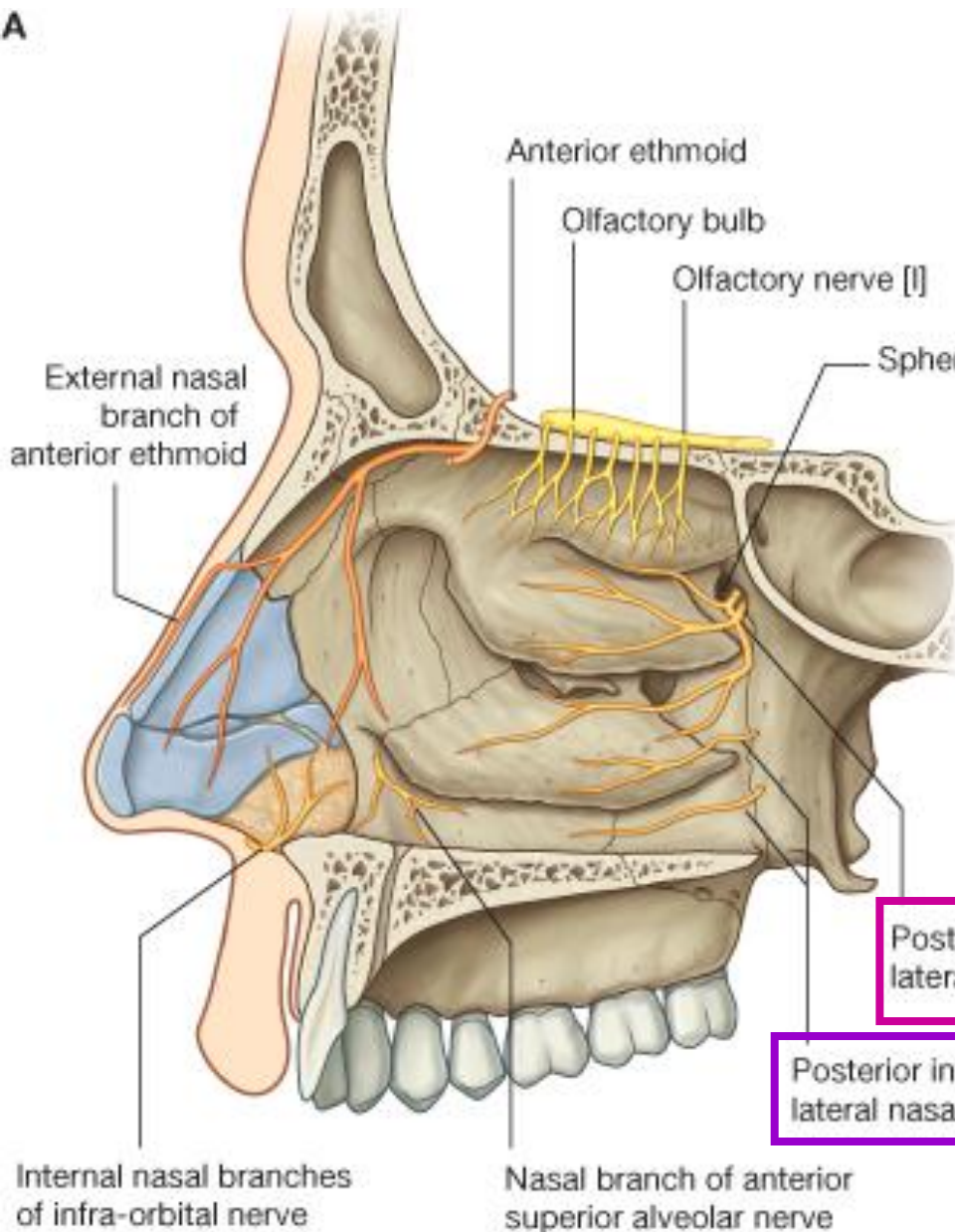
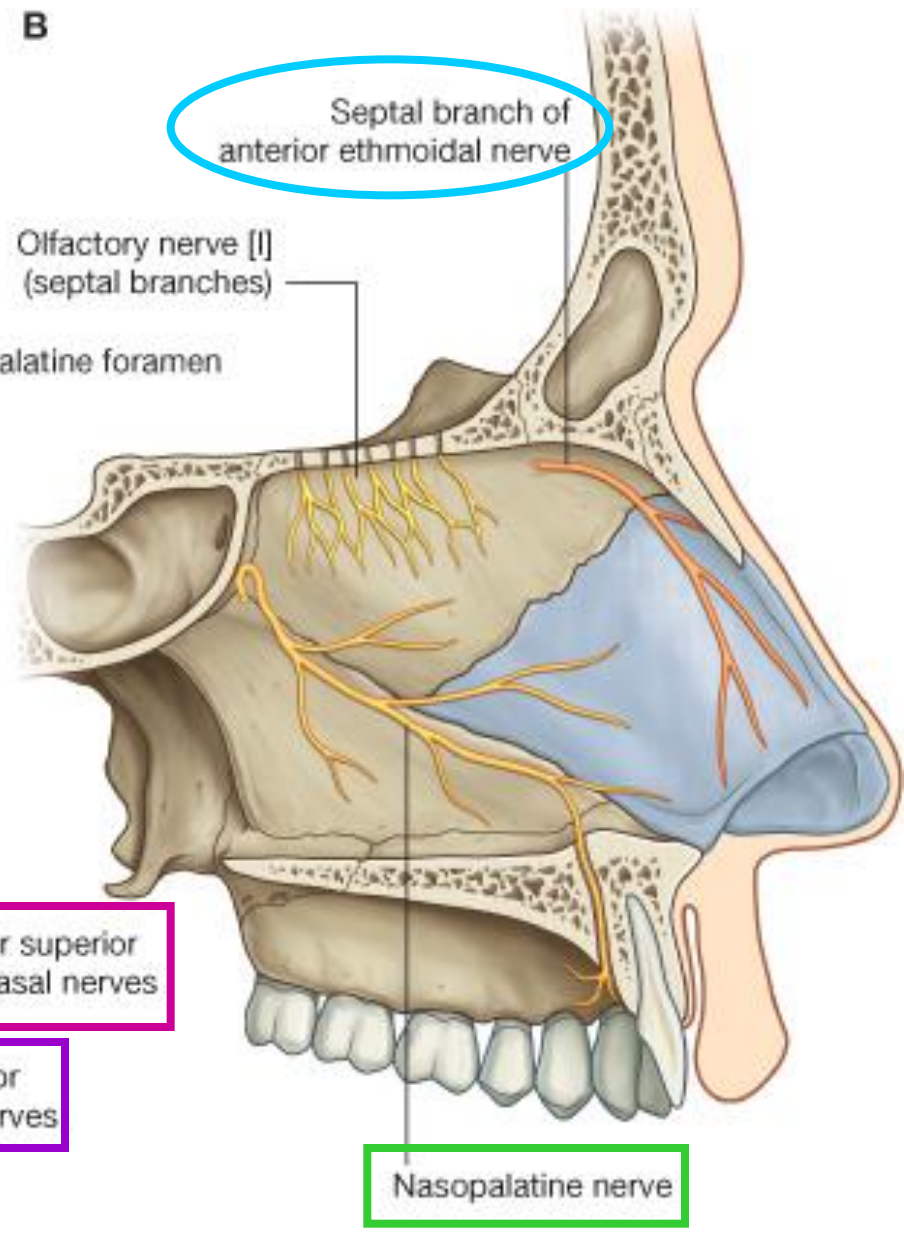
anterior & posterior ethmoidal nerve

- branches of **nasociliary nerve (CN V1)**

lateral nasal branches of **greater palatine nerve**

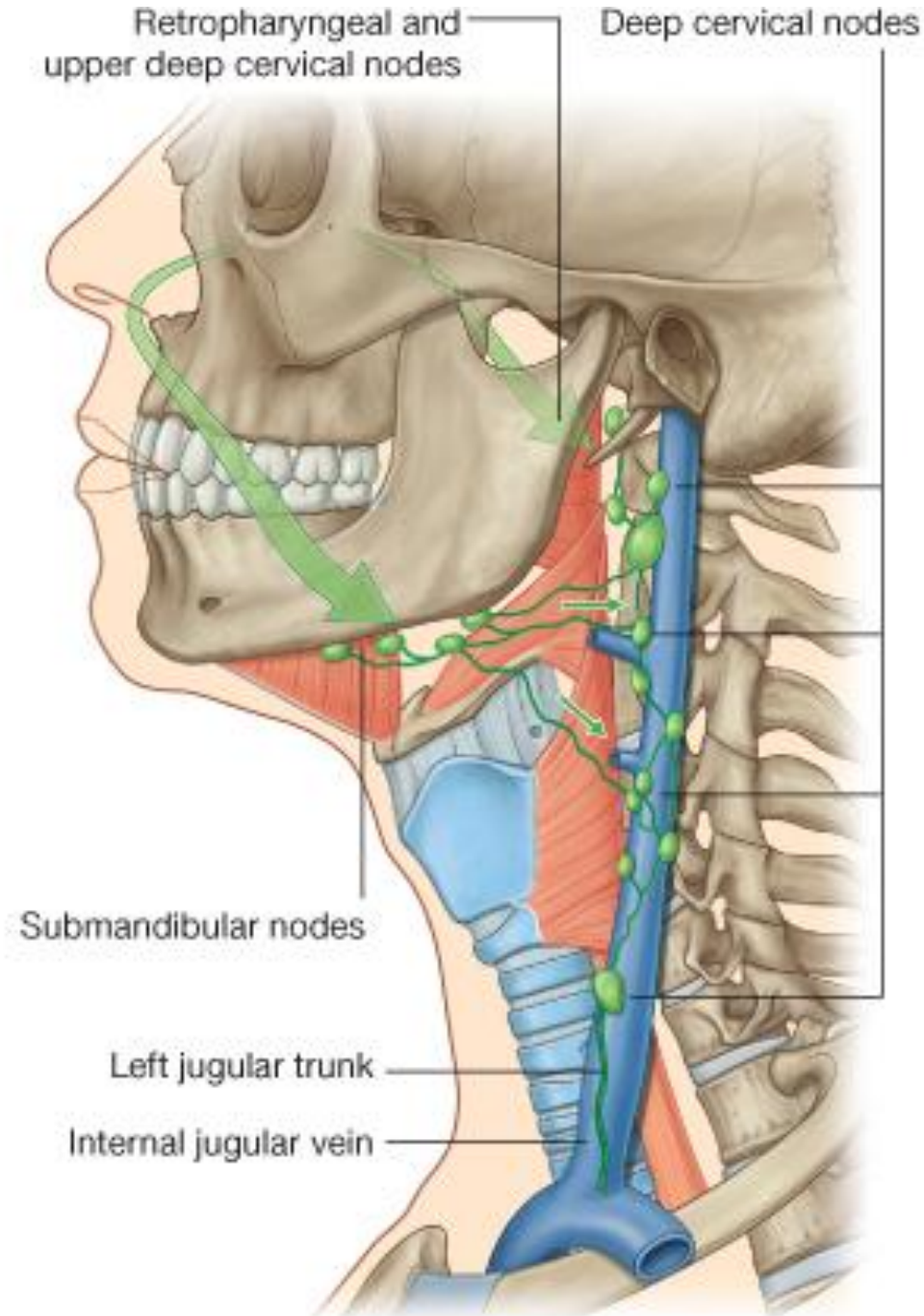
internal nasal branches of **infraorbital nerve**

olfactory nerve

A**B**

Lymphatics

- *Anterior region of nasal cavity*
→ **submandibular nodes**
- *Posterior region of nasal cavity*
→ **retropharyngeal nodes**



The Pterygopalatine Fossa

anterior: maxilla

posterior: pterygoid process of sphenoid bone

medial: palatine bone

lateral: infra-temporal fossa

roof: sphenoid bone

floor: pyramidal process of palatine bone

The Pterygopalatine Fossa

canals: **pterygoid canal** (→ middle cranial fossa),
palatine canal (→ palate),
pharyngeal canal (→ nasopharynx)

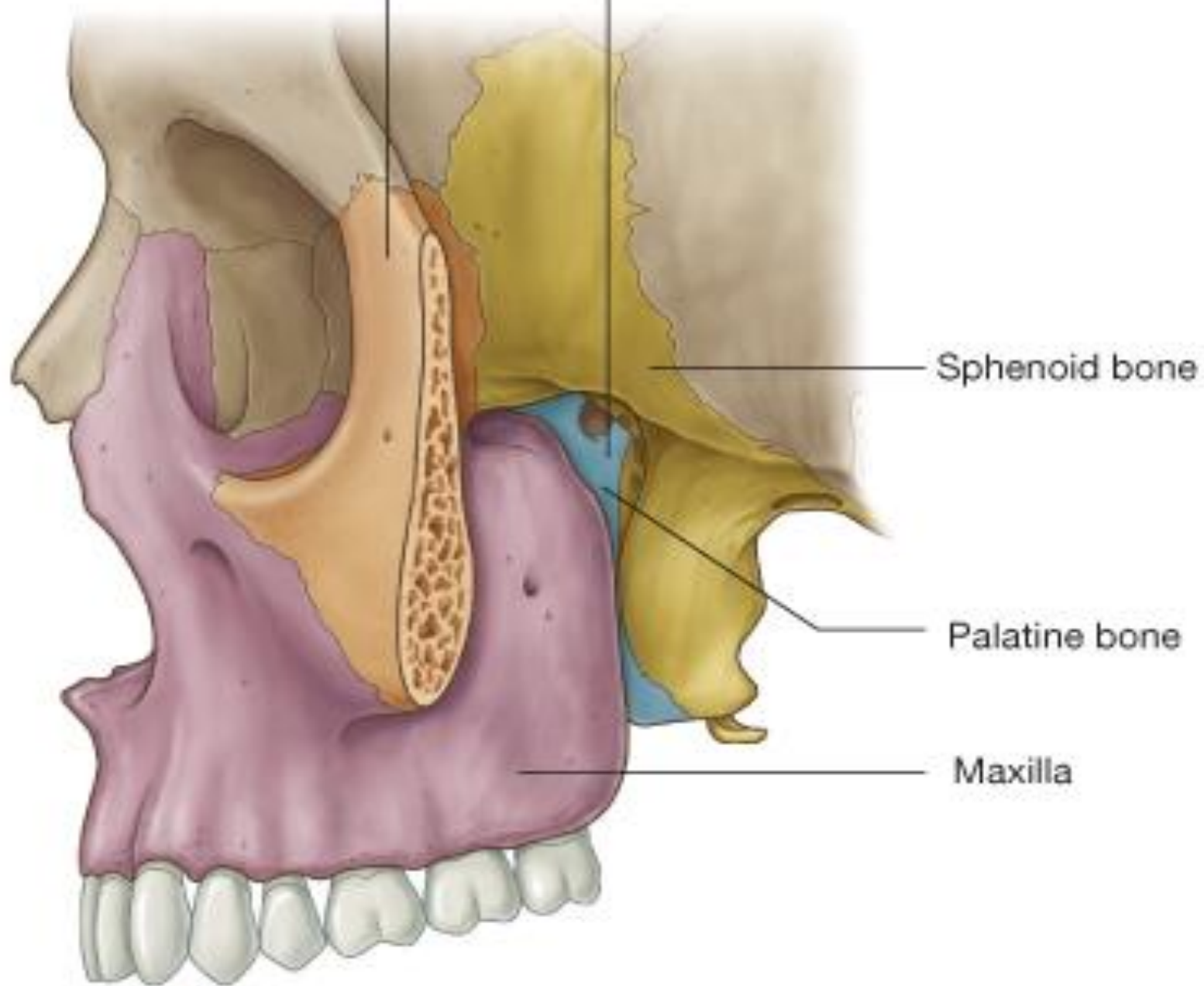
foramens: **foramen rotundum** (→ middle cranial fossa),
sphenopalatine foramen (→ nasal cavity)

fissures: **inferior orbital fissure** (→ orbit),
pterygomaxillary fissure (→ infratemporal fossa)

A

Zygomatic bone

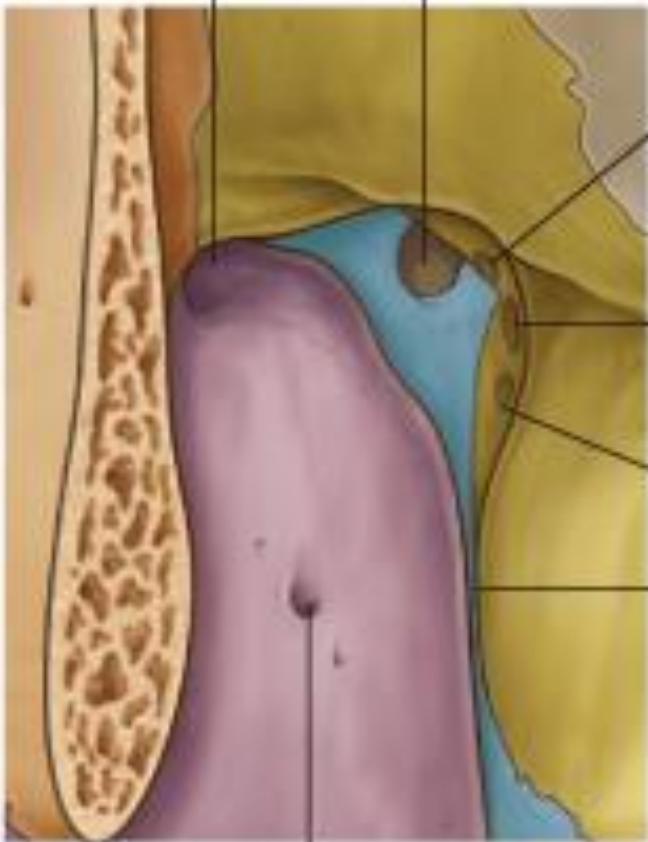Pterygopalatine fossa



B

Inferior orbital fissure

Sphenopalatine foramen



Palatovaginal canal
(Pharyngeal canal)

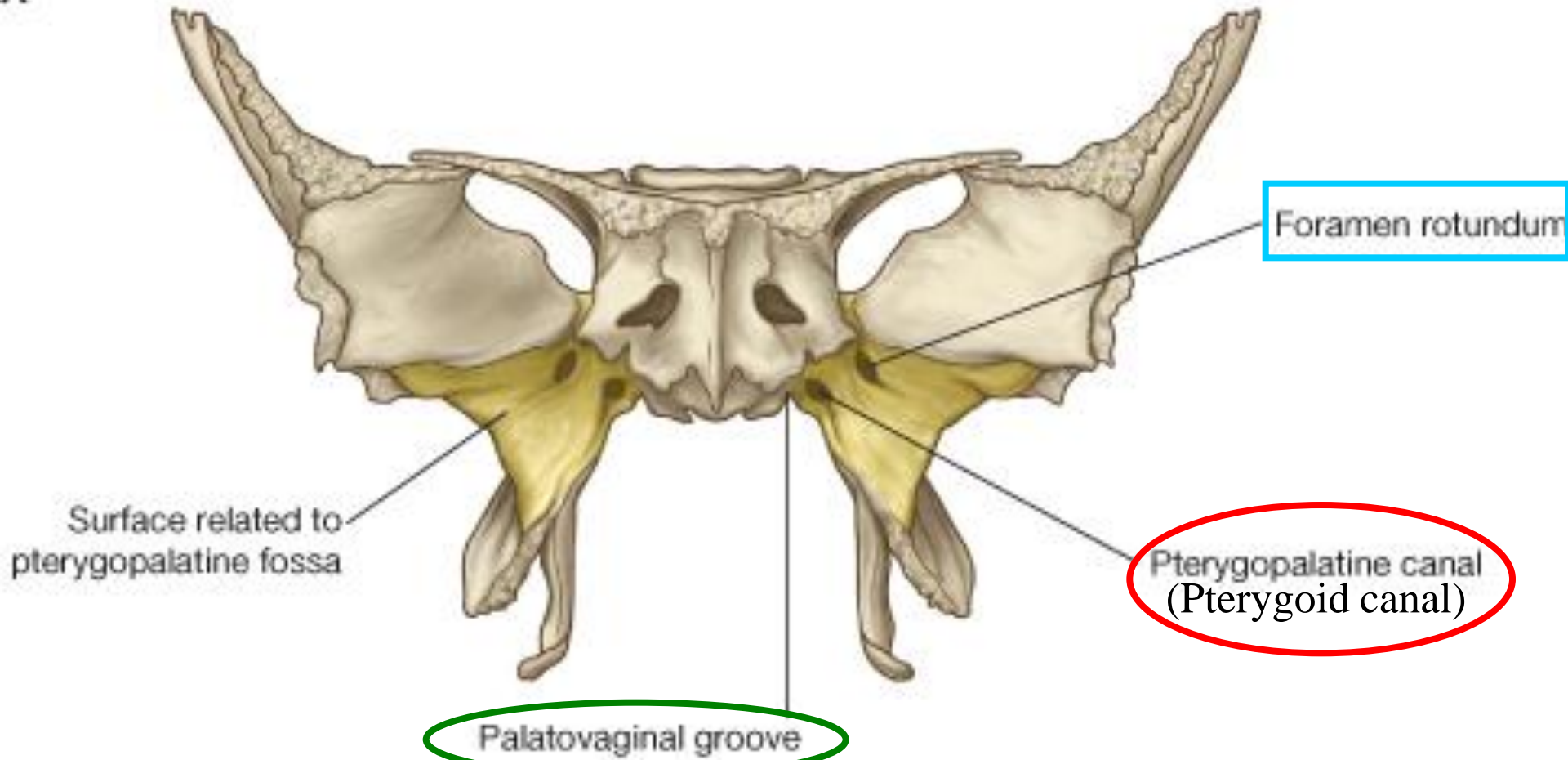
Foramen rotundum

Pterygoid canal

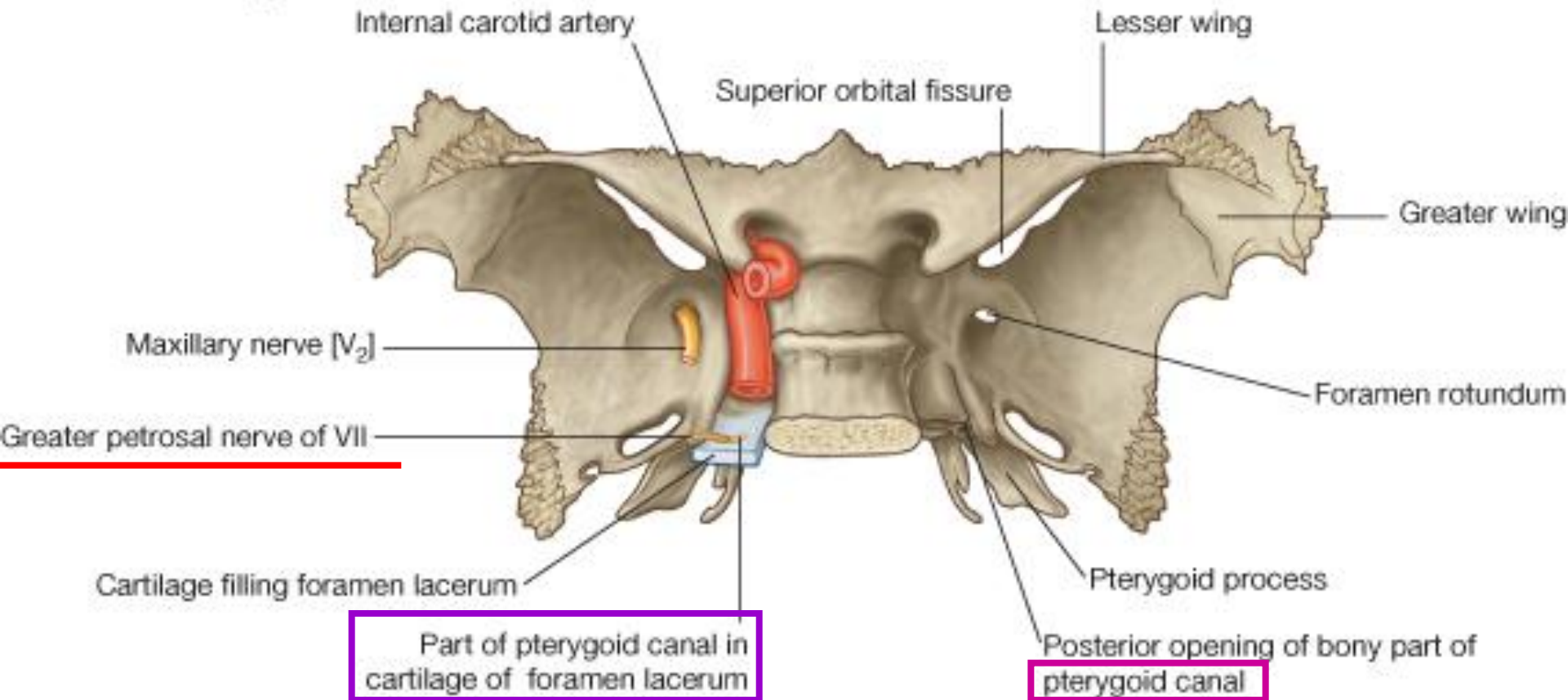
Palatine canal

Alveolar foramen

A



B



Sphenopalatine foramen
nasal cavity

Inferior orbital fissure
floor of orbit

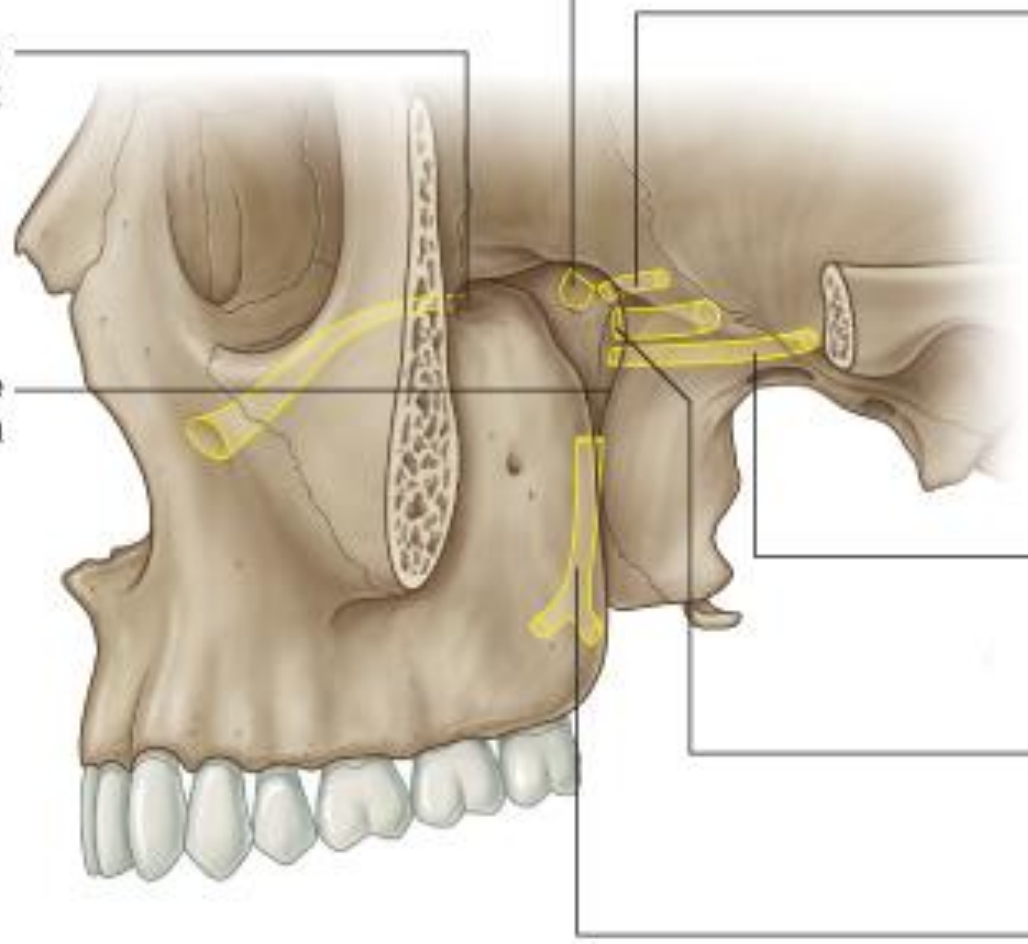
Pterygomaxillary fissure
infratemporal fossa

Palatovaginal canal
nasopharynx

Pterygoid canal
cranial cavity
(middle cranial fossa)

Foramen rotundum
cranial cavity
(middle cranial fossa)

Palatine canal
roof of oral cavity (palate)



Contents of the pterygo-palatine fossa

(1) branches of 3rd part of **maxillary artery**

post. sup. alveolar artery

descending palatine artery

(→ **greater & lesser palatine arteries**)

artery of pterygoid canal

sphenopalatine artery

(→ **post. nasal lateral artery**

& post. nasal septal artery)

infraorbital artery (→ ant. sup. alveolar artery)

Contents of the pterygo-palatine fossa

(2) branches of maxillary nerve

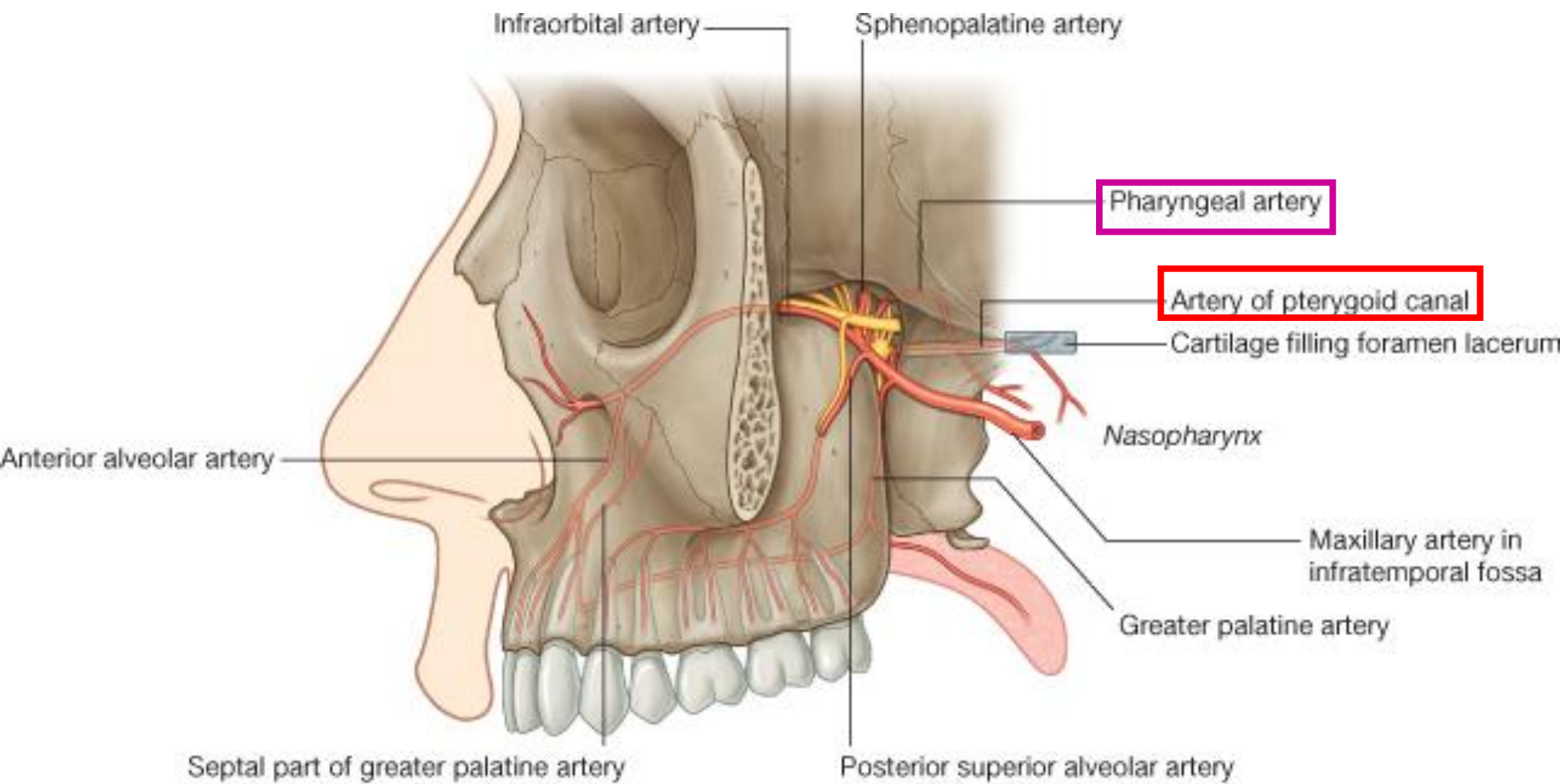
zygomatic nerve

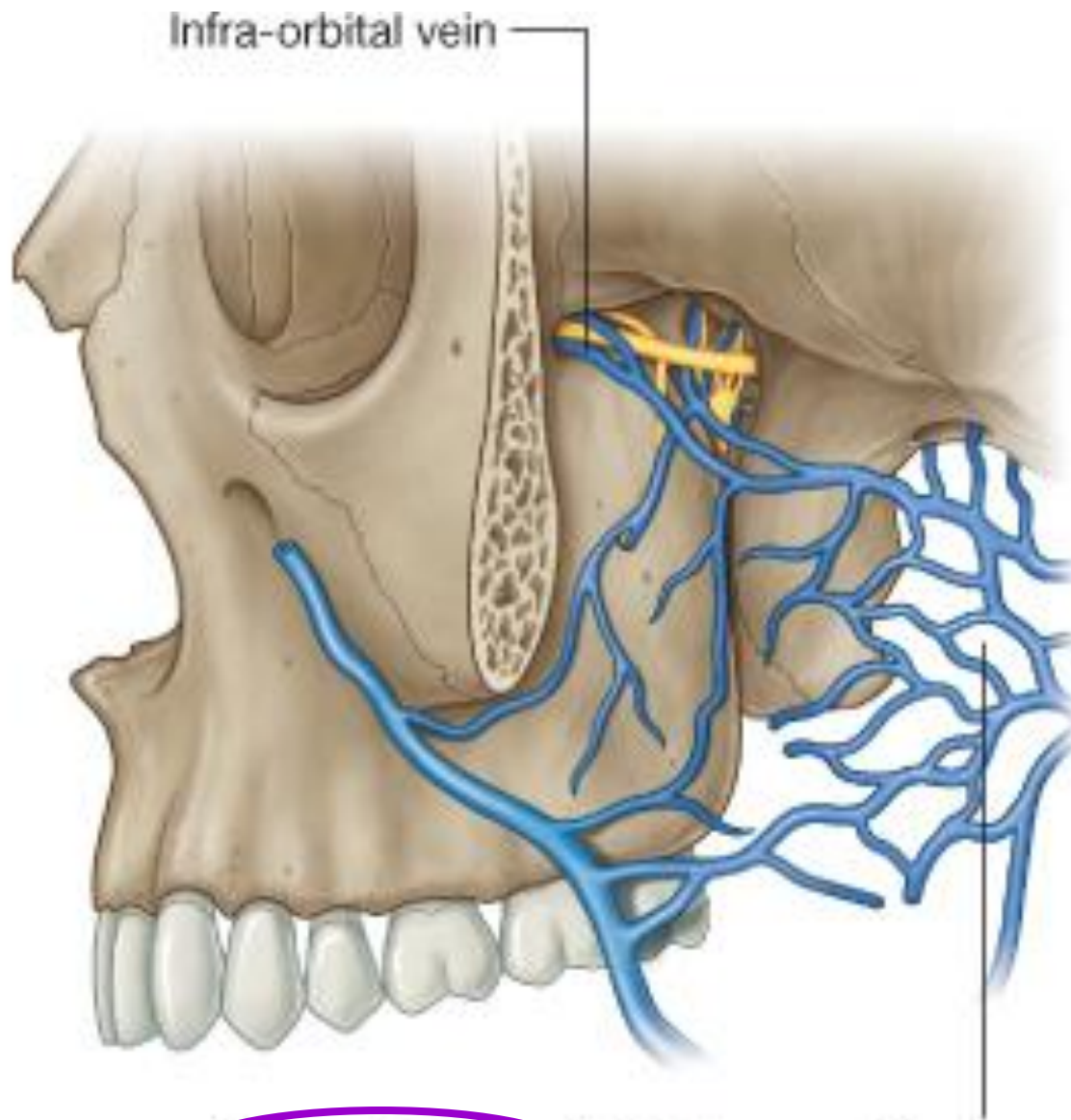
(→ zygomaticofacial & zygomaticotemporal nerves)

two pterygopalatine nerves

– suspend **pterygopalatine ganglion**

infraorbital nerve



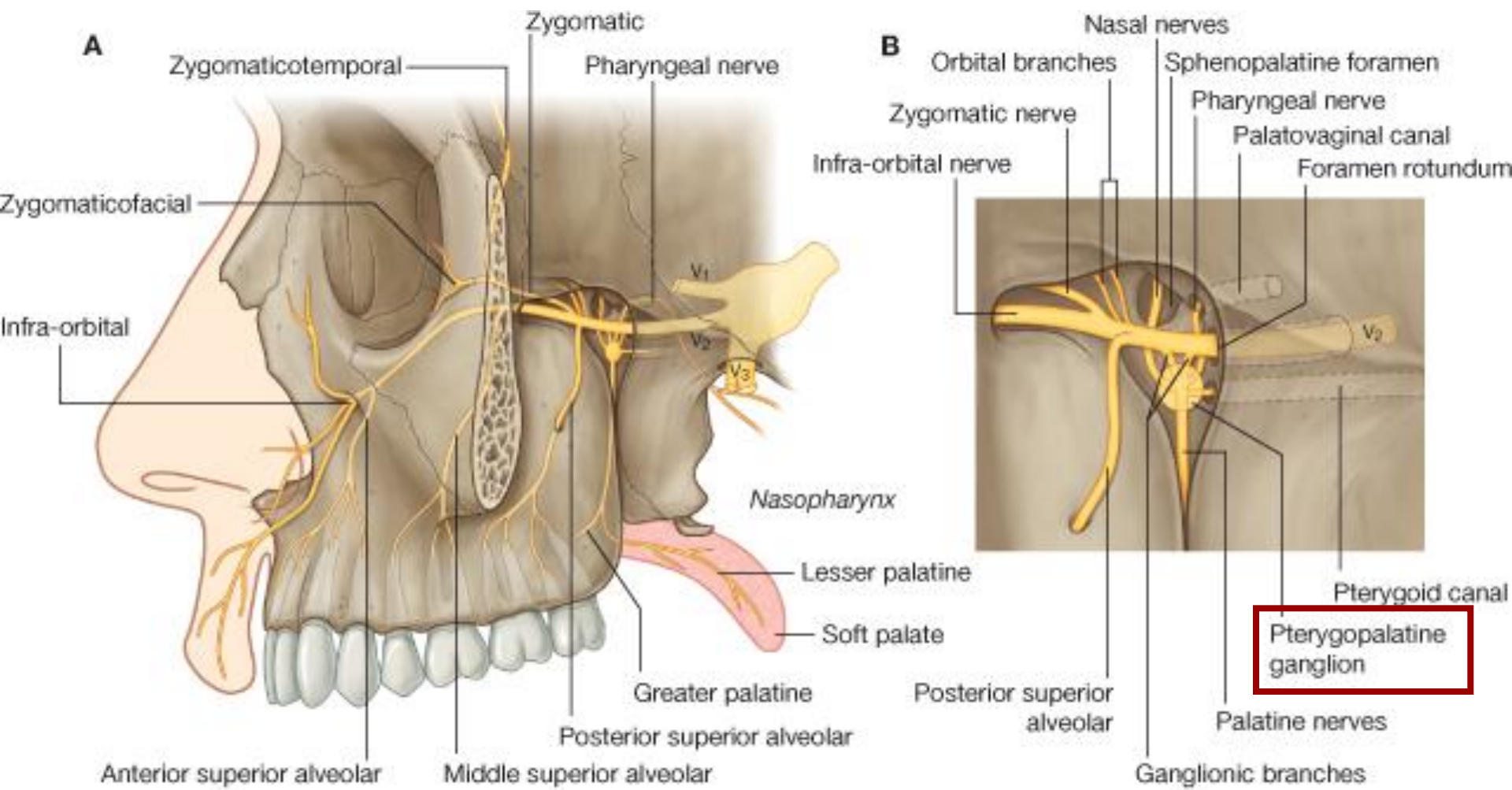


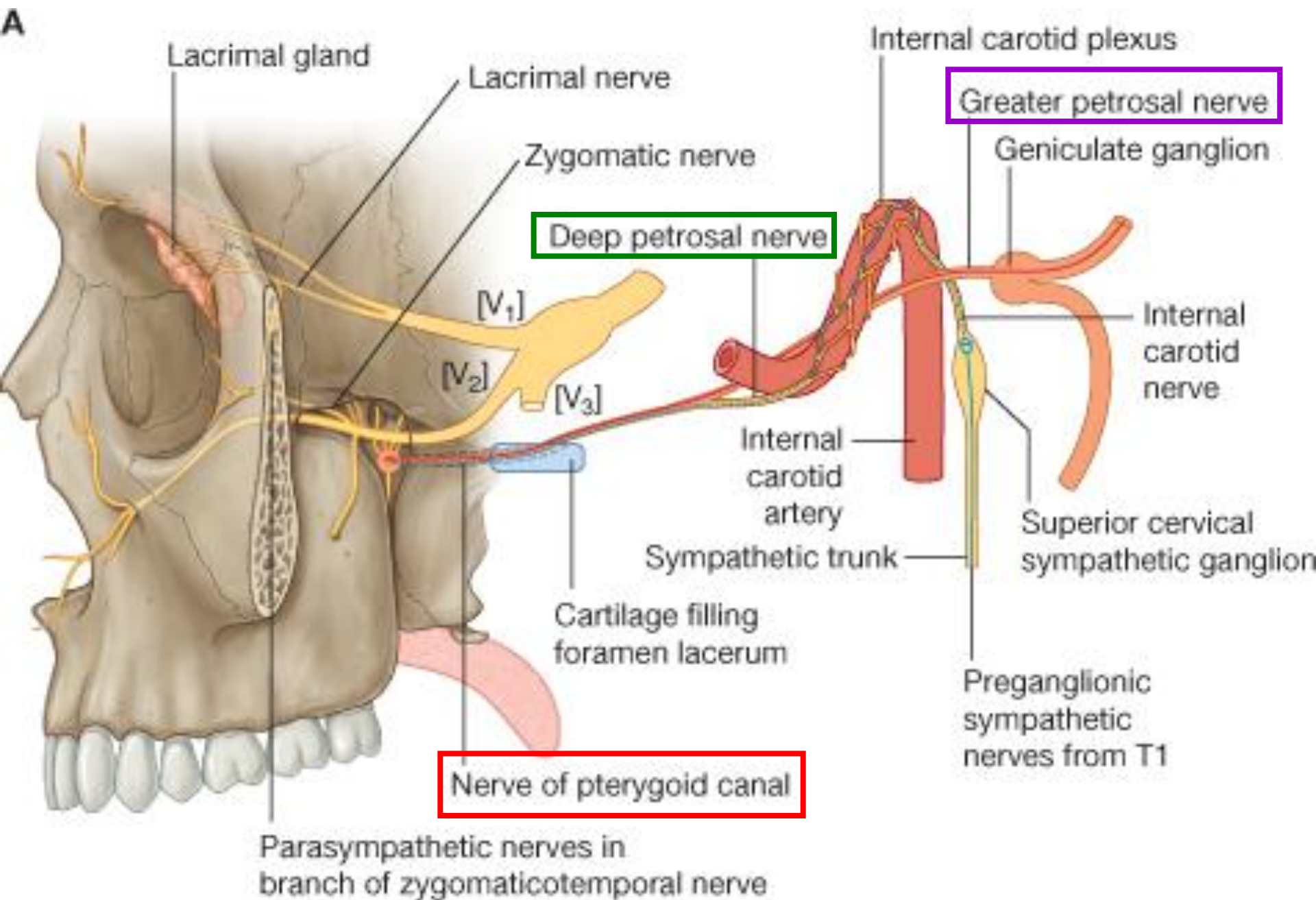
Infra-orbital vein

Pterygoid plexus in infratemporal fossa

(3) **pterygo-palatine ganglion**
(**sensory** + **parasympathetic** nerve fibers)
greater & lesser palatine nerves
nasopalatine nerve
pharyngeal nerve

(4) **nerve of pterygoid canal**
= **greater petrosal nerve** + **deep petrosal nerve**
(parasympathetic fibers) (sympathetic fibers)



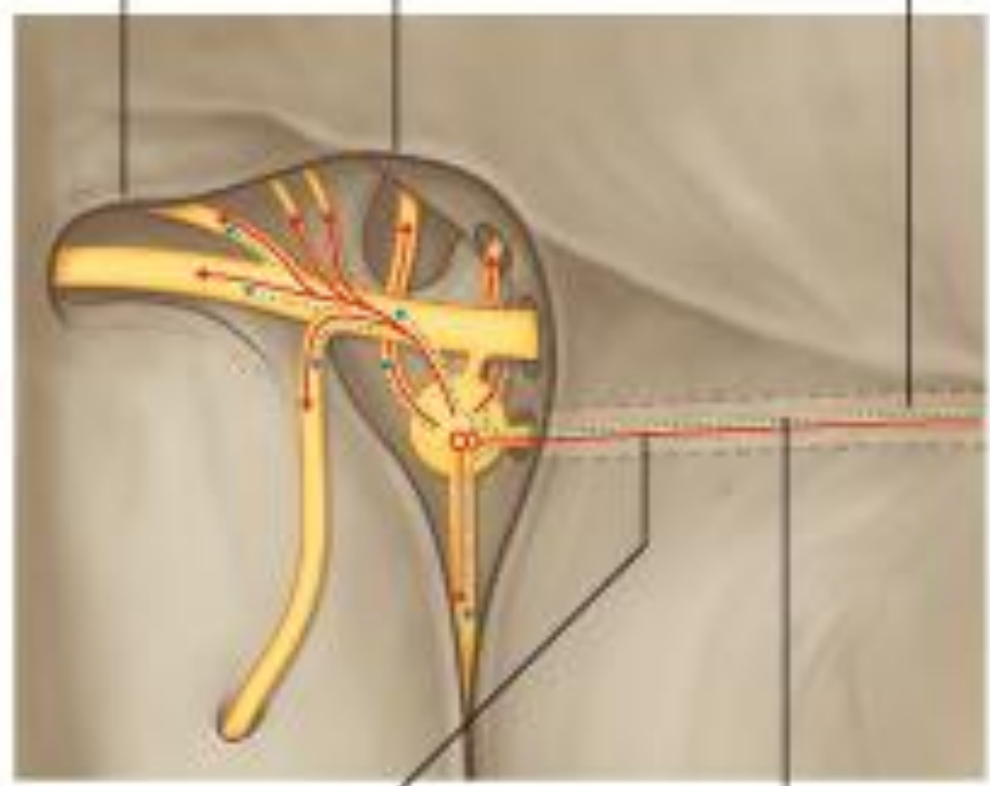


B

Nerve of pterygoid canal

Inferior orbital fissure

Pterygopalatine fossa



Preganglionic
parasympathetic
nerves

Postganglionic
sympathetic
nerves

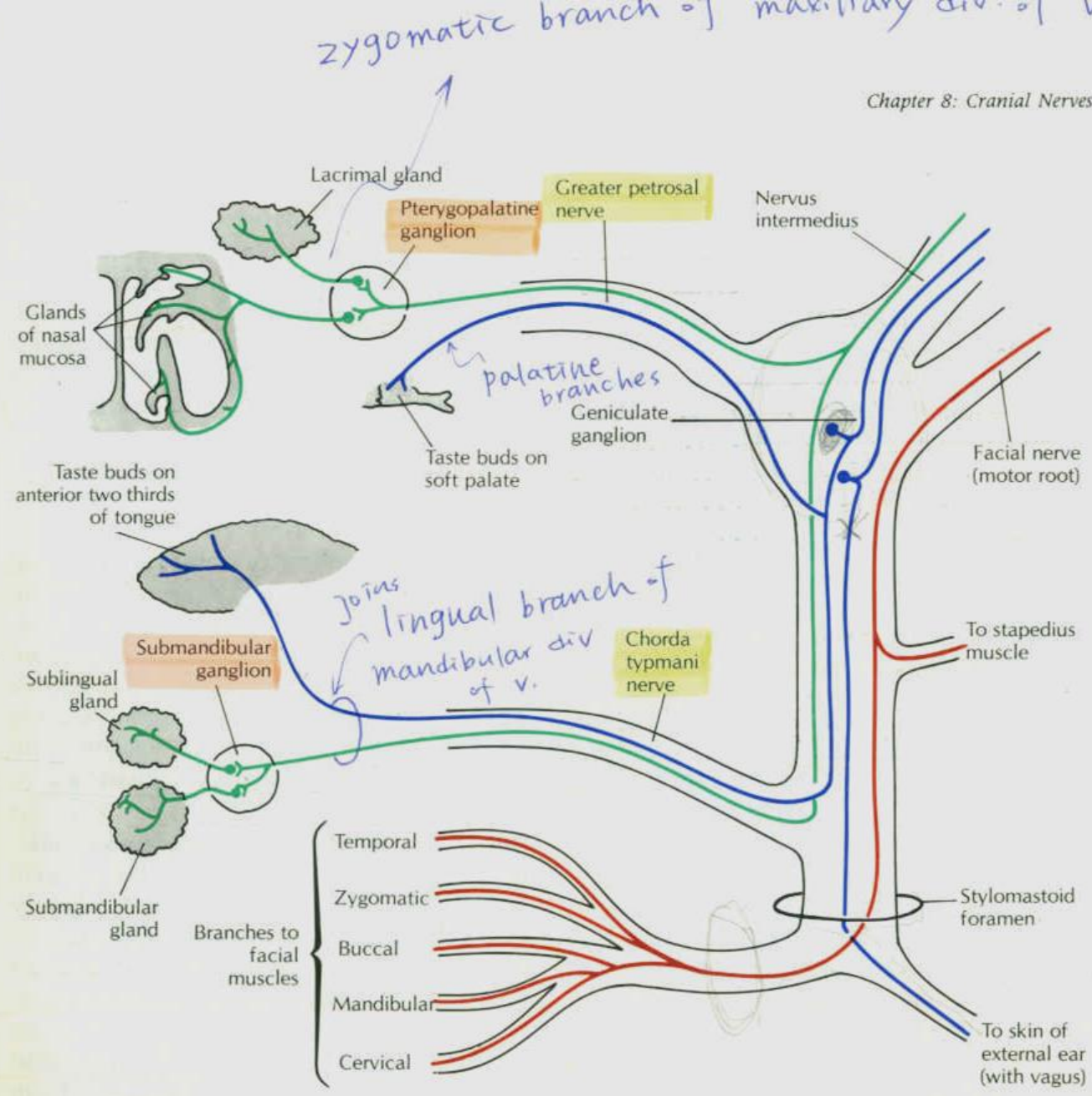


Figure 8-10. Components of the peripheral parts of the facial nerve. (Primary sensory neurons are blue; motor neurons are red; preganglionic and postganglionic parasympathetic neurons are green.)

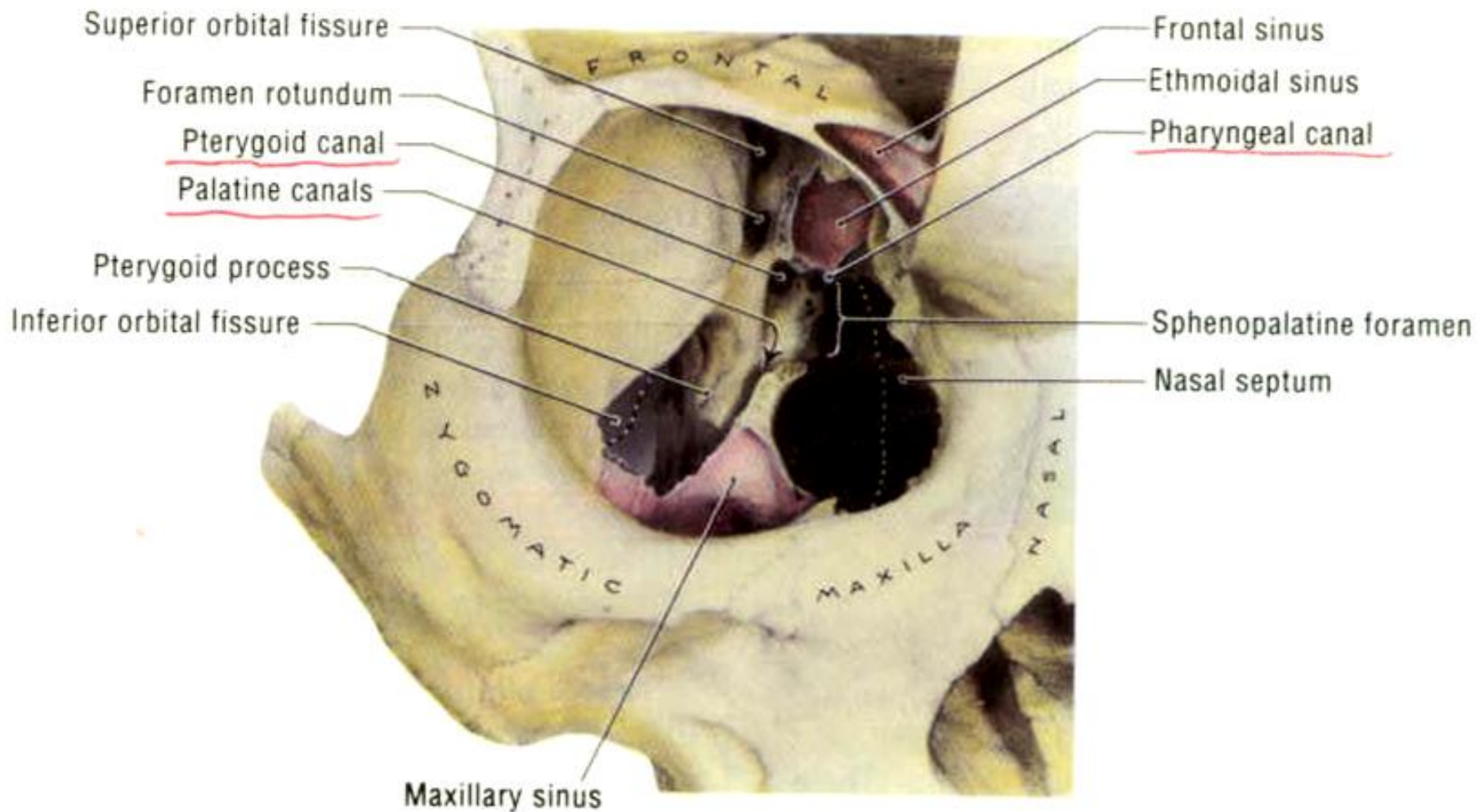


Figure 7-103. Anterior view of the pterygopalatine fossa that has been exposed through the floor of the orbit and maxillary sinus. (For a lateral view of the pterygopalatine fossa, see Fig. 7-76B.)

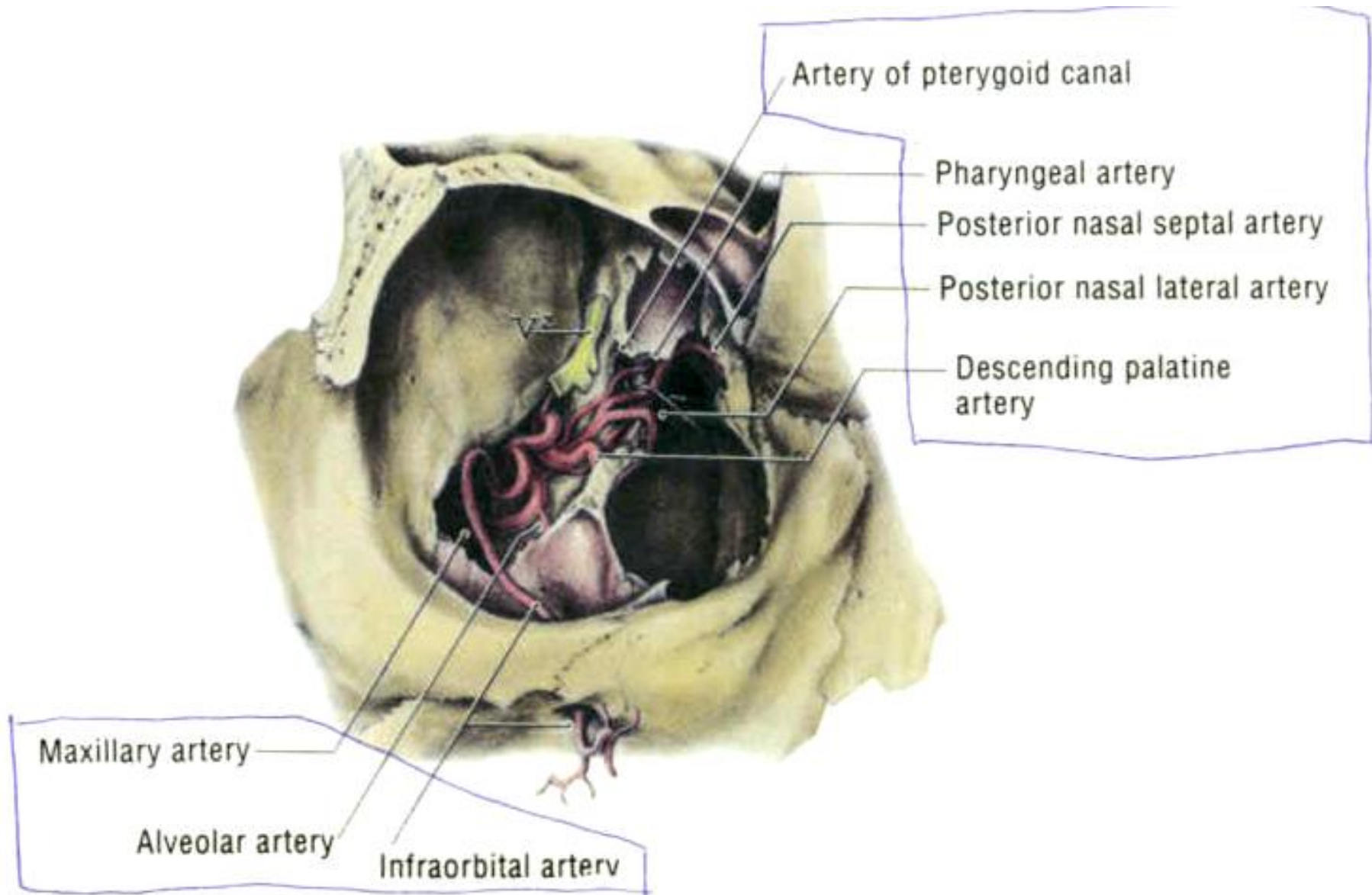


Figure 7-105. The third or pterygopalatine part of the maxillary artery.

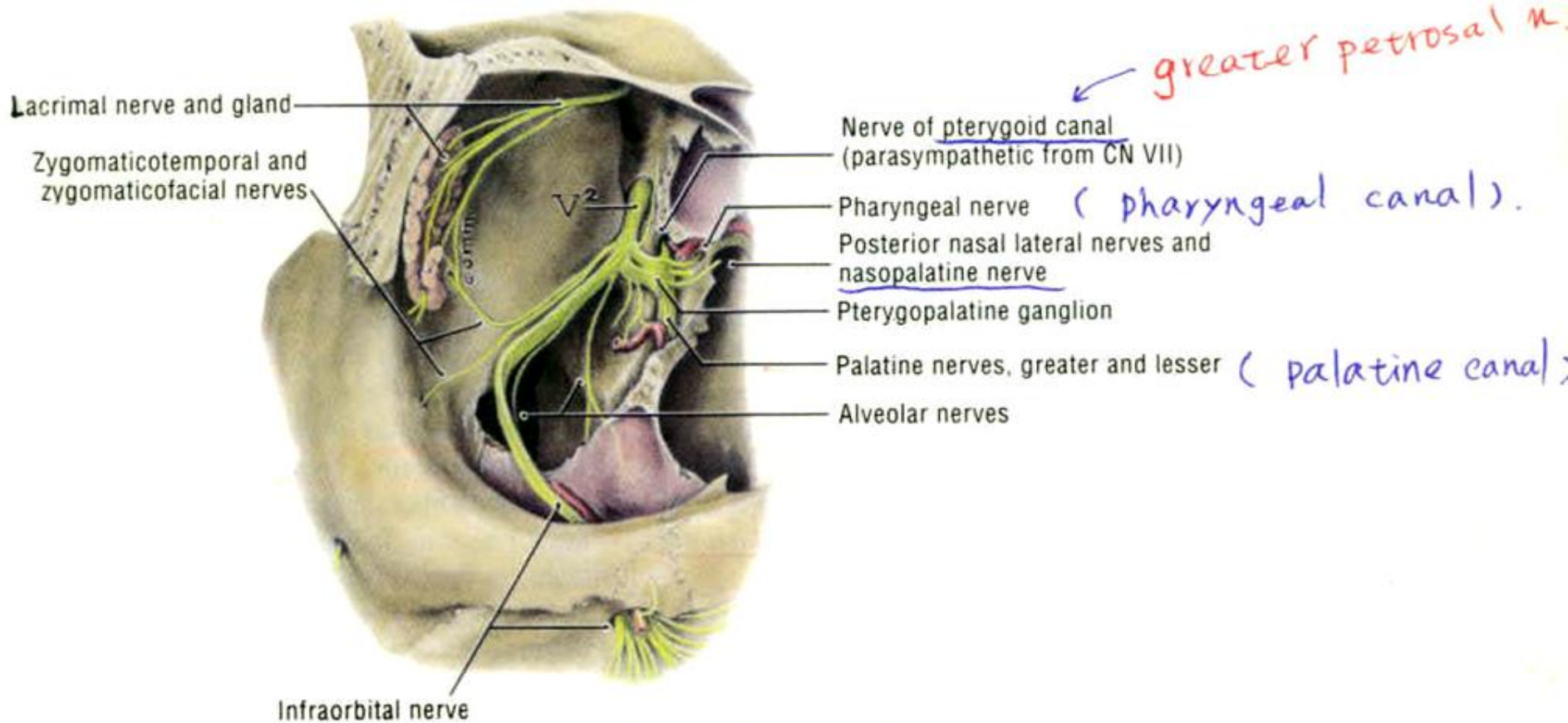


Figure 7-104. Dissection of the maxillary nerve (CN V²).

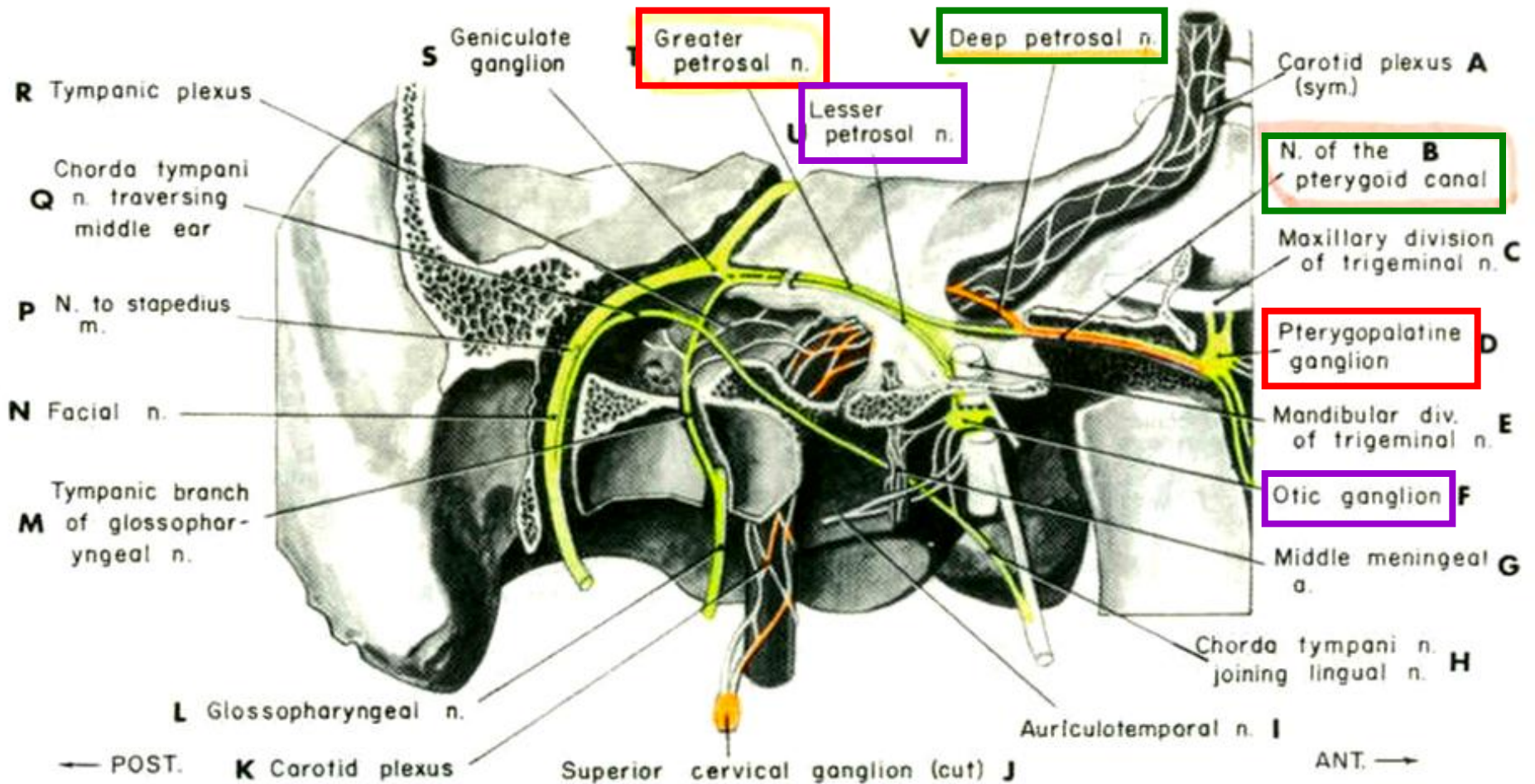


Figure 7-74. Origin and destination of the petrosal nerves—right side. (Modified after Warren). This is a longitudinal section through the middle ear and adjoining structures.

Dissection

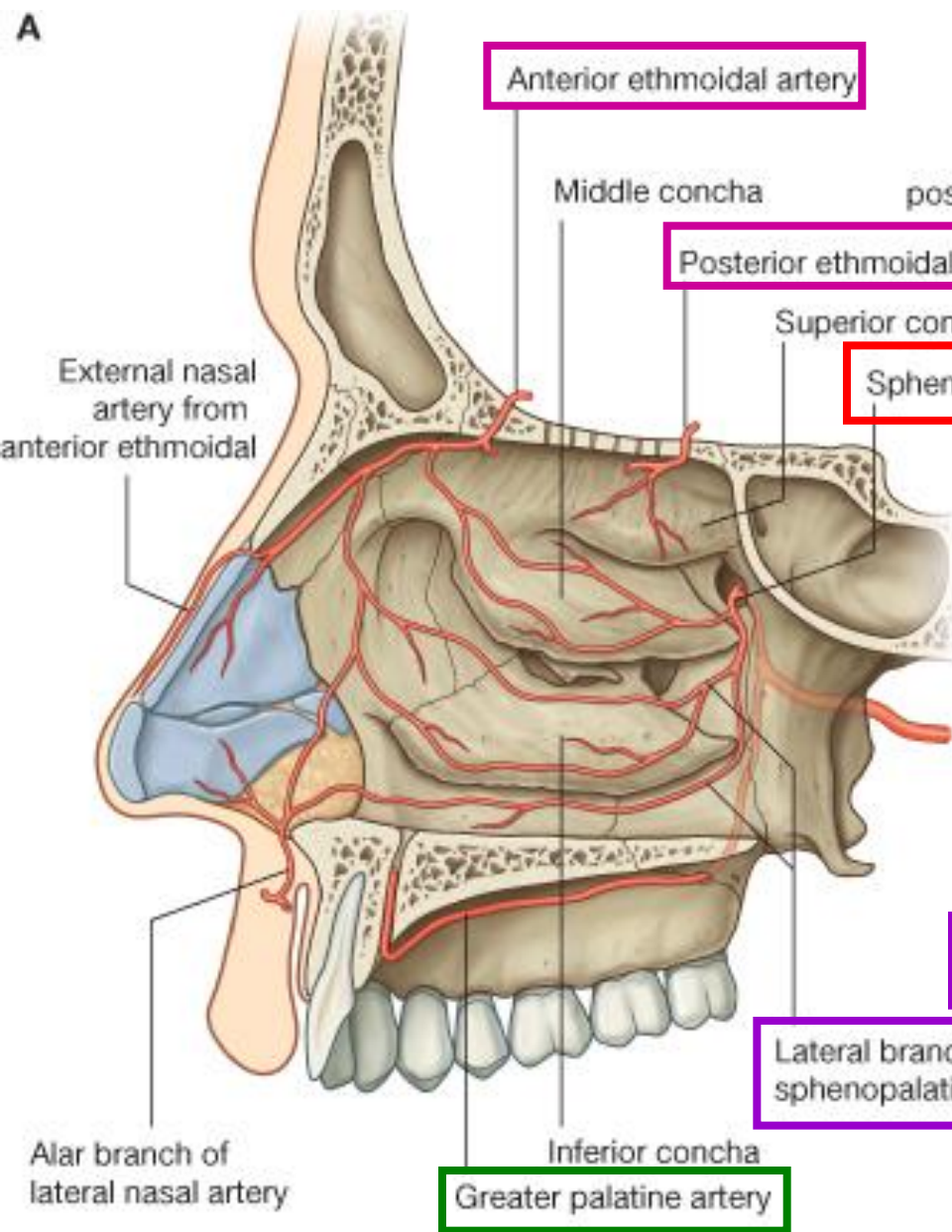
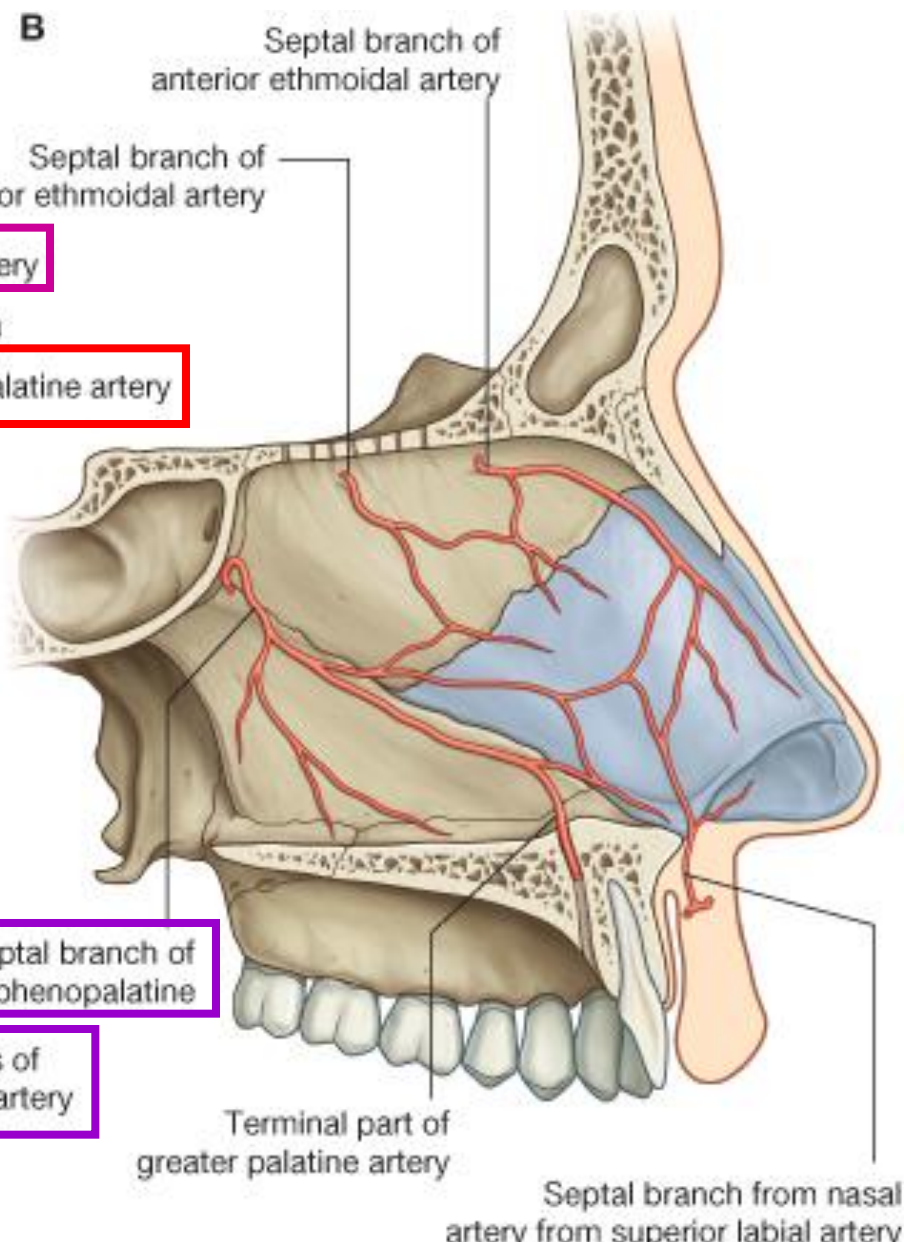
Bisection of Head (I)

Usually, **nasal septum** deviates to one side.

1. Saw just lateral to **crista galli** through one of the **cribriform plates** of **ethmoid bone**.
2. Then, through **the body of sphenoid bone** and **part of occipital bone** to foramen magnum.
3. Saw through the **hard palate**.
4. Cut through the **upper lip**, divide the **uvula** and **soft palate** in the mid-sagittal plane.

Bisection of Head (II)

5. Slit open the naris, the head was bisected.
The **tongue** lies exposed.
6. Examine **sulcus terminalis**, **foramen cecum**, **filiform, fungiform & vallate papillae** and **lingual tonsil**.
7. A median fold of mucous membrane, the median **glosso-epiglottic fold**.
8. The tongue is supplied by five cranial nerves (**V, VII, IX, X, XII**)

A**B**

Bisection of mandible and floor of mouth

1. Split the thin **raphe of mylohyoids** and separate the muscles.
2. Identify the paired **geniohyoids**, saw through **mandible** just between the geniohyoid ms.
3. Finally, bisect the **tongue** from the tip to the **hyoid bone** and to the **epiglottis**.

Do not destroy the epiglottis and hyoid bone at this time.

Nasal cavities

Nasal septum

1. Strip the *mucoperiosteum* and identify the **perpendicular plate of ethmoid bone, vomer and septal cartilage.**
2. Examine the nerves to nasal septum.
3. **Nasopalatine nerve** (a branch of V2 via **pterygopalatine ganglion**) toward **incisive canal.**
4. **Anterior ethmoid nerve** (fine branch of V1)

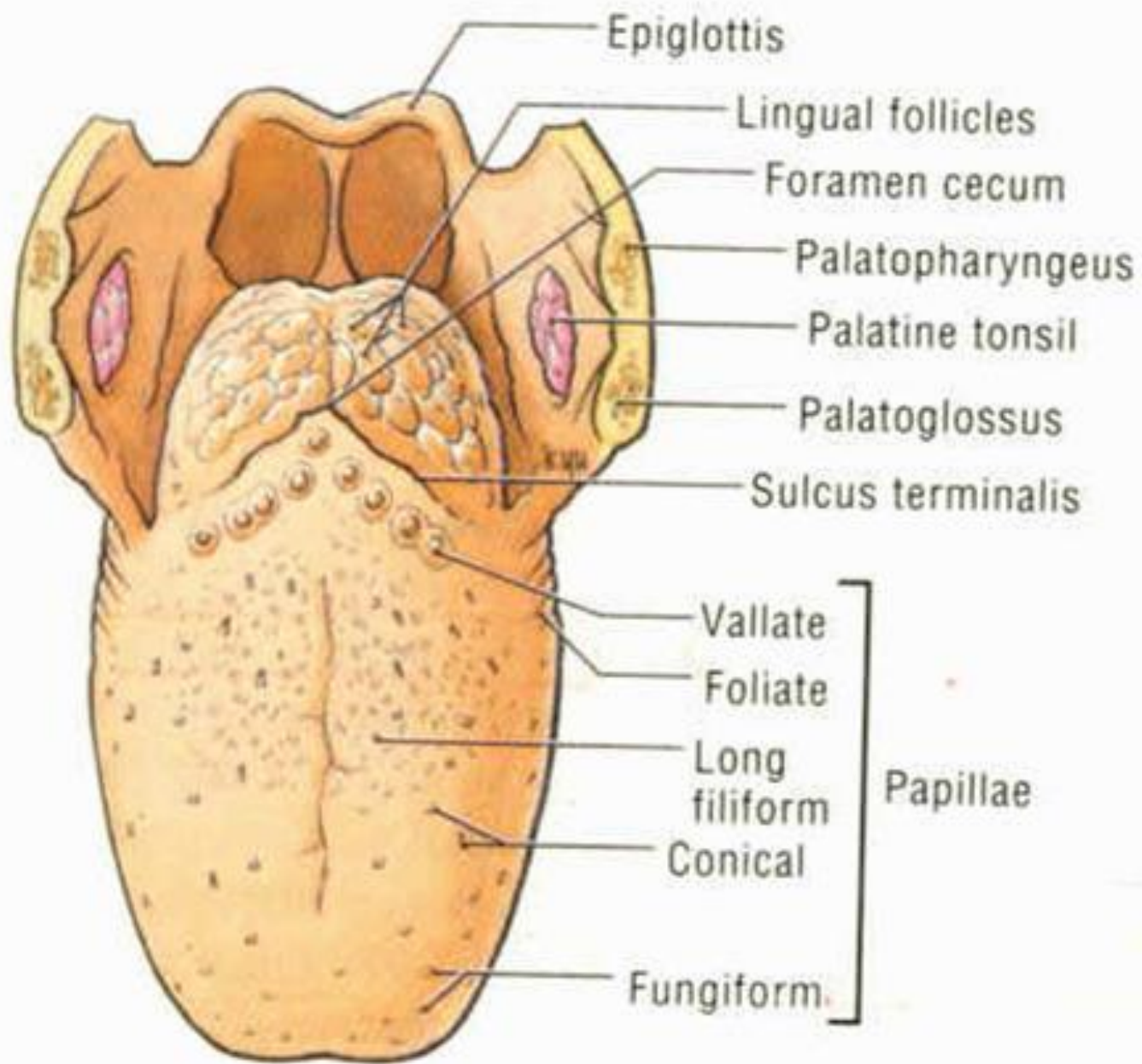


Figure 7-95. Dorsum of the tongue.

Lateral wall of nasal cavity (I)

1. Identify **inferior concha, inferior meatus, auditory tube;**
middle concha, middle meatus;
superior concha, superior meatus;
spheno-ethmoidal recess.
2. Cut away inferior concha, pass a stiff wire through **nasolacrimal duct** to inferior meatus.
3. Cut away middle concha,
identify the **hiatus semilunaris**
and **ethmoid bulla.**
4. Pass a stiff wire from **frontal sinus** through frontonasal duct to **hiatus semilunaris.**

Lateral wall of nasal cavity (I)

5. Observe the **ant., mid. & post. ethmoid cells (sinus)**.
6. Explore **hiatus semilunaris**,
pass a probe into **maxillary sinus**.
7. Open **infraorbital canal**,
identify **infraorbital nerve and vessels**.
8. With the aid of bone forceps, *remove the medial wall of maxillary sinus*, look for roots of teeth.

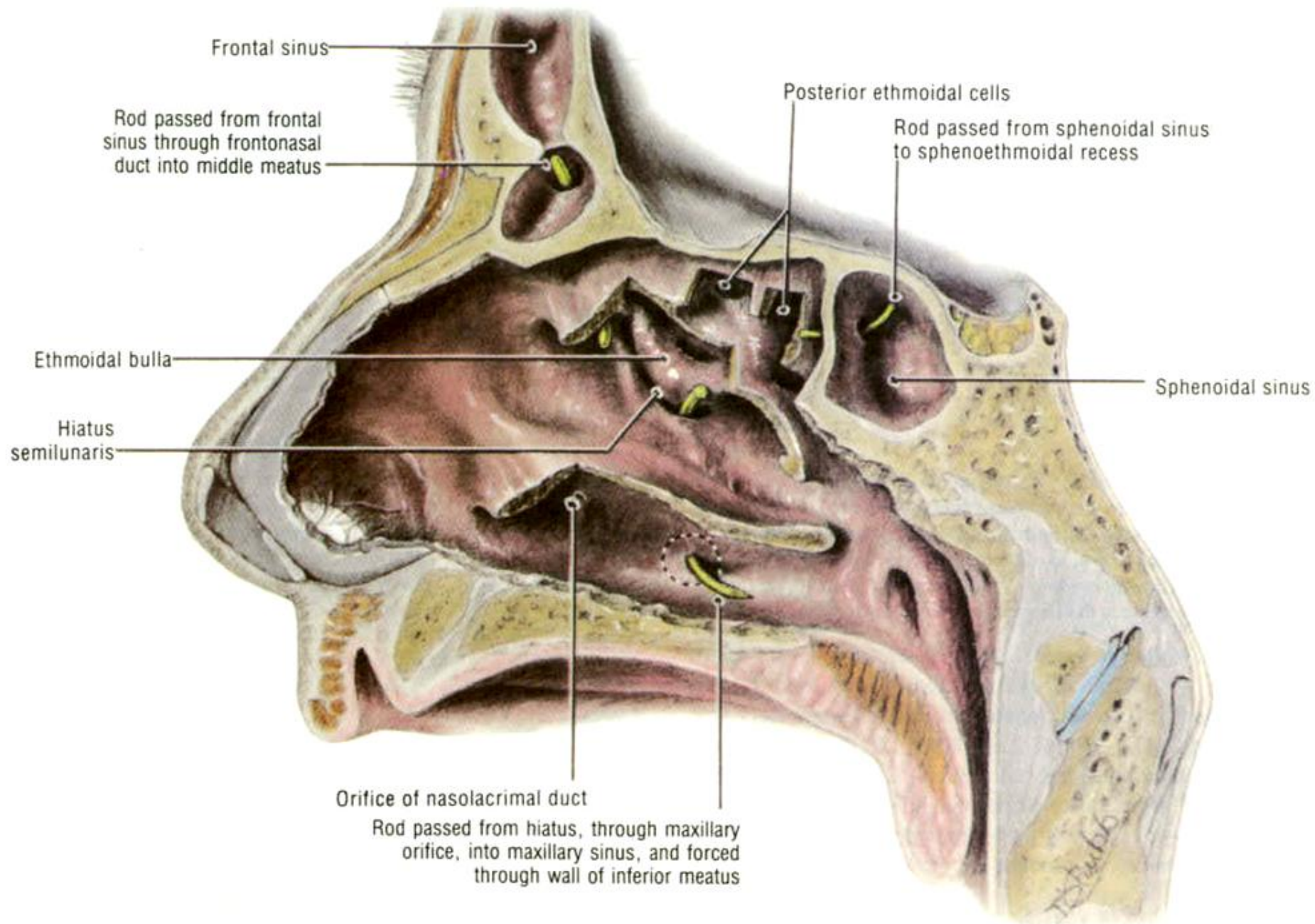


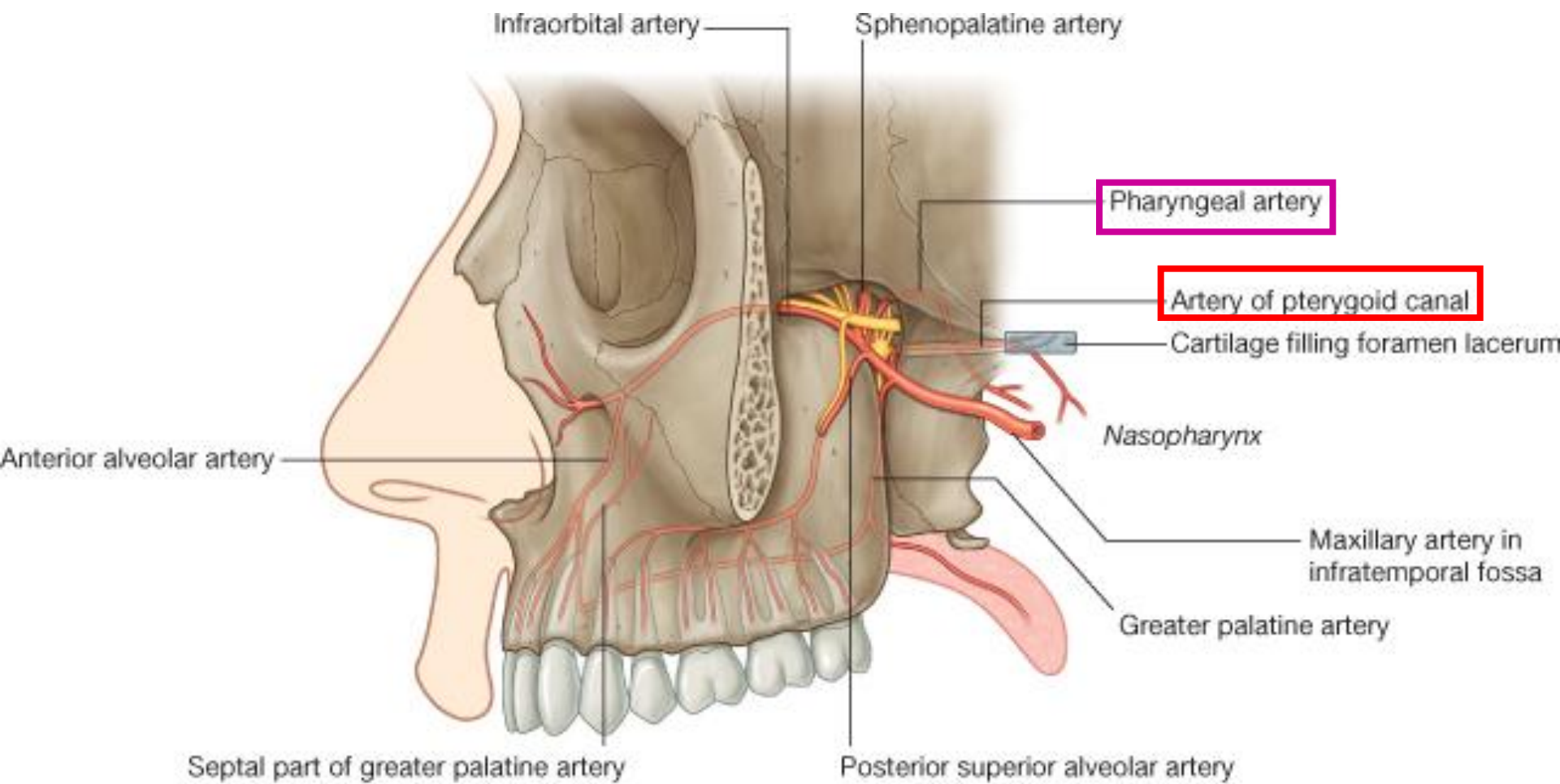
Figure 7-111. Dissection of the lateral wall of the nasal cavity. Parts of the superior, middle, and inferior conchae are cut away.

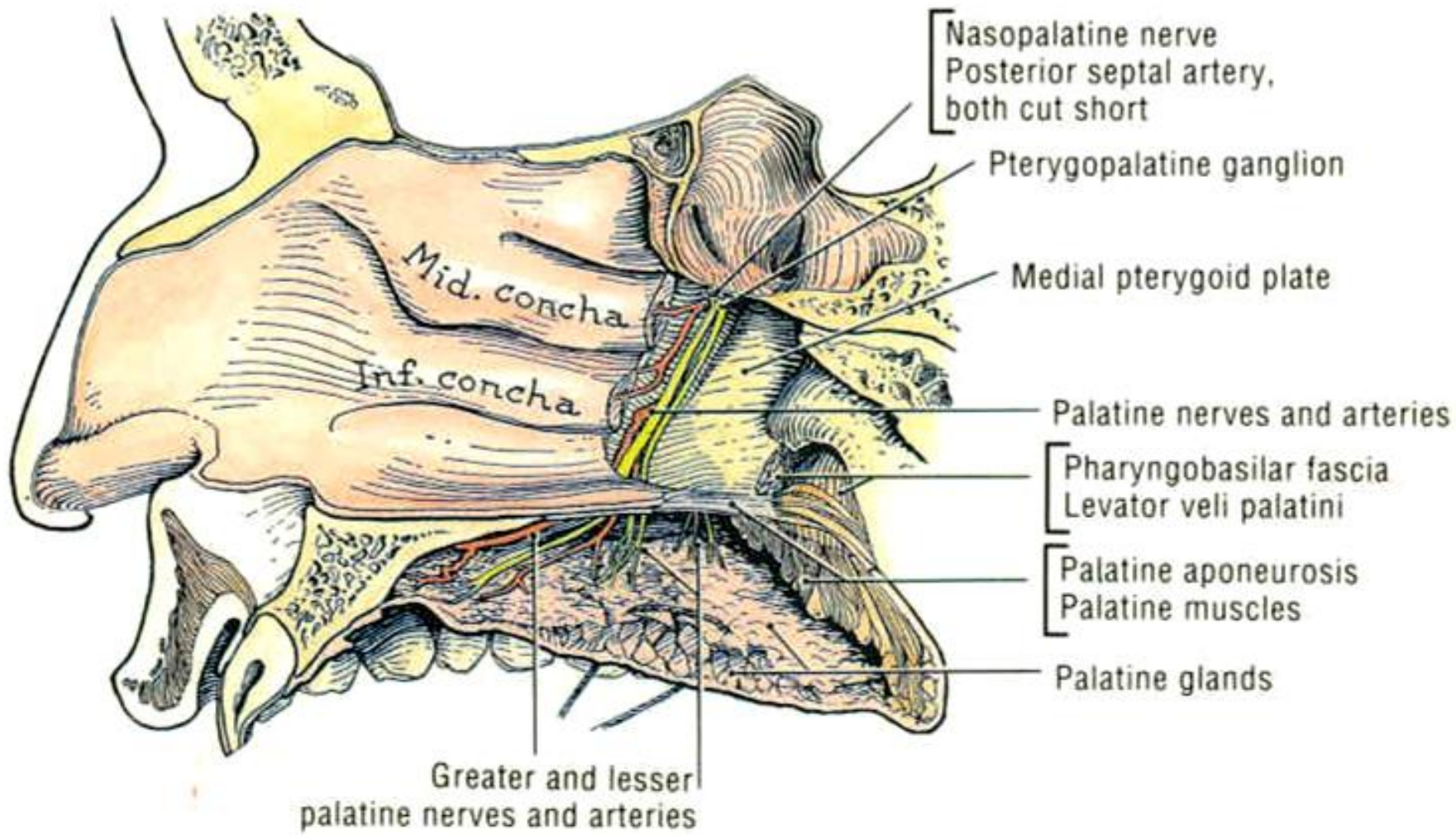
Sphenopalatine foramen & pterygopalatine fossa

1. Identify the **sphenopalatine foramen**,
pterygopalatine fossa,
greater palatine foramen,
greater palatine canal and **pterygoid canal**.
2. Examine **sphenopalatine artery** and branches
(**posterior lateral nasal a.** & **posterior septal a.**)
3. Break down med. wall of **greater palatine canal**
to expose **greater palatine a. & n.**

Sphenopalatine foramen & pterygopalatine fossa

4. Follow greater palatine nerve superiorly to sphenopalatine foramen, find **pterygopalatine gang.**
5. Find the ridge of **pterygoid canal** in **sphenoid sinus**, open the canal & find the nerve of **pterygoid canal.**
6. Identify maxillary artery, greater palatine a. & sphenopalatine a.
7. Maxillary nerve (V2) & pterygopalatine ganglion, infraorbital nerve.





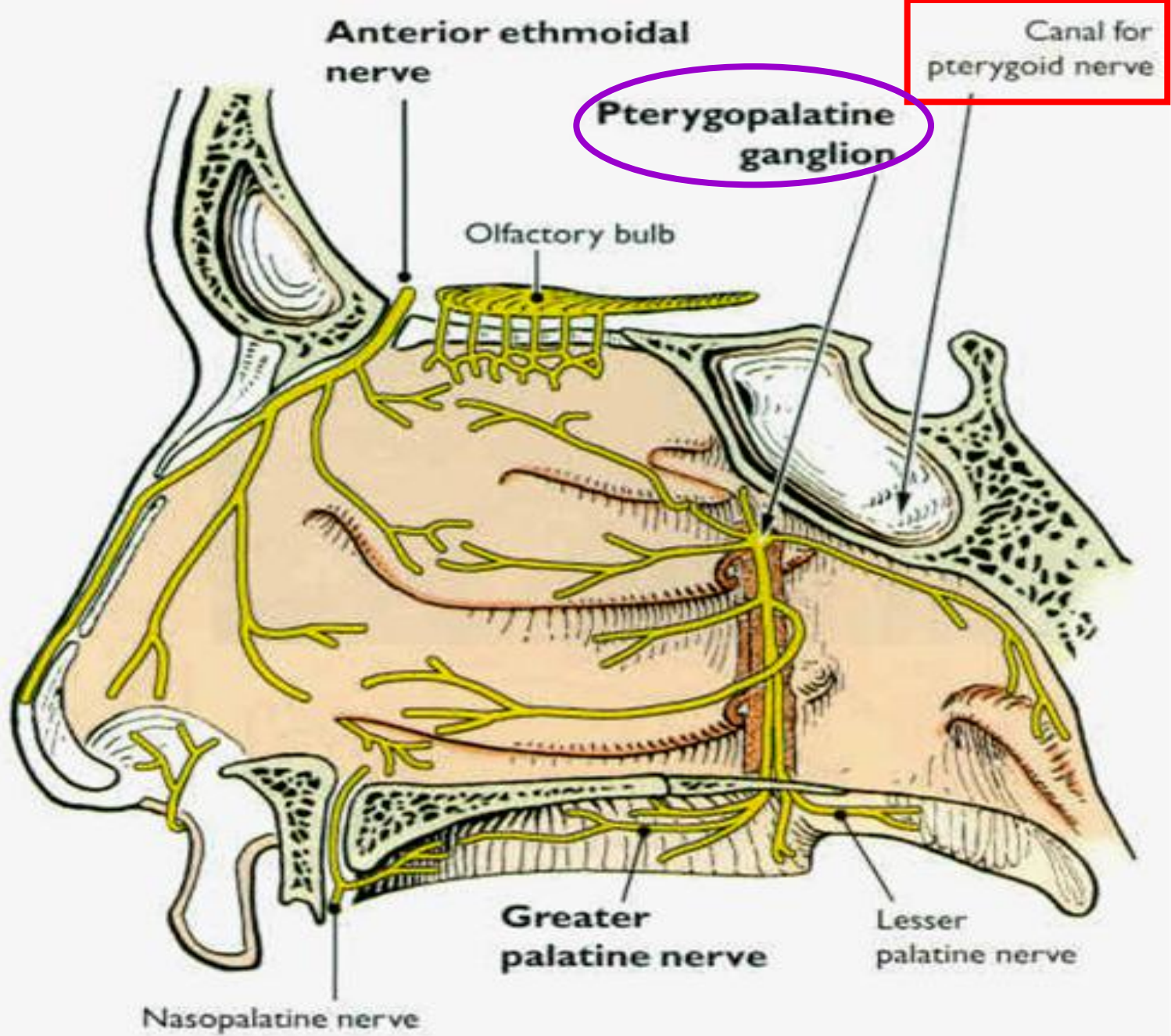


Figure 7.87. Diagram of nerve supply of lateral wall of nose.